

A customized quad helix: an appliance for management of unilateral posterior cross-bite

Sanjanaa Venkata Ramanamurthy Chebolu¹, Uma Maheshwari², Devaki Vijayalakshmi. R^{3*}

¹Private Practice, ²Assistant Professor, ³Professor and HOD, ¹⁻³Dept. of Orthodontics and Dentofacial Orthopedics, ¹⁻³Meenakshi Ammal Dental College and Hospital, Chennai, Tamil Nadu, India

Abstract

Posterior crossbites are most common malocclusion observed in both primary and permanent dentition. Lateral shift of the mandible is one of the effects exhibited in patients with posterior crossbite. The other effects associated are asymmetrical condylar positioning, neuromuscular disturbances with difference in loading patterns and the corresponding asymmetrical maxillo-mandibular dentoskeletal adaptations. The prevention of these effects requires early intervention of orthodontic treatment to achieve a stable occlusion in early stages of development. Achieving a normal closure pattern with elimination of functional shifts through correction of transverse discrepancy harmonizes the detrimental dentofacial esthetics. However, the restoration of harmony should be achieved during periods of dynamic growth. Early permanent dentition correction is less time consuming and more physiologically tolerable treatment options. This case report describes about a customized quad helix for the correction of unilateral posterior crossbite correction in a 13-year-old patient.

Keywords: Appliances, Cross-bites, Orthodontics.

Introduction

Posterior cross-bite is an aberrant transverse malocclusion wherein the maxillary teeth are palatal to the corresponding antagonist teeth. Posterior crossbites can be isolated to a specific tooth or may involve multiple teeth. The literature reports a prevalence between 6% and 23% for posterior crossbite with an increased prevalence for unilateral crossbite approximating 6-7%.^{1,2} There are various etiological factors which contributes to the development of crossbite, the most common being abnormal function like sucking habits, upper airway obstruction and tongue thrust habit. As transverse is the first dimension in which growth ceases,³ posterior crossbite malocclusions is least likely to undergo spontaneous correction without intervention, thus predisposing the malocclusion for earlier intervention with maxillary expansion.

Diagnosis and Etiology

A 13-year old patient presented with a chief complaint of forwardly placed front teeth and a gap between upper and lower teeth with no significant medical history. Extra-oral examination revealed a mesocephalic head type, mesoprosopic facial pattern, convex profile, posterior divergence, acute nasolabial angle with a potentially incompetent lip (Fig. 1. A, B, C, D).

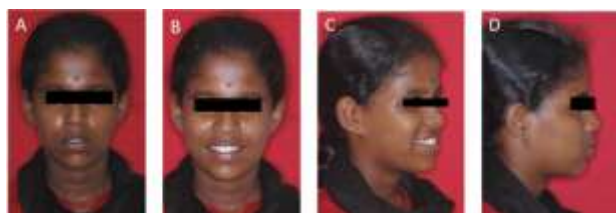

Fig. 1: Pre – treatment extra-oral photographs

The maxillary dental midline was coincident with the facial midline. The lower dental midline was shifted to the left by 2mm with respect to the maxillary dental midline. Intra-oral examination revealed a tapered maxillary arch with unilateral posterior crossbite on left side and ovoid mandibular arch with imbrication in lower anteriors. The canine relationship was end-on relationship on the left side and class I on the right side. Molar relationship on left couldn't be established because of the cross-bite. The patient had an anterior open bite (3 mm) and an overjet of 2mm (Fig. 2. A, B, C, D, E).

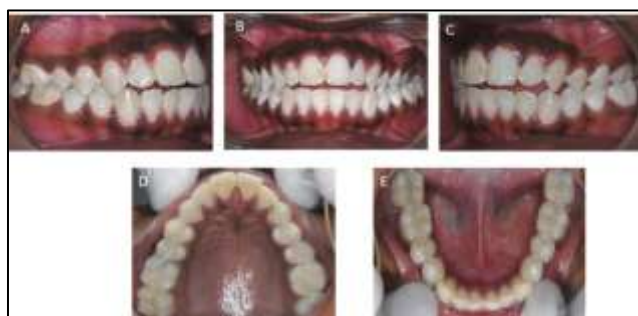

Fig. 2: Pre – treatment intra-oral photographs

Functional examination revealed clinically asymptomatic TMJ with a tongue thrust swallow pattern. The patient had difficulty in production of /s/ sound and also had difficulty in pronouncing consonants like /f/ and /z/.

The model analysis revealed a tooth-size arch-length discrepancy of 9 mm in upper arch and 4 mm in lower arch. The intercanine width was 30mm, inter-premolar width at 1st premolar was 32mm and inter molar width was 40mm

*Corresponding Author: Devaki Vijayalakshmi. R, Dept. of Orthodontics and Dentofacial Orthopedics, Meenakshi Ammal Dental College and Hospital, Chennai, Tamil Nadu, India

Email: devasara17@yahoo.co.in

<http://doi.org/10.18231/ijodr.2019.023>

Table 1: Pre-and Post- inter-canine, inter-premolar and inter-molar widths

Parameters	Normal Values*	Pre-treatment	Post-Treatment
Inter-canine width (mm)	31.3	30	32
Inter-premolar width (mm)	34.9	32	34
Inter-molar width (mm)	44.3	40	44

*Data from Moyers RE, et al: Standards of Human Occlusal development. Monograph 5, Craniofacial Growth Series. Ann Arbor, Mich: University of Michigan, Center for Human Growth and Development: 1976.

Table 2: Pre and Post cephalometric values

Parameters	Normal Values	Pre-Treatment	Post-Treatment
SNA (°)	82	82	82
SNB (°)	80	79	79
Anb (°)	2	3	3
Upper 1 to na (°)	22	31	25
Upper 1 to na (mm)	4	8	4
Lower 1 to nb (°)	25	35	25
Lower 1 to nb (mm)	4	8	4
Impa (°)	90	110	91
Fma (°)	25	28	29
SN-GoGn (°)	32	35	35
Mandibular body length (Co-Gn) (mm)	114.9±7.1	119	121
Maxillary length (Co-point A) (mm)	89.2±5.2	92	92
Lower Facial Height (ANS-Gn) (mm)	68.8±4	74	76
Convexity of point A to N Pog (mm)	2mm±2	5	3
Nasolabial angle (°)	90	85	96
Lower lip to E Plane (mm)	0mm±2	3	0
McNamara upper pharynx measurement (mm)	17.4±3.4	17	17
McNamara lower pharynx measurement (mm)	11.3±3.3	13	14

(Table 1). Ashley-Howe model analysis indicated that expansion was possible in the upper arch. The Boltons analysis revealed relative anterior mandibular tooth material excess by 3.5 mm and relative overall maxillary tooth material excess by 6.2 mm

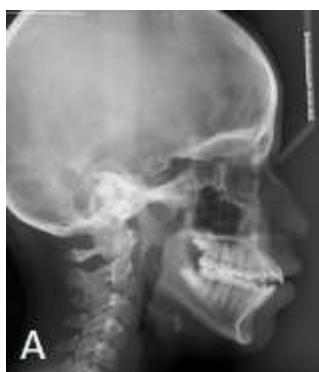

Fig. 3: A: Pre-treatment Orthopantomogram revealed no abnormalities.

On lateral cephalometric evaluation, the patient had orthognathic maxilla and orthognathic mandible on a high mandibular plane angle, increased lower facial height with proclined upper and lower incisors. There were no signs of airway obstruction in the lateral cephalogram and airway

dimensions were within the normative values. (Table 2) (Fig. 3. B).

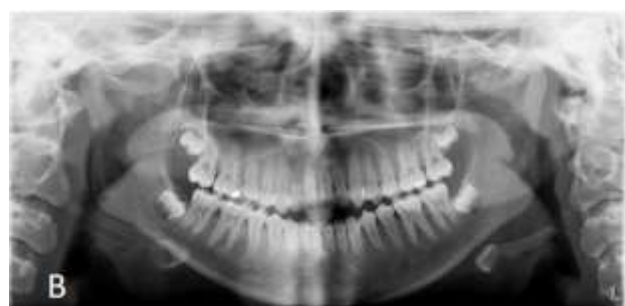

Fig 3 B: Pre – treatment OPG and Lateral Cephalogram

Treatment objectives

The treatment objective was to enhance the soft tissue profile and facial esthetics, to correct the habit using a habit breaking appliance, to correct the unilateral posterior crossbite, to align upper and lower anteriors, to maintain Class I molar relation and Class I canine relationship bilaterally and to achieve ideal overjet and overbite

Treatment plan

Two approaches to treatment were considered:

1. The first approach included expansion of upper arch to correct the posterior crossbite and utilization of space

gained through expansion in upper arch and interproximal reduction in lower arch to address the remainder of the treatment objectives. However, considering the extent of arch-length tooth size discrepancy and dentoalveolar protrusion, which was the patient's foremost esthetic concern, this treatment option would have been insufficient.

- The second approach included expansion of upper arch using customized quad helix to alleviate the unilateral posterior crossbite and extraction of 1st pre-molars in all 4 quadrants to alleviate dentoalveolar protrusion thus improving the facial esthetics. This approach addressed all the treatment objectives.

Upper arch: Extraction of 14,24,

Lower arch: Extraction of 34, 44

Upper anchorage – Group A

Lower anchorage- Group A

Mechanotherapy: 0.022 MBT PEA

Treatment progress

The treatment commenced with banding of upper 1st molars and quad-helix fabricated of 0.036-inch stainless steel wire was soldered to the bands for crossbite correction. The lingual arms were extended bilaterally up to the canines and helices were placed as anteriorly possible. To reinforce anchorage acrylic was added to the quad helix on the non-cross bite to harness the palatal soft and hard structures. Anticipating some amount of palatal tissue irritation, a soft liner was added over the palatal surfaces. Simultaneously, lower posterior bite was inserted to open the bite to facilitate crossbite correction without resistance. The quad helix was preactivated unilaterally, such that the molar bands on the cross-bite side were half-way past the buccal surface of the upper left 1st molar (Fig 4. A, B, C, D, E).

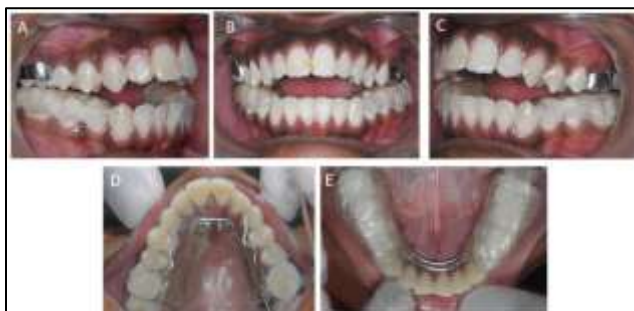

Fig. 4: Customized quad helix with acrylic covering on I quadrant to allow unilateral expansion on the left.

At the end of four months, once the arch was over-expanded such that the palatal cusps of the maxillary 1st molars were in contact with the buccal cusps of the mandibular 1st molars, maxillary expansion along with mandibular bite plane was discontinued, and the appliance was left in place for 1 month as part of the retention protocol and fixed appliance treatment was initiated after extraction of all 1st pre-molars using 0.022 X 0.028-inch MBT prescription (Fig 5. A, B, C, E).

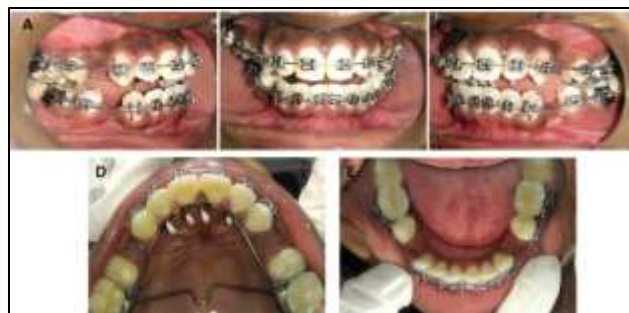

Fig. 5: Post expansion with strap up

Fixed appliance therapy was combined with tongue rakes for breaking the tongue-thrust habit and also trans palatal arch was added to maintain the corrected transverse dimension (Fig 5. D). The sequence of wire used for levelling and aligning were 0.016-in NiTi, 0.017 X 0.025-in NiTi, 0.019 X 0.025-in NiTi which was followed by space closure using frictionless mechanics on a 0.019 X 0.025-in SS wire. The finishing and detailing were carried out by segmental zing the upper arch and using a continuous 0.014-inch SS in the lower arch and settling was carried out.

Treatment Results

Facial appearance improved drastically, straight facial profile was achieved with a consonant smile arc and competent lips. The patient was pleased with the end results and enhanced facial appearance (Fig 6. A, B, C, D).

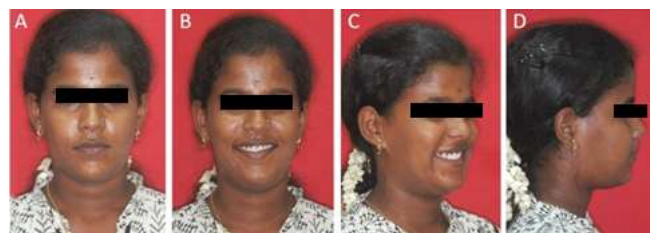

Fig. 6: Post – treatment extra-oral photographs

The treatment outcome at the end of active orthodontic treatment was excellent in terms of intercuspation, arch coordination and midlines. At the end of 18 months of active treatment, the appliance was deboned in a class I canine and class I molar relationship (Fig 7. A, B, C, D, E).

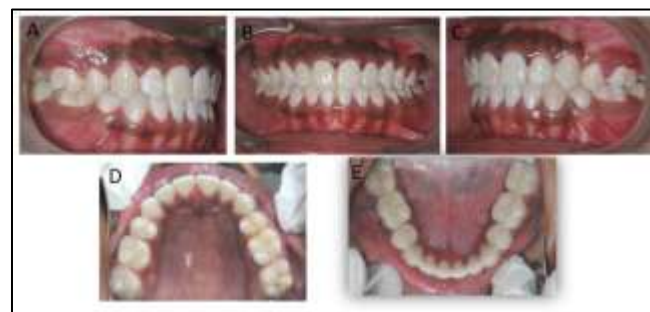

Fig. 7: Post – treatment intra-oral photographs

Following deboning, retention regimen consisted of Bag's wrap around retainer with tongue-crib for the upper and bonded lingual retainer for the lower (Fig 8. A, B, C, D, E).

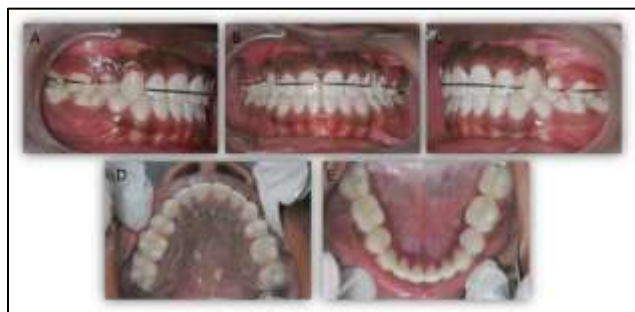

Fig. 8: Post – treatment intra-oral photographs

Post-treatment study models demonstrated an increase in the maxillary inter-canine, inter-premolar and inter-molar width with attainment of ideal overjet and overbite (Table 1). Post-treatment OPG revealed no abnormalities and no signs of root resorption (Fig. 9. A).

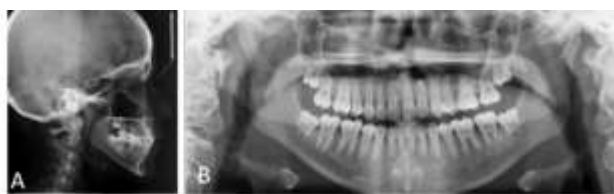

Fig. 9: Post – treatment OPG and Lateral Cephalogram

Cephalometric analysis demonstrated correction of upper and lower anterior proclination (Table 2) (Fig 9. B) (Fig 10).

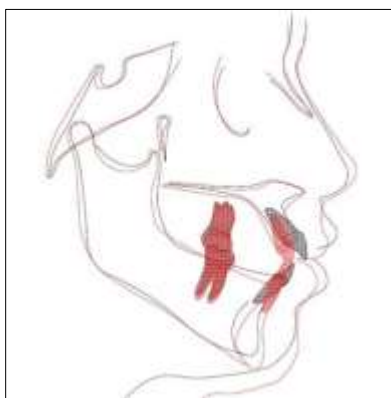


Fig. 10

Discussion

Foremost treatment goal in orthodontics is to achieve results which are stable in the post-retention phase. The key factor which decides the long-term stability is making a change at the right time harnessing growth. As the patient grows, the abnormal function like tongue thrust matures making it difficult to intervene. The therapeutic success in treating a unilateral crossbite cases lies in individualized treatment approaches.⁴ As the patient was in her early teens, it was

decided to intervene and correct the transverse dimension before the growth completes. The foremost concern during expansion is the post-expansion relapse and since the patient had a unilateral crossbite, it was much more practical to opt a technique which had little or no effect on the non-crossbite side. Options contemplated were a removable expansion appliance incorporated with a jackscrew, however this was disregarded because it would require total dependency on the patient, the next option was utilizing asymmetric maxillary expansion appliance (AMEX),⁵ but the design of the appliance is such that it hinders with the mastication and speech ability of the patient and it would reduce the tongue space. Considering the patient already had a tongue thrust habit, the AMEX would further complicate the treatment mechanics and would predispose the patient to a lateral tongue thrust and posterior open bite. So, it was decided to fabricate a Quad helix and to prevent expansion on the unaffected side acrylic was added and support was taken from the palatal vault thus reinforcing anchorage. Post-expansion it was decided to extract 1st premolars in all 4 quadrants to address the proclination which was the patient's chief complaint. Literature suggests that maxillary expansion had significantly lesser relapse in younger patient,⁶ so it was appropriate to utilize the patients age and fabricate a customized appliance which was less technique sensitive and compliant for the patient. However, some amount of post-treatment relapse related to late mandibular growth is anticipated which can be best avoided if the patient is under long-term observation and retention.

The current case report illustrates the use of a customized quad helix for correction of a unilateral crossbite. Contrary to the other rapid and slow expansion appliances like AMEX, Hass expanders, Trans Force expanders etc., the customized quad helix is easier to fabricate, cost effective and more patient compliant.

Conclusion

The customized quad-helix appliance proved to be effective for treating unilateral crossbite in the posterior region. The appliance was well tolerated by the patient Obtaining a, harmonious soft tissue drape and occlusal stability were the objectives at the beginning of the treatment which was achieved through combined customized quad helix and fixed appliance therapy. The patient was pleased with the improvement in the masticatory function and facial esthetics.

Source of Funding

None.

Conflict of Interest

None.

References

1. Melsen B, Steengard K, Pedersen J. Sucking habits and their influence on swallowing pattern and prevalence of malocclusion. *Eur J Orthod* 1979;1:271-80.

2. Thilander B, Wahlund S, Lennartsson B. The effect of early interceptive treatment in children with posterior cross-bite. *Eur J Orthod* 1984;6:25-34.
3. Proffit WR, Fields HW, Sarver DM. Contemporary Orthodontics, 4th ed. St Louis, Mo: Mosby; 2007:619
4. Bartzela T, Jonas I. Long-term stability of unilateral posterior crossbite correction. *Angle Orthod* 2007;77(2):237-43.
5. Toroglu M S, Uzel E, Kayalioglu M, and Uzel I, "Asymmetric maxillary expansion (AMEX) appliance for treatment of true unilateral posterior crossbite," *Am J Orthod and Dent Orthop* 2002;122(2):164-73.
6. Wertz R, Dreskin M. Midpalatal suture opening: a normative study. *Am J Orthod* 1977;71:367-81.

How to cite this article: Chebolu SVR, Maheshwari U, VR Devaki. A customized quad helix: an appliance for management of unilateral posterior cross-bite. *Indian J Orthod Dentofacial Res* 2019;5(3):108-12.