

Maxillary arch expansion along with fixed mechanotherapy using different expansion devices

Medha Lakhanam¹, Tripti Tikku², Rohit Khanna³, Rana Pratap Maurya⁴, Snehlata Verma⁵, Kamna Srivastava^{6,*}

¹Junior Resident, ²Professor and HOD, ³Professor, ⁴⁻⁶Reader, Dept of Orthodontics and Dentofacial Orthopedics, Babu Banarasi Das College of Dental Sciences, Lucknow, Uttar Pradesh, India

***Corresponding Author:**

Email: amitn99@gmail.com

Abstract

Malocclusions can exist in all the three planes of space i.e in antero – posterior, vertical and transverse plane. Transverse discrepancies can manifest as dental, skeletal or functional discrepancies. Maxillary expansion is one of the most common treatment modality for arch length augmentation, posterior crossbite correction and removing cross arch interferences.

Skeletal correction is done by orthopedic expansion or surgical expansion. Rapid Maxillary Expansion and Head Gears, produces orthopedic correction. Severe skeletal discrepancies require surgical correction of underlying skeletal deformity by using SARPE (Surgically Assisted Rapid Palatal Expansion) or surgical expansion of palatal shelves by midline osteotomies.

Dental correction can be done using Rapid expansion in growing children and by slow expansion using Quad Helix, W Arches, Coffin Spring and certain modification of Jack screw appliances in other cases.

In patients treated with fixed mechanotherapy expansions can not only be achieved by Arch wires, auxillary Jockey arches, cross elastics etc. but also by slow or rapid expansion devices that can be amalgamated with fixed orthodontic treatment.

In this article, the use of slow maxillary expansion appliances in treatment of the three patients with transverse maxillary deficiency and undergoing fixed mechanotherapy will be discussed.

Keywords: Expansion.

Introduction

Malocclusions can exist in all the three planes of space i.e in antero-posterior, vertical and transverse plane. Transverse discrepancies can manifest as dental, skeletal or functional discrepancies. Maxillary arch expansion is one of the common non extraction treatment modality for arch length augmentation, posterior crossbite correction and removing cross arch interferences.

Skeletal correction is done by orthopedic expansion or surgical expansion. Rapid Maxillary Expansion and Head Gears, produces orthopedic correction. Severe skeletal discrepancies require surgical correction of underlying skeletal deformity by using SARPE (Surgically Assisted Rapid Palatal Expansion) or surgical expansion of palatal shelves by midline osteotomies.

Dental correction can be done using Rapid expansion in growing children and by slow expansion using Quad Helix, W Arches, Coffin Spring and certain modification of Jack screw appliances in other cases.

Slow expansion devices can be amalgamated with fixed mechanotherapy to achieve dentoalveolar expansion which reduces the total duration of treatment time. Overhanging of palatal cusp of posterior teeth that may occurs due to dentoalveolar expansion with slow expansion devices can be simultaneously corrected by incorporating buccal root torque in the main arch wire.

In this presentation, the use of slow maxillary expansion appliances with fixed mechanotherapy will be shown in two patients having transverse maxillary deficiency.

Case-I

A 27-year-old male patient was referred to department of orthodontics with chief complaint of spacing in maxillary and mandibular anterior region. On examination, the patient had a convex profile, increased interlabial gap, tongue thrust, unilateral posterior crossbite on right side and asymmetric maxillary arch. All the pre treatment records (Lateral cephalogram, O.P.G, study models and extraoral and intraoral photographs) were taken and analysed (Fig. 1A).

Based on the clinical diagnosis non extraction orthodontic treatment was planned aiming to correct posterior crossbite on right side and closure of spaces present in maxillary and mandibular anterior region.

To correct the posterior unilateral crossbite removable appliance with jack screw was designed and closure of spaces was planned. Appliance base plate was cut in the posterior region in such a manner to produce unilateral expansion of posterior segment of right side (Fig. 1B) whereas remaining portion of the base plate served as anchorage unit, from palatal aspect. Buccal root torque was incorporated in main arch wire when reached to 17X25 SS wire after sequential change of alignment wires.

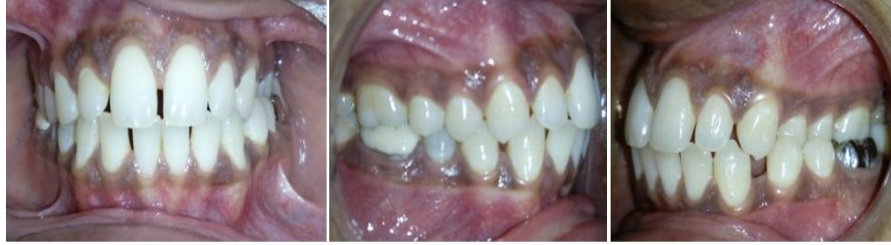

Fig. 1(A): Pretreatment intraoral photographs showing unilateral crossbite on left side.

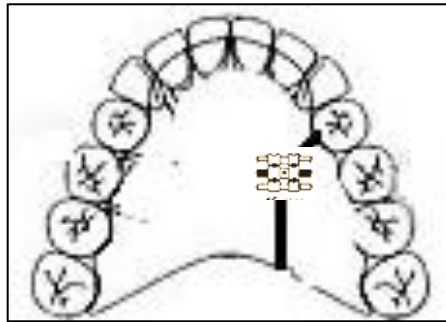


Fig. 1(B): The slow expansion jack screw appliance

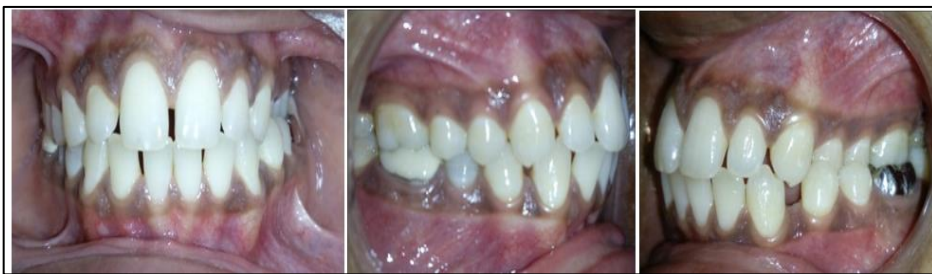

Fig. 1 (B): Pretreatment intraoral photographs showing unilateral crossbite on right side

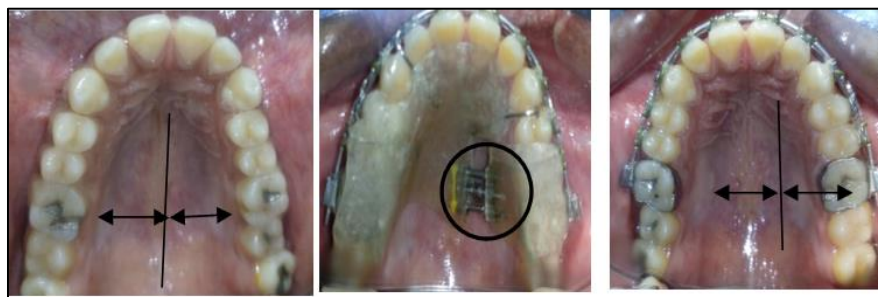

Fig. 1(C): Showing Maxillary arch expansion on right side

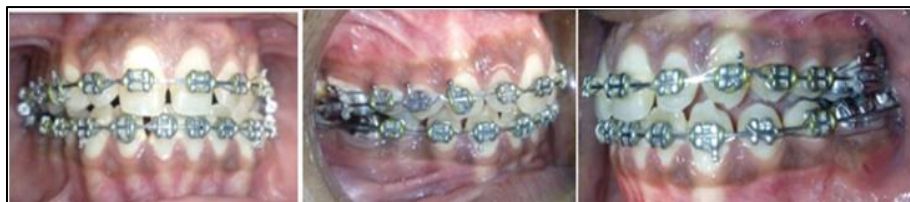

Fig. 1(D): The mid-stage treatment intraoral photographs depicting correction of posterior crossbite on right side

Treatment Progress

Activation of expansion screw was performed 1-quarter turns (0.25 mm) once per week until the desired

overexpansion was achieved, evaluated by the crossbite correction (after 4 months) simultaneously alignment of the arch wire with 0.016,0.018 Ni-Ti wires and the

correction was stabilised by buccal crown torque was incorporated in 17×25 SS wire. Simultaneous alignment and leveling and closure of spaces in maxillary and mandibular arches was done using sequential wire (0.016, 0.018 Ni-Ti and 0.016×0.025 SS wire). 4mm expansion in 4 months along with overcorrection of crossbite for preventing relapse chances.

Case II

A 21-year-old male patient was referred to our department with complaint of irregular teeth in maxillary and mandibular arch. On examination, the patient had a straight profile, competent lips, anterior crossbite irt 12, bilateral posterior crossbite and asymmetric maxillary arch (Fig. 2 A). Maxillary arch expansion was planned with modified coffin spring with overlapping of anterior arms for palatally placed lateral incisor (Fig. 2 B) and was soldered to maxillary first molar bands.

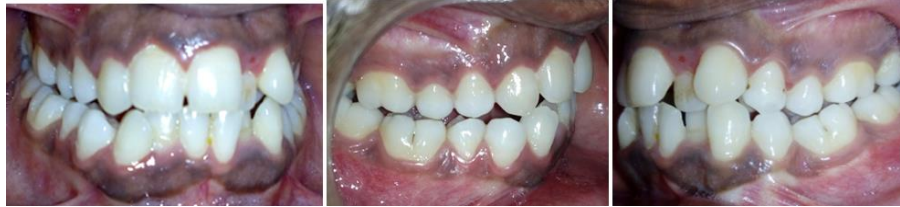

Fig. 2(A): Pretreatment intraoral photographs showing anterior crossbite on left side and bilateral posterior crossbite

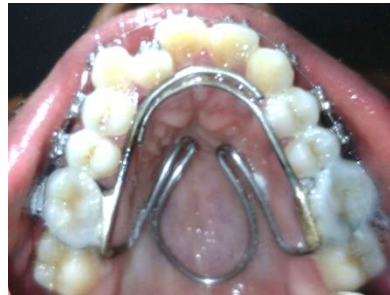

Fig. 2(B): The modified coffin spring appliance for correction of anterior crossbite

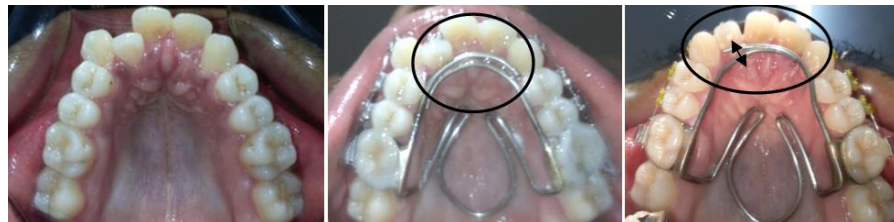

Fig 2(C): Maxillary arch photographs: before, during and after expansion showing maxillary anterior expansion and correction of right lateral incisor

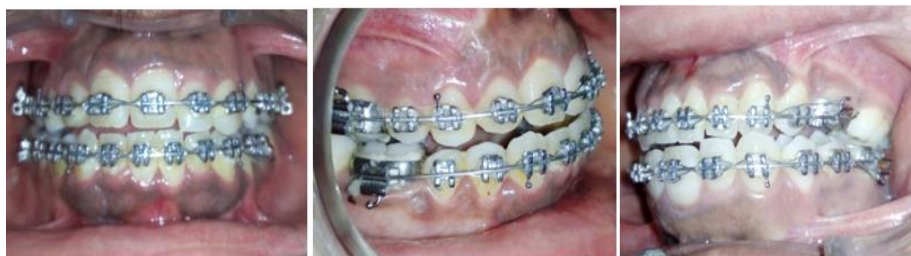

Fig. 2(D): The mid-stage treatment intraoral photographs

Treatment Progress

Alignment and leveling of maxillary arch was started with 0.014 NiTi arch wire. On the palatal aspect modified coffin spring was soldered on maxillary first molar bands and cemented. Activation of coffin

spring was performed on scheduled monthly appointment and the desired expansion was achieved, evaluated by the crossbite correction of posterior segment and adequate space achieved for lateral incisor along with fixed mechanotherapy.

Conclusion

Expansion in maxilla and maxillary dentition may be accomplished in numerous ways. The type of skeletal and dental problem greatly influences the type of expansion chosen and the type of expansion selected can greatly facilitate the overall treatment objectives.

In both these cases slow expansion appliances were employed alongwith fixed mechanotherapy. The treatment goal was achieved by the activated appliance in coordination with alignment and leveling stages of fixed mechanotherapy. These slow expansion appliances help in expansion of the arches, while fixed mechanotherapy facilitates the bodily movement of tooth by incorporating buccal root torques in the ss arch wire. This combination reduces the duration of treatment.

References

1. Agrwal A, Mathur R. Maxillary Expansion. *Int J Clin Pediatr Dent.* 2010;3(3):139–46.
2. Handelman C.S. Adult Nonsurgical Maxillary and Concurrent Mandibular Expansion; Treatment of Maxillary Transverse Deficiency and Bidental Arch Constriction. *Semin Orthod.* 2012;18:134-51.
3. Mutinelli S, Cozzani M. Rapid maxillary expansion in contemporary orthodontic literature. *APOS Trends Orthod.* 2016;6:129-36.
4. Koudstaal, M. J., Poort, L. J., van der Wal, K. G. H., Wolvius, E. B., Prahl-Andersen, B., & Schulten, A. J. M. Surgically assisted rapid maxillary expansion (SARME): a review of the literature. *Int J Oral and Maxillofacial Surg.* 34(7), 709-14.
5. Pereira JS, Jacob HB, Locks A, Brunetto M, Ribeiro GLU. Evaluation of the rapid and slow maxillary expansion using cone-beam computed tomography: a randomized clinical trial. *Dent Press J Orthod.* 2017;22(2):61-68.
6. Hicks, E. P. Slow maxillary expansion. *Am. J Orthodontics.* 73(2):121–41.
7. Marzban R, Nanda R. Slow Maxillary Expansion with Nickel Titanium, *J Clin Orthod.* 37(8):431-41.
8. Wonga C.A, Sinclair P.M, Keimc R.G, Kennedy D.B. Arch dimension changes from successful slow maxillary expansion of unilateral posterior crossbite. *Angle Orthod.* 2011;81:616–23.