

Molar distalization – A review

Vinay Umale^{1,*}, Neha Jalgaonkar², Chetan Patil³, M. Bala Gangadhar⁴, Sayali Sheth⁵

^{1,4}Senior Lecturer, ^{2,5}PG Student, ³Associate Professor, Dept. of Orthodontics & Dentofacial Orthopedics, Yogita Dental College and Hospital, Khed, Maharashtra, India

***Corresponding Author: Vinay Umale**

Email: vinayumale15@gmail.com

Abstract

Esthetics plays a major role from orthodontic treatment to results. Gaining space in dental arch is the most important step in the treatment planning which can be achieved by different methods one of which is molar distalisation. To distalise molars in upper arch using non-extraction treatment, various appliances have been invented. The first attempt for this technique was the use of headgear appliance, but this needed patient compliance and was esthetically displeasing. Thus, various intra-oral devices were introduced for molar distalisation.

Keywords: Disitilisation, Pendulum appliance, Anchorage.

Introduction

Modern orthodontic viewpoint have been directed towards conservative regimen approach i.e., to avoid the need for extraction. Class II malocclusion treatment plans avoiding extraction demands upper molar distalisation method to achieve class I relationship. This method requires patient compliance when treated with headgear or elastics. However, thoroughly outlined intraoral appliance exclude the requirement for patient consent.

Indications

1. Minimal arch length discrepancy cases and mild class II molar relationship associated with normal mandible.
2. Borderline cases can be effectively managed without extracting teeth, thereby gaining space required for the needful corrections.
3. Class II div I with low mandibular plane angle.
4. Blocked out or impacted canines due to mesial drift of molars but having good aesthetic profile can be treated.

Contraindications

1. Patients with severe arch length tooth size discrepancy.
2. Patients having high mandibular angle are contraindicated for distalization of molars.
3. Treatment by distalisation is also difficult in fully grown patients. Anterior anchorage loss can occur due to the forces required for distalisation of third molar.
4. According to William Wilson in 1978, molar distalisation should not be done before 11 years of age as the maxillary tuberosity enters its rapid growth phase which may lead to second and third molar impaction.¹

Various molar distalisation appliances can be classified as (a) Extra-oral appliances; (b) Intra-oral appliances.

Extra-oral Appliances

Headgears: In 1822, Gunnel first described Extra-oral anchorage. In 1866, Guilford used the headgear for correcting protruding maxillary teeth. Further, in 1892 Norman William Kingsley reported remodeling of class II molar relationship to class I using headgear. Later, Klein Phillip in 1957 assessed the outcome of cervical traction for correcting class II malocclusion.²

Intra-oral Appliances

Atkinson Buccal Bar: In 1959, Guerrero James illustrated a method using this device for moving posterior teeth distally. This appliance produces minimum strain on mandibular anchorage unit. When it is used with minimum amount of elastic force, i.e., 2 ounces measured with a Richmond or a postal scale, this appliance will move the buccal segments posteriorly, whether second molars are present or not. Cervical anchorage was used to position the anterior teeth.³

Acrylic Cervical Occipital Appliance (ACCO): Dr. Herbert I. Margolis first devised this appliance to be used to "harness growth". He added various finger spring auxiliaries for distal tooth movements by realizing the stability and favourable force application of this device.

It is composed of acrylic plate covering the palatal area with an anterior bite plate disoccluding posterior teeth along with modified Adams clasps on the first premolars, a labial bow over the incisors for retention purpose and for moving molars distally there are finger springs facing the mesial aspects of first molars in alliance with an extraoral traction.⁴

Tandem Yoke: Hogs in 1970 introduced this appliance which consist of biometric arch module design for ease of insertion and removal. It comprises of 0.045" round tube that slides on the 0.040" end section of biometric round arch and a retractor of 0.018" along with 0.045" coil spring for the distal movement of the molar with intermaxillary traction.⁵

Herbst Appliance: This device (Fig. 1) was originally designed by Emil Herbst in 1909 and it was popularized by Pancharz in 1979. It has the ability to inhibit maxillary anteroposterior growth and to produce an increase in mandibular length and lower facial height. The intrusive and distal movements of maxillary molars including tipping of crowns distally and mesial drift of the mandibular anterior and posterior teeth is observed. Treatment in mixed dentition is not recommended using this appliance.⁶

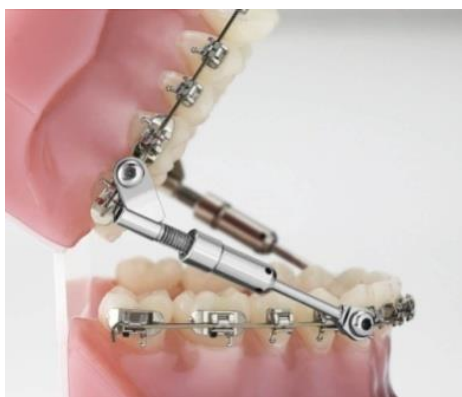

Fig. 1

Saif Spring: In the late 1960 or early 1970s, Armstrong introduced the pace spring which was later called as Multicoil spring, and finally called as Saif spring (Fig. 2). It is nickel-titanium closed spring that applies intermaxillary traction. It contains two springs within each other and loops fused to springs in both sides. It is attainable in 7mm and 10mm diameter.⁷



Fig. 2

Jasper Jumper: James J. Jasper made an appliance (Fig. 3) for correcting class II malocclusion in 1987 which was identical to the Herbst device in terms of design and force vectors. It consists of two vinyl coated auxiliary springs attached to fully banded upper and lower fixed appliances. Posteriorly, the springs were adhered to maxillary first molars whereas anteriorly to mandibular arch wire, and retain the mandible in a protruded position. In both the dental arches, rectangular shaped stainless steel arch wires are used. In anterior region of mandibular arch to strengthen lower anchorage, labial root torque is combined. Transpalatal bar and lower lingual arch are used for anchorage.

This device is indicated in class II growing patients, with deep bite and retroclined mandibular incisors. On the other hand, contraindicated in dental and skeletal open bites with high mandibular plane

angle and increased lower facial height, as the Jasper Jumper creates symbolic tipping of molars distally correlates with clockwise rotation of the mandible.⁸

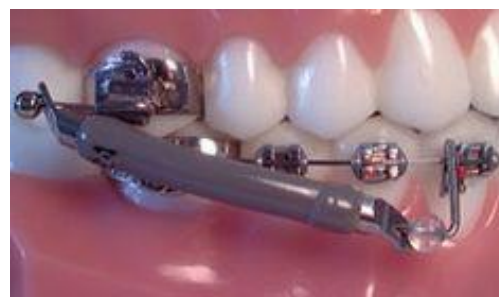

Fig. 3

Jones Jig (Compressed coil device): It was pioneered by Jones and White in 1992, consisting of a modified Nance device fixed to first premolar or deciduous second molar with a heavy round wire and a light wire extending through molar tube, both the wires are joined to a fixed attachment sheath and hook (fig. 4). An activated open coil spring conveys 70-75gms of force which brings about 1mm of anterior movement and nearly 2.5-2.8mm mobilization of molars distally. Patients are usually seen at 4-5 weeks interval and requires 120-180 days for the correction. The main hardship of this appliance is it easily breaks.⁹

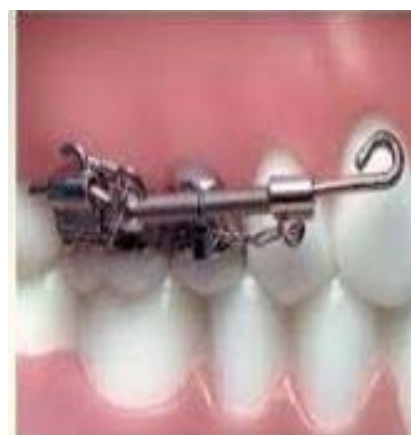


Fig. 4

Pendulum Appliance: This appliance was designed by Higlars in 1992. It is a composite device consisting Nance acrylic button in palate for anchorage and with 0.032" TMA springs which transfers light continuous broad swinging arc or pendulum of force to upper first molars. The lingual sheath is made up of 0.036" for easy fit of 0.032" TMA spring (Fig. 5).

Activation of this device is done before placing it in oral cavity where the spring is parallel to mid saggital plane which generates 60% activation after placement of the appliance. The force applied on each side is nearly 200-250gms which creates a movement of 5mm within 3-4 months of period. In case of maxillary

arch expansion a midline screw is included into the device and is known as Pend X-appliance. It is activated by turning the screw one quarter in every 3 days. This device is not advised in patients having dolico-facial types with tongue thrust habit.¹⁰

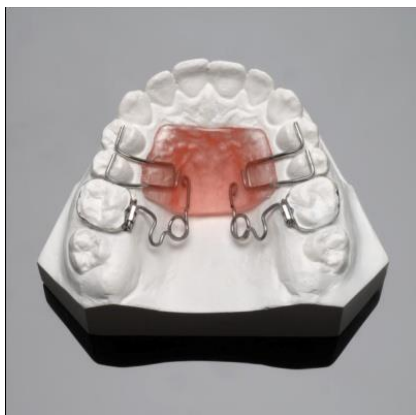

Fig. 5

K-loop Molar Distalizer: This appliance was introduced by Varun Karla in 1995. 0.017"x0.025" TMA wire is used to fabricate this appliance where loop of the K is 8mm in length and 1.5mm in width. Legs of K are inserted into premolar bracket and molar tube having a bent of 20°. The wire is marked mesially to the premolar bracket and the molar tube in which 1mm mesial to the mesial mark as well as 1mm distal to the distal mark stops are bent (Fig. 6). The 20° bends in appliance legs is reinforced by the activation movements as the loop is squeezed into place and this counteracts the force produced by the tipping movements of the appliance. Thus the distal movement of the molar occurs bodily rather than tipping.

Reactivation of the appliance by 2mm should be done after every 6-8 weeks. In majority of the cases 4mm of distal movement of molar is sufficient which can be achieved by one reactivation.¹¹

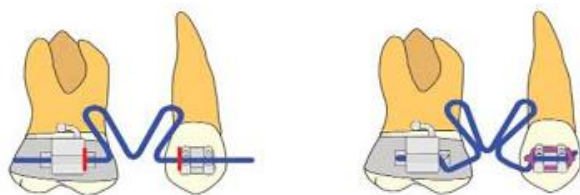


Fig. 6

Fixed Piston Appliance: This appliance was given by Raphael Greenfield in 1995.

The appliance consist of:

1. Maxillary first molar and first bicuspid bands
2. 0.036" stainless steel tubing (soldered to bicuspids)
3. 0.030" stainless steel wire (soldered to first molars)
4. Enlarged Nance button, reinforced with an 0.040" stainless steel wire (for control of anterior anchorage)

5. 0.055"(internal diameter) super elastic nickel titanium open-coil springs (to provide light continuous force) (Fig. 7)

This appliance produces translator movement of maxillary first molar without loss of posterior anchorage. In non-extraction cases the treatment time is decreased as the distal movement of the molars takes place by 1mm/month. A light and controlled force nearly 1½-2 oz per tooth is used. Anterior anchorage loss along with inflammation of the palatal mucosa surrounding the modified nance button will result if the force magnitude is increased.¹²

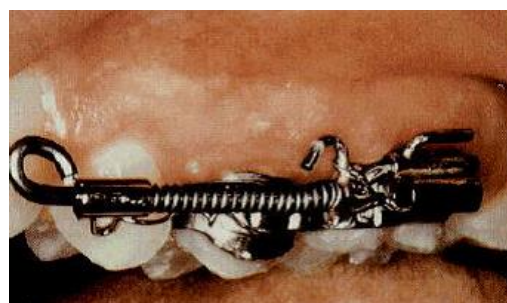


Fig. 7

Distal Jet Appliance: Carano and Testa developed this appliance in 1996. It is made up of acrylic Nance button which is attached with bilateral tubes in 0.036" internal diameter. Bayonet bend is given at the end of the wire which comes out of acrylic and is inserted into palatal sheath on molar band (Fig. 8). Wire is attached to NiTi coil spring with the help of screw clamp. To provide anchorage wire is soldered on the bands of first and second premolars from Nance palatal button. Reactivation is done once a month by moving the clamp closer to first molar.¹³

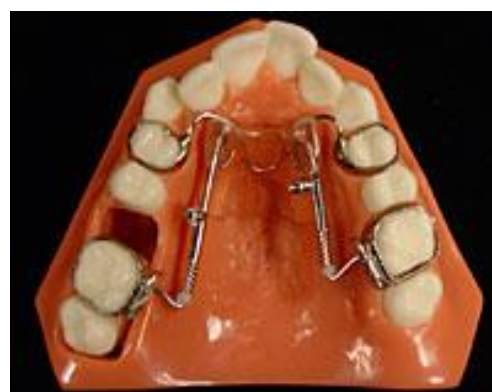

Fig. 9

First Class Appliance: It was introduced by Fortini A, Lupoli M and Parri M in 1999. The components of the appliance (fig. 9) includes bands for first molars and second premolars, vestibular screws soldered to single tubes and butterfly shaped Nance button. Between soldered joint premolar and molar NiTi coil spring is fully compressed. 4mm of molar distalisation can be

achieved within 2-4 months. The disadvantage of the appliance is it produces more of a tipping movement than bodily movement.¹⁴

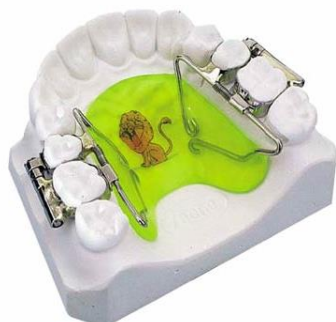

Fig. 10

Modified Pendulum Appliance: It was modified as Pendulum M by Scuzzo et al in 1999 and he claimed that this appliance ensures bodily movement of molars. To achieve bodily movement of maxillary molar he invented the horizontal pendulum loop. Activation of the appliance is done by opening the loop because of buccal and/or distal movement of roots of molar.¹⁵

Franzulum Appliance: It was developed by Buyoff and colleagues in 2000. Lingually and inferiorly to mandibular incisors an acrylic button is placed approaching mandibular canines of each side, is used for anchorage anteriorly. Occlusal rests are placed on canines and first premolars. Active component is placed on a tube between second premolar and first molar. Nickel titanium coil spring of about 18mm length is used for distalisation. It applies 100-120gms of force per side. Molar tubes are inserted with J-shaped wire which passes through the coil and end is inserted into the lingual sheath. Occlusal rests on canine and premolar are bonded with composite. NiTi coil spring gets compressed when J-shaped distalising unit is ligated to lingual sheath. 4-5 mm of distalisation can be achieved with this appliance.¹⁶

C-space Regainer: C-space regainer has labial framework of 0.036" stainless steel wire along with acrylic splint. Distally the labial framework extends close to molar tubes which has to be inserted into headgear tube. It is made up of a closed helix bend into the wire in canine premolar region. Open coil spring of 0.010"x0.040" is soldered distal to helix. For retention purpose ball end clasp is used. Advantage of C- space regainer is that it causes molar distalisation without significant incisor flaring. This appliance was developed in 2000 by Chung KR and colleagues.¹⁷

Intra-oral Bodily Molar Distalizer: Intra-oral bodily molar distalizer was developed to achieve bodily distal movement of molars by Ahmet Keles and Korkmaz Sayinsu in 2000. For the fabrication of this appliance we need to band maxillary first molars and premolars. Palatal attachment with 0.032"x0.032" slot size hinge

cap are welded on palatal aspect of first molar. For anchorage purpose nance palatal button is used which also acts as anterior bite plane to disocclude posterior teeth. Springs are fabricated from 0.032"x0.032" TMA wire and oriented from the acrylic to distalise the molar. Crown tipping force is applied by distalizer part of spring and root uprighting force is applied by uprighting section of spring. Molar correction is achieved by approximately 7.5 months.¹⁸

The Mini-distalising Appliance (MDA): MDA was given in 2003 by Hilgers and Traceyin. Using MDA distalisation of maxillary molars, expansion of upper arch, space regaining for eruption of canines can be achieved as it has the features of both compact rapid palatal expander and Pendulum appliance.

Advantages of MDA

1. It has three dimensional working range.
2. It is small and rigid.
3. It is comfortable to the patient.
4. It does not cause tissue impingement.¹⁹

Pendulum-K: Pendulum-K is developed in 2003 by Kinzinger G. distal screw is incorporated in the nance button along with uprighting force and toe-in bend is also given. It prevents side effect like palatal rolling of molar and tipping of the crown.²⁰

Bone Anchored Pendulum Appliance: Absolute molar distalisation can be achieved with BAPA. It was developed in 2006 by Kirecelli C, Pekpas ZO, Kircelli BH. Palatal titanium implants are placed for anchorage purpose. Implants are placed 7-8mm distal to incisive foramen and 3-4 mm lateral to midline. Space can be regained in both posterior and anterior segment with minimum anchor loss.²¹

X-bow Appliance: This appliance was fabricated using class II springs by D.W.H as phase I appliance. Anteroposterior and transverse correction can be achieved with phase I appliance. Most important part of X-bow is hyrax RME. X-bow also consists of triple L-arch, Gurin locks and Forsus Fatigue Resistant Device.^{22,23}

Skeletalized Distal Jet Appliance: This appliance is fabricated using distal jet appliance along with two palatal implants for anchorage purpose. This appliance caused bodily distal movement of the molar. As the force applied is from the palatal side of the molar it causes mesio-palatal /disto-buccal rotation of molar.²²

Conclusion

Various intraoral noncompliance appliances for maxillary molar distalization have been introduced since the 1980s and evaluated. But with those appliances two negative effects have been reported. Anchorage loss can occur with almost all currently used intraoral appliances. Because the distalized molars must be used as part of anchorage during retraction of the premolars and the anterior teeth, a considerable amount of relapse can occur. To solve these problems of

noncompliance appliances, intraoral distalizing mechanics combined with palatal implants have attracted attention.

References

1. Ucem T, Yuksel S, Okay C, Gulsen A. effects of three dimensional biometric maxillary distalising arch. *Eu J Orthod.* 2000;22:293-98.
2. Klein P. An evaluation of cervical traction on the maxilla and the upper first permanent molar. *Angle Orthod.* 1957;27:61-8.
3. Guerrero James J. Posterior movement of the buccal segments. *Am J Orthod.* 1959;45:125-30.
4. Leonard B. The ACCO Appliance. *J Clin Orthod.* 1969;3:461-8.
5. Hogs D. Tandem yoke. Mechanics of tandem yoke. *Angle Orthod.* 1970;40:234-48.
6. Pancherz H. Treatment of Class II malocclusion by jumping the bite with the Herbst appliance. A cephalometric investigation. *Am J Orthod.* 1979;76:423-42.
7. Mcsgerry PF, Bradley H. Class II correction- Reducing patient compliance: A review of available techniques. *J Orthod.* 2000;27:219-25.
8. Jasper JJ, McNamara JA. The correction of interarch malocclusions using a fixed force module. *Am J Orthod.* 1995;108:641-50.
9. Jones RD, Whilt MJ. Rapid class II molar correction with open-coil jig. *J Clin Orthod.* 1992;26:661-4.
10. Hilgers JJ. The Pendulum appliance for class II non-compliance therapy. *J Clin Orthod.* 1992;26:706-14.
11. Locatelli R, Bednar J, Dietz VS, Gianelly AA. Molar distalization with superelastic Ni-Ti wire. *J Clin Orthod.* 1992;26:277-9.
12. Graber RL. Fixed piston appliance for rapid class II correction. *J Clin Orthod.* 1965;29:174-83.
13. Carano A, Testa M. The distal jet for upper molar distalization. *J Clin Orthod.* 1996;30:374-80.
14. Fortini A, Lupoli M, Parri N. The first class appliance for rapid molar distalization. *J Clin Orthod.* 1999;33:322-28.
15. Scuzzo G. et al. The Modified pendulum appliance with removable arms. *J Clin Orthod.* 2000;34:244-6.
16. Bvloff F, Darendeliler MA, Stoff F. Mandibular molar distalization with the Franzulum appliance. *J Clin Orthod.* 2000;34:518-32.
17. Chung KR, Park YG, Ko SJ. C space regainer for molar distalization. *J Clin Orthod.* 2000;34:32-9.
18. Keles A, Sayinsu K. A new approach in maxillary molar distalization: Intraoral bodily molar distalizer. *Am J Orthod Dentofac Orthop.* 2000;117:39-48.
19. Hilgers JJ, Tracey SG. The Mini-Distalizing Appliance: The Third Dimension in Maxillary Expansion. *J Clin Orthod.* 2003;37:467-75.
20. Kinzinger G, Fritz U, Stenmans A, Diedrich P. Pendulum-K appliance for non-compliance molar distalization in children and adolescents. *Kieferorthop.* 2003;17:11-24.
21. Kircelli BH, Pektas ZO, Kircelli C. Maxillary molar Distalization with a Bone-anchored Pendulum Appliance. *Angle Orthod.* 2006;76(4):650-9.
22. Flores-Mir C, Barnett G, Higgins DW, Heo G, Major PW. Short-term skeletal and dental effects of the Xbow appliance as measured on lateral cephalograms. *Am J Orthod Dentofac Orthop.* 2009;136:822-32.
23. Flores-Mir C, McGrath LM, Heo G, Major PW. Efficiency of molar distalization with the Xbow appliance related to second molar eruption stage. *Eur J Orthod.* 2013;35(6):745-51.