

## Ethnic soft tissue profile differences: A relevant clinical issue in daily orthodontic practice

BEUGRE Jean-Bertin<sup>1,\*</sup>, BEUGRE-KOUASSI Ahia Monique<sup>2</sup>, GNADOH N'Cho Jean Jacques<sup>3</sup>

<sup>1,2</sup>Associate Professor <sup>3</sup>Phd Student, <sup>1,2</sup>Dept. of Orthodontics, <sup>3</sup>Dept. of Paleoanthropology, University Felix Houphouet-Boigny, Abidjan (Côte d'Ivoire)

**\*Corresponding Author:**

Email: jbbeugre@yahoo.fr

### Abstract

**Objective:** The objective of this study was to determine the cephalometric variations in the soft tissue profile between Ivorian and Lebanese girls.

**Material and Methods:** We conducted a cross-sectional comparative study in young girls from two countries (Côte d'Ivoire and Lebanon), aged 11-16 years, taken in initial consultation in a private orthodontic practice in Abidjan. For each subject selected, lateral cephalometric radiographs were taken under standardized conditions and traced to determine soft tissue patterns. The cephalometric analysis was performed with the conventional marks taken from the soft tissues. Classic and specific planes and lines were used. Data obtained were analyzed with SPSS 20.0 statistics software. The quantitative variables were described by their average and difference. A *t* test for independent samples was performed to compare the variables according to ethnicity (nationality). Statistical significance was set at  $p < 0.05$ .

**Results:** The results showed many significant statistical differences between the Ivorian and the Lebanese girls, except for the upper part of the facial profile. Almost all the variables concerning the convexity of the soft tissue profile, and the nose profile, showed differences between the two groups. The Lebanese girls had a larger total facial convexity than the Ivorian girls. Whose nose' depth angle was smaller, and whose nose' back angle was larger. The nasal bridge was thus more pronounced. The labio-mental angle and the Z angle also smaller. However, the nasal tip angle did not present any difference between the two groups. The lips were more protrusive in the Ivorian girls.

**Conclusion:** These results reveal significant differences in most of the facial soft tissue profile variables comparing Ivorian with Lebanese girls. Most of these variables are essential for the diagnosis and treatment plan of cases that need orthodontic and/or orthognathic surgery.

**Keywords:** Cephalometric analysis – Facial soft tissue profile – Comparison - Ethnic differences.

### Introduction

The quest for a pleasing facial esthetic is one of the main objectives of orthodontic treatments. Many decision aids for diagnosis and treatment have been set up besides clinical observations.<sup>(8,18,19)</sup> Cranium cephalometry, using lateral radiographs is one tool that allows the viewing and measurement of the hard and soft tissues of the cephalic end. The soft tissue profile is as an important orthodontic element for the part it plays in the facial aesthetics. It is thus reasonable to assume that an analysis of facial soft tissue is relevant to diagnosis and therapeutic planning, as its configuration is intimately linked to that of the underlying skeleton.

Several approaches to cephalometric analysis have been developed to interpret the diagnostic features provided by lateral cephalograms.<sup>(2)</sup> They are mostly based on dental skeletal points of interest that are not necessarily compatible with a pleasing facial aesthetic. However, the soft tissues play an important role in the physical and aesthetic appearance of the face. Some approaches have been specifically developed to study the soft tissues including the soft tissue profile.<sup>(4,20,28)</sup>

The criteria of beauty change and differ from one community to another, but have always attracted interest and been of great importance in all cultures. The facial soft tissues may or may not develop in proportion to or

the corresponding skeletal structures. The variations in the depth, length and tonus of the soft tissues can affect the position of the dental skeletal structures, and the relations between them can thus affect the esthetic of the face. A pleasing face can lend its owner a marked psychosocial advantage, just as a facial deformity can adversely affect social acceptance and behavior. Self-esteem seems to be closely linked to facial appearance.<sup>(5,24)</sup>

Clinically, the cephalometric standards are not applicable to all patients because of ethnic characteristics and interbreeding; this implies a need for specific cephalometric norms for each ethnic group. However, cephalometric standards for different ethnic groups must be interpreted carefully.<sup>(3,10,17,23,26,27)</sup> Communities today are more and more multiethnic.

In Côte d'Ivoire, orthodontics is still a recent specialty of odontology. However, the number of patients seeking orthodontic and/or orthognathic surgery treatment is steadily increasing. The Lebanese diaspora forms a firmly settled, integrated ethnic community who work and study in Côte d'Ivoire, which is the African country that has the most Lebanese citizens.

In this social mix, the anthropological and cultural characters of the different ethnic communities are different.

To date, there are no reported studies comparing cephalometric soft tissue values of Ivorian subjects aged 11-16 years.<sup>(1,6)</sup> Likewise, as far as we know, for the Lebanese living in Côte d'Ivoire.

The purpose of this study was to compare the soft tissue profile of Ivorian and Lebanese adolescents with normal skeletal patterns. The null hypothesis tested was that the cephalometric features of the soft tissue profile of the young Lebanese and Ivorian patients were similar.

### Materials and Methods

This was a cross-sectional study of a sample comprising one group of Ivorian and another group of Lebanese girls, all admitted for initial consultation in a private orthodontic practice in Abidjan. These young girls were aged 11-16 years. To be included in this study, the girls had to be 100% native (father and mother) of Côte d'Ivoire or Lebanon.

None of the subjects had any traumatic or orthodontic antecedents, and all presented skeletal class I features, a facial normodivergence and a face well-balanced in appearance. None had orofacial soft tissue pathologies, or craniofacial abnormalities. None had undergone any previous orthodontic, orthognathic, or prosthodontic treatment.

Despite the large numbers of girls presenting at the initial consultations (boys were fewer in number, reflecting local social behavior), very few satisfied all the criteria. Only 34 Ivorian and 32 Lebanese female patients were retained.

For each subject, the lateral cephalogram was extracted from the file for the needs of the study. To be selected, two Ivorian orthodontists consensually judged that on each lateral radiograph, the face was well-balanced after a drawing and some preliminary measures based on the FMA and ANB angles.

All the cephalograms were taken with the same digital lateral cephalography equipment CRANEX Excel Ceph® (SOREDEX). The AGFA X-ray films (8" × 10") were exposed to 80 kVp; 10 mA, 0.8 s at a fixed distance of 2 m following the standard technique. The screens were located 30 cm away from the patients' midsagittal plane. These could be adjusted according to the patient's age and size.

Lateral cephalographs were taken in the natural head position with the eyes straight ahead, the true vertical perpendicular to the floor, and the true horizontal parallel to the floor, with the teeth in maximum intercuspitation and the lips at rest. The true horizontal line (THL) and true vertical line (TVL) were taken as the horizontal and vertical references respectively. The radiographic pictures were obtained with a distance of 130 mm between the source and the cassette.

The cephalometric tracings were made by one operator (BJB), and the landmarks (anatomical landmarks) were verified by another operator (BKAM). No dissonance was observed and the operators were both fully satisfied with the result.

Forty-three variables in reference to the soft tissue profile were studied: face profile angle, nasolabial angle, low-profile of throat angle, lower jaw path, the mandibular path, nasal congestion, nasal projection, lower height of the face, length of upper lip, thickness of upper lip, protrusion of upper lip, exposure of upper incisor, interlabial angle, length of lower lip, height of chin, thickness of lower lip, lower protrusion of lip, sub-nasal area, length of neck and height of lower face.

To facilitate the evaluation of all these cephalometric parameters, they were split into three categories: angular, linear, and proportional (Table 1, Fig. 1)

**Table 1: Soft tissue points**

Landmark Name	Definition
<b>Glabella (G')</b>	Most prominent anterior point in the mid-sagittal plane of the forehead
<b>Soft nasion (N')</b>	Point of greatest concavity in the midline between forehead and nose
<b>Pronasale (Prn)</b>	Most prominent or anterior point of the nose (tip of nose)
<b>Columella (Cm)</b>	Lowest and most anterior point of the nose
<b>Subnasale (Sn)</b>	Point where the columella (nasal septum) merges with the upper lip in the mid-sagittal plane
<b>Labrale superius (Ls)</b>	Most anterior point of the upper lip
<b>Stomion (St)</b>	Junction point between the lowest point of the uppermost point of lips on the vermillion
<b>Labrale inferius (Li)</b>	Most anterior point of the lower lip
<b>Supramentale (Sm)</b>	Deepest point of the lower sub-labial concavity
<b>Pogonion (Pog')</b>	Most anterior point on the chin in the mid-sagittal plane
<b>Menton (Me')</b>	Lowest point on the soft tissue profile of the chin in the mid-sagittal plane
<b>Cervical (C)</b>	Point located at the antero-superior extremity of the neck
<b>Gnathion (Gn')</b>	Point equidistant between point Pog' and point Me'
<b>Suborbitale (Or)</b>	Point palpable with the finger on the lateral edge of the orbit
<b>Porion (Po)</b>	Mid-point of the external acoustic meatus

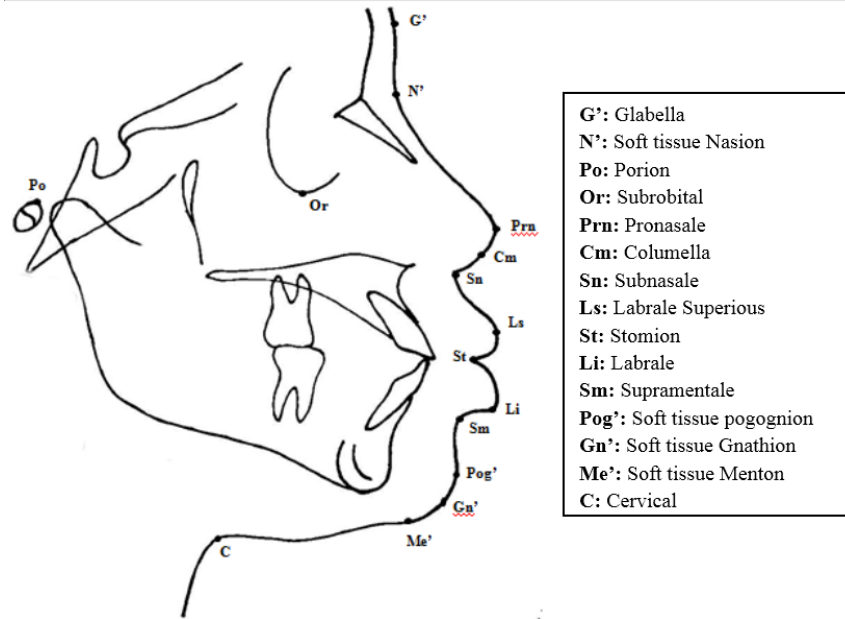


Fig. 1: Landmark points

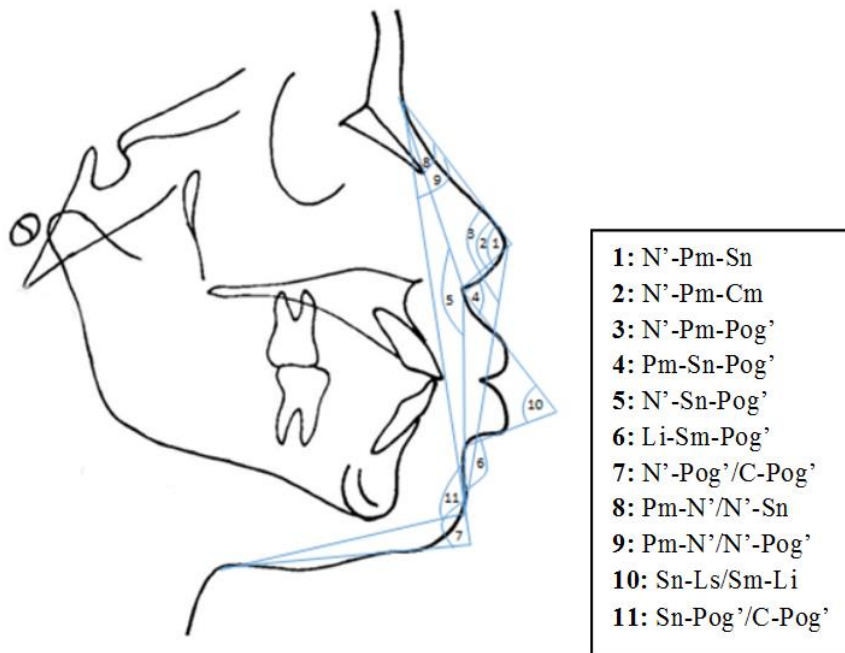


Fig. 2: Angular measures

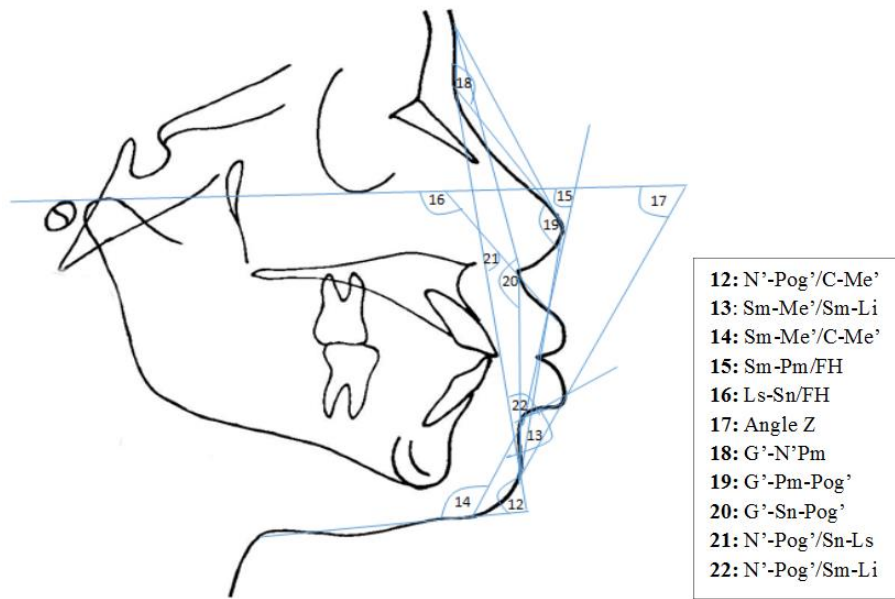


Fig. 3: Angular measures (continued)

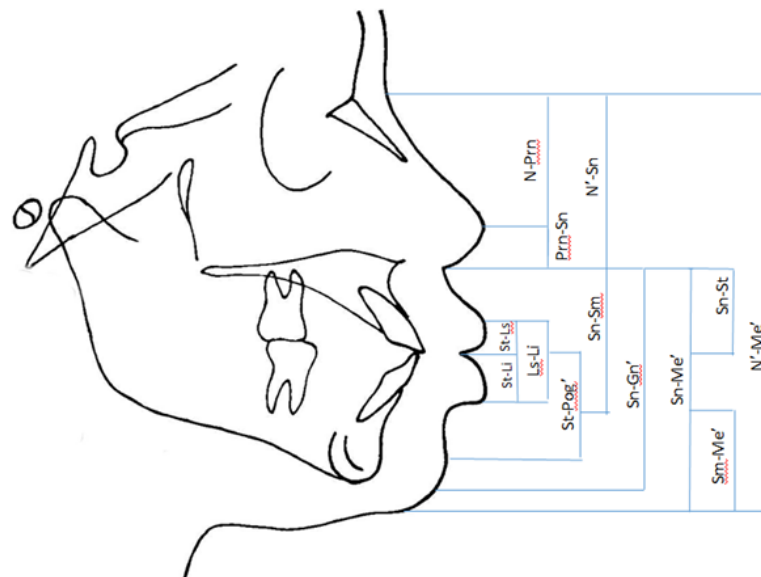


Fig. 4: Linear measures (height)

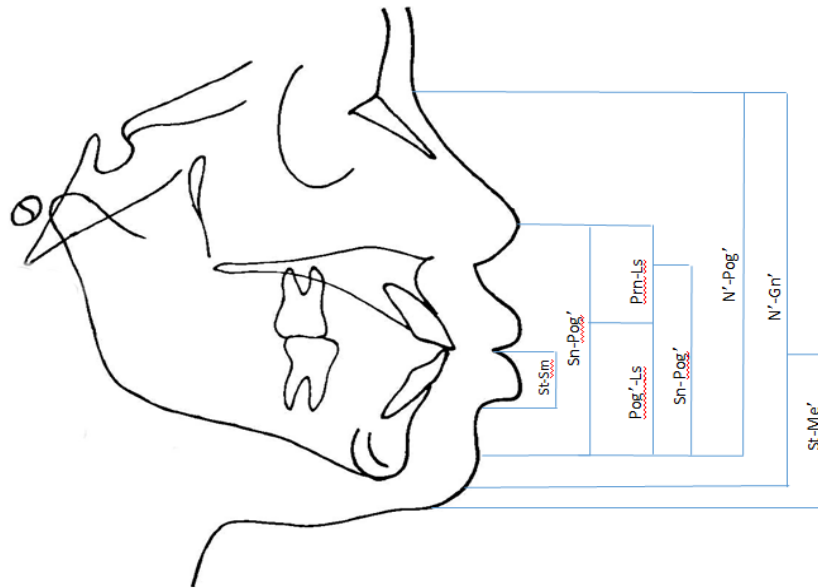


Fig. 5: Height (continued)

**Statistical analyses:**

The data obtained were analyzed using IBM SPSS 20.0 statistical software for Windows. The normal distribution of quantitative variables was verified using a Kolmogorov-Smirnov test.

Student's *t*-test or its non-parametric equivalent was used for comparison of the mean cephalometric values for each ethnic group. Statistical significance was set at  $p < 0.05$ .

A reproducibility test was performed on 20 randomly subjects (10 from each group). Over these 20 radiographs chosen at random, the same measures were made a second time by the same operator (BJB) two weeks later. The error on the method was evaluated with Dahlberg's formula<sup>(12)</sup>:

$Err = \sqrt{\sum d^2 / 2n}$  (10) where *d* is the difference between the two values and *n* is the number of double measures). The errors were not significant, ranging from 0.158 mm to 1.581 mm for the linear variables and from 0.474° to 1.897° for the angular variables. The radiography drafts method was not biased and the identification of the marks was precise. The comparisons of the retraced radiographs found no statistically significant differences between the variables.

**Results**

**Table 2: Methodological cephalometric tracing errors**

Angular measurement	Dahlberg's value (Err)
G'-N'-Prn	1.106
G'-Prn-Pog'	0.948
G'-Sn-Pog'	0.948
G'-Pog'/C-Me'	1.106
N'-Pog'/Sn-Ls	0.948
N'-Pog'/Sm-Li	0.474

N'-Prn-Sn	1.897
N'-Prn-Pog'	0.774
N'-Prn-Cm	1.581
N'-Sn-Pog'	1.739
N'-Pog'/C-Me'	0.625
Li-Sm-Pog'	0.948
Prn-Sn-Ls	1.106
Sn-Ls/Li-Sm	0.79
Sm-Me'/Sm-Li	1.264
Sm-Me'/C-Me'	1.106
Sm-Prn/FH	0.79
Ls-Sn/FH	0.948
Angle Z	0.79
<b>Linear measurement</b>	
N'-Sn	0.948
N'-Gn	1.581
N'-Pog'	0.948
Sn-Me'	1.264
Sn-Gn'	0.948
Sn-Pog'	0.948
Prn-Sn	1.106
Ls-St	0.316
St-Li	0.158
Sn-St	0.79
St-Sm	0.948
Sn-Sm	0.948
Ls-Li	0.474
St-Me'	0.632
Prn-Ls	0.632
Prn-N'	0.79
Pog'-Ls	0.632
St-Pog'	0.316

Sixty-six young girls comprising 32 Lebanese and 34 Ivorians aged 11-16 years were included in this study.

The results comparing the Ivorian and Lebanese girls are presented in Tables 3 and 4. For this comparison of the facial soft tissue profile, 17 linear variables out of 22, and

13 angular variables out of 21 showed significant differences between the two ethnic groups.

**Table 3: Comparison of the girls' angular variables according to ethnic group**

Parameter (°)	Ivorian girls (n = 34)		Lebanese girls (n = 32)		p
	Average	SD	Average	SD	
N'-Prn-Sn	105.706	6.422	103.781	6.384	0.227
N'-Prn-Pog'	136.088	4.137	133.656	7.443	0.017
N'-Prn-Cm	125.09	6.176	124.06	7.571	0.541
N'-Sn-Pog'	160.941	6.638	161.469	5.924	0.735
Li-Sm-Pog'	119.059	11.714	130.094	15.644	0.002
Prn-Sn-Ls	102.47	13.102	130.84	10.885	0.000
Sn-Ls/Li-Sm	82.29	16.361	130.84	17.871	0.000
N'-Pog'/C-Me'	88.794	7.686	94.500	9.899	0.011
N'-Pog'/C-Pog'	102.18	6.608	106.84	7.514	0.009
Prn-N'/N'-Sn	17.00	1.923	18.31	3.042	0.039
Prn-N'/N'-Pog'	26.41	2.732	26.97	3.393	0.464
Sn-Pog'/C-Pog'	111.56	7.333	117.19	7.961	0.004
Sm-Me'/Sm-Li	154.294	10.344	165.219	15.987	0,002
Sm-Me'/C-Me'	129.206	8.738	124.563	9.453	0.042
G'-N'-Prn	140.71	6.987	149.47	8,277	0.000
G'-Prn-Pog'	145.88	4.558	140.09	5.226	0.000
G'-Sn-Pog'	167.94	5.152	164.56	5.842	0.039
N'-Pog'/Sn-Ls	30.53	9.570	7.5	4.265	0.000
N'-Pog'/Sm-Li	66.21	9.425	44.88	12.666	0.000
Sm-Prn/FH	73.32	4.290	65.76	3.811	0.000
Ls-Sn/FH	124.38	11.252	94.92	9.004	0.000
Angle Z	58.882	9.597	73.969	7.715	0.000

**Angular variables:** The angles G'-N'-Prn, N'-Pog'/C-Pog', Prn-N'/N'-Sn, Li-Sm-Pog', Prn-Sn-Ls, Sn-Ls/Li-Sm, Sn-Pog'/C'-Pog', Sm-Me'/Sm-Li and Z were significantly greater for the Lebanese girls (*p* respectively equal to 0.000; 0.011; 0.009; 0.002; 0.000; 0.000; 0.039; 0.004; 0.002 and 0.0001), whereas the

angles Sm-Ch'/C-Ch', Sm-Prn/FH, Ls-Sn/FH, G'-Prn-pog', G'-Sn-Pog', N'-Pog'/Sn-ls, N'-Pog'/Sm-Li presented significantly greater values for the Ivorian girls (*p* respectively equal to 0.042; 0.000; 0.0000; 0.000; 0.000; 0.000 and 0.000) (Table 3)

**Table 4: Comparison of the girls' linear variables according to ethnic group**

Parameter (°)	Ivorian girls (n = 34)		Lebanese girls (n = 32)		p
	Average	SD	Average	SD	
St-Li	13.853	1.708	9.72	2.530	0.000
St-Ls	12.235	2.535	7.56	2.488	0.000
Ls-Li	26.088	3.753	17.19	4.521	0.000
N'-Prn	38.50	5.130	40.28	4.560	0.181
Prn-Sn	11.32	2.446	11.80	1.708	0.507
St-Pog'	30.59	4.113	29.25	5.418	0.261
N'-Sn	49.147	5.743	49.459	9.459	0.000
Sn-Sm	41.588	4.459	34.47	4.799	0.0001
Sn-St	23.26	2.678	18.32	2.839	0.000
St-Sm	18.41	2.388	16.36	2.644	0.000
Sn-Gn'	64.06	6.679	55.64	6.788	0.000
Sn-Me'	67.21	9.250	59.97	6.694	0.001

<b>Sn-Pog'</b>	53.68	6.138		46.60	5.993	0.000
<b>N'-Me'</b>	117.65	11.534		115.88	17.038	0.621
<b>N'-Gn'</b>	110.26	20.938		105.56	14.370	0.030
<b>N'-Pog'</b>	102.765	11.035		97.88	9.94	0.064
<b>St-Me'</b>	44.44	5.690		41.75	4.813	0.043
<b>Prn-Ls</b>	22.06	3.709		22.16	3.060	0.552
<b>Pog'-Ls</b>	41.88	6.333		36.59	5.639	0.001
<b>Sn-Me'/N'-Me'</b>	57.00	4.971		52.19	4.849	0.000

**Linear variables:** Overall, all the statistically different distances (11 variables out of 18) were greater for the Ivorian girls.

The upper face (N'-Sn, N'-Pog', Prn-Sn) did not present any difference between the two ethnic groups. Almost all the variables concerning the convexity of the soft tissue profile, the nose profile, showed differences between the two groups. The nose depth angle was larger, and the nose back angle was smaller for the Lebanese girls but, the tip angle did not show any difference between the two groups.

Regarding the shape of the upper lips, the nasolabial angle was smaller and the angle between FH and the upper lip was wider for the Ivorian than for the Lebanese girls. For the shape of the lower lip, the Z angle was much more closed for the Ivorian girls.

Regarding the shape of the chin, the labial chin angle (Li-Sm-Pog'), the angles N'-Pog'/C-Me' and Z of the Ivorian girls were smaller whereas the angle Sm-Me'/C-Me' was greater.

In the comparison of the position of the lips, the cephalometric analysis showed that the upper and lower lips were positioned further forward the Ivorian girls (Sn-Ls/Li-Sm).

## Discussion

The importance of reviewing the soft tissue profile in the setting of treatment objectives in orthodontic and orthognatic surgery is recognized. An esthetically pleasing face is one of the main objectives. However, the morphology of the soft tissues of the human face and facial esthetic do not always match, and normative data based on a given community cannot be applied to all. The esthetic of the face depends on the contours of both the soft and hard tissues. A pleasing face can be a great asset for its owner just as a facial deformity can adversely affect social acceptance and behavior.<sup>(5,24)</sup>

The influence of the skeletal structures on the shape of the face is a known and accepted fact. However, it is important to remember that the soft tissues that cover the bone surface of the face are equally important for the stability of the dental arch as for esthetics.<sup>(8,19,20)</sup>

In this study, 43 cephalometric variables of young Ivorian and Lebanese girls aged 11-16 years were recorded. These girls were referred patients for orthodontic treatment in a private orthodontic practice in Abidjan. They would therefore potentially carry certain

dental skeletal anomalies. In this study, establishing cephalometric norms or standards for either the Ivorian or the Lebanese subjects was not the issue.

The determination of standards implies that subjects whose radiographs are analyzed already have a pleasing facial harmony, and normal inter-arch arrangement and inter-arch relations. It would thus have been necessary to take radiographs of subjects that would not really have needed them. This would mean undertaking a study without any direct individual advantage. Exposing patients to ionizing radiation solely for a research also poses ethical problems.

As the profile changes depend on facial typology, this study involved only subjects in skeletal class I and normodivergent. In other words, various dental malocclusions could readily occur in such subjects despite a balanced face. For example, Casco and Shepherd<sup>(9)</sup> found that the cephalometric values for a sample of normal occlusions were very variable, far outside the average values frequently presented as treatment objectives.

For that reason, this study selected girls considered as having balanced faces. Such a selection was easy because of the high number of consultations for girls in Ivorian communities. The number of boys that satisfied all the conditions was too low for their inclusion in this study.

The orthodontic literature reports several studies that have involved ethnic differences in the facial soft tissue profile, but none analyzed the telerradiographs of the profile of two ethnic groups living in Côte d'Ivoire (the Ivorian and Lebanese communities). For this study, the two groups were directly compared. A single operator dealt with the two groups in order to eliminate between-operator errors.

Statistically, several significant differences appeared between the Ivorian and Lebanese girls.

The nasal frontal angle (G'-N'-Prn) was smaller for the Ivorian girls, indicating their prominent facial profile. The Lebanese girls had a less marked nasal saddle than the Ivorian girls. This could be linked to a less prominent forehead for the Lebanese girls rather than a less protruding nose. The facial convexity including the nose and starting from the soft nasion (N'-Prn-Pog') did not present any significant difference between the two groups, while the facial convexity starting from the glabella (G'-Prn-Pog') was significantly more pronounced for the Ivorian girls. The

angle of the nasal tip did not present any difference between the two groups. The lack of any difference between the variables involving the soft nasion indicates a similarly shaped mid-face.

Diouf et al<sup>(13)</sup> carried out a photographic study on a sample of Senegalese and Moroccan patients and found results that differ from ours. The nasal frontal angle did not present any significant difference between the Moroccans and the Senegalese. Our values for this variable were lower than those of Diouf et al ( $153.08 \pm 6.69$  for the Senegalese against  $154.43 \pm 8.60$  for the Moroccans) but slightly higher than those of Oghenemavwe et al<sup>(21)</sup> ( $134.29 \pm 9.18$ ) for Igbo women in Nigeria). These variances in the results could be explained by the marked in the evaluation tools: photography vs radiography.

However, when the methodology is similar, our results come closer to the study of Fadeju et al<sup>(15)</sup> who found a nasal frontal angle of  $139.18 \pm 8.17$  among teenagers in the West Africa.

In subjects with normal profile, soft tissue facial growth has generally similar amount and rates irrespective of the ages herein investigated and pubertal growth spurt, with only few exceptions.<sup>(22)</sup>

A close analysis of the results reported by different studies on this issue of gender differences in soft tissue profile suggests that post-pubertal maturational changes may be involved. It has been shown that angular parameters associated with the nasal complex remain relatively constant during childhood with a steady change from 13 to 18 years old.<sup>(16)</sup>

Regarding the comparison of soft tissue values found in the whole of our sample with those published for West African adolescents and for Caucasian subjects of a similar age group, important differences can be noted.

Throughout this study, the convexity of the soft profile was the same between the two groups. However, the significantly smaller angles N'-Pog'/C-Ch', N'-Pog'/C-Pog' and Sn-Pog'/C-Pog' for the Ivorian girls could indicate a retrusive chin for the Lebanese girls. The wider opening of the Prn-Sn-Ls and Sn-Ls/Li-Sm angles for the Lebanese girls indicates that these had a less convex facial profile.

According to previous longitudinal studies<sup>(11,25)</sup> changes of facial convexity have been demonstrated in pre-pubertal subjects and relative stability in facial convexity after 6 years of age has been reported.<sup>(7)</sup>

Significantly marked differences between the two groups appeared in the lip region. The upper lip relative to the Frankfurt plane (FH) and the lower lip to the NP angle were greater for the Ivorian girls, indicating more prominent lips for the latter.

As a result of the more retrusive position of the upper and lower lips, we found wider nasal labial and chin labial angles for the Lebanese girls.

The lips were thicker heightwise for the Ivorian girls, and the significantly higher values of St-Li, St-Ls, Ls-Li and Sn-St reflect more elongated and so more

fleshy lips for the Ivorians. Diouf et al<sup>(13)</sup> found similar results. We did not find any statistically significant difference in terms of the linear variables of mid-face. Only the lower face presented a significant difference with high values of Sn-Ch', St-Mé' and Sn-St for the Ivorian girls, which could mean that the oral level predominates over the ventilatory level for the Ivorian compared with the Lebanese girls.

This is a totally different result from that of Diouf et al.<sup>(13)</sup> It may be relevant to facial esthetic appraisal as suggested by Espinar-Escalona et al.<sup>(14)</sup> For these authors, the vertical and subnasal sagittal measures of the lower third of the face are crucial for the esthetic of the face. Hence, these esthetic parameters could be used as an objective tool for the planning of orthodontic treatment.

Overall, the comparative results show that the Ivorian girls had an ethnically specific facial shape compared with the Lebanese girls.

These differences are worth considering when drawing up an orthodontic treatment plan for patients with different ethnic origins. The results of this study have implications for diagnosis and treatment of the Lebanese and Ivorian patients who come to the same orthodontic consultation.

## Conclusion

Cephalometric analysis of the facial profile and a statistical study of the data obtained enabled us once again to highlight morphological differences from one population to another, according to their ethnic group. Girls of Ivorian origin had an ethnically specific facial profile compared with Lebanese girls. The Ivorian girls were distinguished by prominent lips and closed nasal labial and mental labial angles, and thus an overall more convex face. The average values for these lip positions could be used as a reference in the orthodontic diagnosis of Ivorian girls. The Lebanese girls had thinner and less elongated lips and a smaller lower face.

These differences should be considered when establishing an orthodontic treatment plan for patients of different ethnic origins.

Further work is now needed to assess the diagnosis value of these cephalometric models more thoroughly.

## Disclosure of Interest

The authors declare that they have no conflicts of interest concerning this article.

## References

1. Agneroh-Eboi G, Crocquet M, Thilloy G, et al (1989) Craniofacial anatomo-morphological profile of black African Ivory Coast children. *Odontostomatol Trop* 12:111-12.
2. Ajayi EO (2005) Cephalometric norms of Nigerian children. *Am J Orthod Dentofac Orthop* 128:653-56.
3. Al-Gunaid T, Yamada K, Yamaki M, Saito I (2007) Soft tissue cephalometric norms in Yemeni men. *Am J Orthod Dentofac Orthop*. 132:576.e7-576.e14.



4. Bergman RT (1999) Cephalometric soft tissue facial analysis. *Am J Orthod Dentofac Orthop* 116:373-89.
5. Beugre JB, Beugre-Kouassi AML, Sonan NK, Ndindin-Guinan B, Fareou P, Faure J, Djaha K (2005) Comparative cephalometry and facial esthetic preferences in Subsaherian black Africa. *Biom Hum et Anthropol* 1-2:63-72.
6. Beugre JB, Sonan NK, Beugre-Kouassi AM, Djaha K (2007) Comparative cephalometric study of three different ethnic groups of black Africa with normal occlusion. *Odontostomatol Trop* 30:34-44.
7. Bishara SE, Jakobsen JR, Hession TJ, Treder JE (1998). Soft tissue profile changes from 5 to 45 years of age. *American Journal of Orthodontics and Dentofacial Orthopedics*, 114: 698–706.
8. Burstone CJ (1967) Lip posture and its significance in treatment planning. *Am J Orthod* 53:262-84.
9. Casco JS, Shepherd WB (1984) Dental and skeletal variation within the range of normal. *Angle Orthod* 54(1):5-17.
10. Celebi AA, Gelgor IE, Colk T, Ayyildiz (2013) Comparison of soft tissue cephalometric norms between Turkish and European-American Adults. *Scientific World Journal* 2013:806203.doi :10.1155.
11. Chaconas SJ, Bartroff JD (1975) Prediction of normal soft tissue facial changes. *The Angle Orthodontist*, 145:12-25.
12. Dahlberg G. (1940) *Statistical Methods for medical and biological Students*. London, G. Allen & Unwin Ltd.
13. Diouf JS, Ngom PI, Fadiga MS, Badiane A, Diop-Ba K, Ndiaye M, Diagne F (2015) Vertical photogrammetric evaluation of the soft tissue profiles of two different racial groups : A comparative study. *Int Orthod* 13(2):149-63.
14. Espinar-Escalona E, Ruiz-Navarro M-B, Barrera-Mora J-M, Llamas-Carreras J-M, Puigdollers-Perez A, Ayala-Puente J (2013) True vertical validation in facial orthognathic surgery planning. *J Clin Exp Dent* 5(5):e231-8.
15. Fadeju A D, Otuyemi O D, Ngom P I; Newman-Nartey M (2013) A study of cephalometric soft tissue profile among adolescents from the three West African countries of Nigeria, Ghana and Senegal. *Journal of Orthodontics* 40(1):53-61.
16. Genecov JS, Sinclair PM, Dechow PC (1990) Development of the nose and soft tissue profile. *Angle Orthod* 60:191-98.
17. Hashim HA, Al-Barakati SF (2003) Cephalometric soft tissue profile analysis between two different ethnic groups: a comparative study. *J Contemp Dent Pract* 2:60-73.
18. Holdaway RA (1983) A soft tissue cephalometric analysis and its use in orthodontic treatment planning. Part-I. *Am J Orthod* 84:1-28.
19. Holdaway RA (1983) A soft tissue cephalometric analysis and its use in orthodontic treatment planning. Part-I. *Am J Orthod* 85:279-93.
20. Merrifield LL (1966) The profile line as an aid in critically evaluating facial esthetics. *Am J Orthod* 52:804-22.
21. Oghenamavwe EL, Osuwoke AE, Ordu KS, Omovigho O (2010) Photometric analysis of the soft tissue facial profile of adult urhobos. *Asian J Med Sci* 2(6):248-524.
22. Primozic J, Perinetti G, Contardo L, Ovsenik M (2017) Facial soft tissue changes during the pre-pubertal and pubertal growth phase: a mixed longitudinal laser-scanning study. *Eur J Orthod* Feb; 39(1):52-60
23. Raghav S, Baheti K, Hansraj V, Rishad M, Kanungo H (2014) Soft tissue cephalometric norms for Central India (Malwa) female population. *J Int Oral Health* 6(5):51-59.
24. Shaw WC (1981) The influence of children's dentofacial appearance on their social attractiveness as judged by peers and lay adults. *Am J Orthod*. 79:399-415.
25. Subtenly J.D (1959) A longitudinal study of soft tissue facial structures and their profile characteristics, defined in relation to underlying skeletal structures. *American Journal of Orthodontics* 45:481-507.
26. Sutter RE, Turley PK (1998) Soft tissue evaluation of contemporary Caucasian and African American female facial profiles. *Angle Orthod* 68(6):487-496.
27. Upadhyay JS, Maheshwari S, Verma SK, Zahid SN (2013) Soft tissue cephalometric analysis applied to regional Indian population. *Natl J Maxillofac Surg* 4(2):159-66.
28. Zylinski CG, Nanda RS, Kapila S (1992) Analysis of soft tissue profile in white males. *Am J Orthod Dentofac Orthop* 128:653-56.