

Effect of Quad Helix appliance on maxillary constriction (holdway measurements)

Maher Fouda¹, Ahmed Hafez², Hawa Shoaib^{3,*}

¹Professor, ²Lecturer, ³PG Student, Dept. of Orthodontics, Faculty of Dentistry, Mansoura University, Egypt

***Corresponding Author:**

Email: hawaali60@gmail.com

Abstract

Objective: to evaluate expansion changes by removable Quad helix appliance on soft tissues profile in growing patients.

Materials and Method: the present prospective clinical study consisted of fifteen subjects (8 girls and 7 boys) with cross bite due to constricted maxillary arch. Cases were selected to be treated for 8 months.

Results: No significant difference Soft tissue facial angle, H angle, SK profile convexity, Soft tissues chin thickness, Superior sulcus depth, Nose prominence and significant difference of Basic upper lip thickness and Upper lip thickness.

Conclusion: the effect of expansion by Quad helix appliance on soft tissue facial angle, H angle and profile convexity showed insignificant changes after the expansion period and significant change of upper lip thickness and Basic upper lip thickness.

Keywords: Constricted maxilla, Expansion, Cross bite, Growing patients, Quad helix appliance, Soft tissues, Holdway measurements.

Introduction

Many patients have a noticeable cross bite of the buccal segments when their occlusion is in maximum inter cuspatation.⁽¹⁾

Posterior cross bite is one of the most common malocclusions in the young patients.⁽²⁾ Posterior cross bite is defined as any abnormal buccolingual relation between opposing molars, premolars or both in centric occlusion.⁽³⁾

The etiology of posterior cross bite can include any combination of dental, skeletal, and neuromuscular functional components, sucking habit, obstruction of the upper airway, and certain swallowing patterns have been identified as etiologic factors of the posterior cross bite.⁽⁴⁾

The early correction of posterior cross-bites requiring maxillary expansion has been advocated to redirect the developing teeth into more normal positions, eliminate untoward temporomandibular joint positions and mandibular closure patterns, and make beneficial dentoskeletal changes during growth periods involving a reduced treatment complexity and time.⁽⁵⁾

Various modes of posterior cross bite correction have been suggested, including rapid maxillary expansion, slow expansion with the quad-helix and removable expansion plates.⁽⁶⁾

Three expansion treatment modalities are used today: rapid maxillary expansion (RME), slow maxillary expansion (SME) and surgically assisted maxillary expansion, Practitioners select treatment appliances based on their personal experiences and on the patient's age and malocclusion.⁽⁷⁾

Animal studies suggest that SME (slow maxillary expansion) maintains sutural integrity during expansion, producing a more stable result than RME (rapid maxillary expansion).⁽⁸⁾

Orthodontic expansion can cause increases in arch perimeter and the correction of dental crowding and

constricted maxilla.⁽⁹⁾

Slow expansion by The quad-helix produces forces between 180 and 667 g, depending on the material used, and the length and the size of the wire.⁽¹⁰⁾

The main advantages offered by the quad-helix appliance are that child or parent compliance with the treatment is not strictly necessary and that the patient enjoys greater comfort and better adaptation.⁽¹¹⁾ Quad helix delivers a constant physiologic force until the required expansion is obtained.⁽¹²⁾

Some investigation of the soft tissue profile in cleft lip and palate patients during maxillary expansion with a quad helix, found no significant changes.⁽¹³⁾

The soft tissue profile plays an important part in our orthodontic considerations. Usually, as we correct malocclusions, we bring about changes in appearance that are pleasing to all concerned. However, most orthodontists who have practiced for even a few years have had the unpleasant experience of finding that some patients 'faces looked better before the orthodontic corrections were made'.⁽¹⁴⁾

Materials and Method

The sample of this study was consisted of fifteen patients, each enrolled patient had the procedures explained, their questions answered and a written consent was signed by the patients' guardians. All patients were selected from the clinic of Orthodontics department, faculty of dentistry, Mansoura University according to following criteria:

- Constricted maxillary arch.
- Age ranged from 6-12 years old.
- Fully erupted maxillary first permanent molar.
- Free from any congenital anomalies or systemic disease that might have an influence on tooth movement.
- Good oral hygiene

The Quad Helix has 4 spiral helicoidal bends, two on the anterior zone, which must descend from the bridge to the palate, and the other two are located slightly behind the molar band, to allow rotation and molar expansion. The Quad helix appliance removable ready-made 0.9 mm stainless steel wire Mobile intra oral arch system (MIA) inserted in the palatal sheaths of the band molar (Fig. 1).

The Quad helix appliance activation was activated with three prong pliers outside of patient mouth. Verification of activation amount was by inserting one retention loop and observing the relationship of the other retention loop to its sheath, repeated on opposite side to confirm was done.

- Activation the posterior helical loops were move the free wires buccally.
- Activation the anterior helical loops were move the molar bands buccally.

New activations was be posted on 40 – 40 day period; on majority of cases the activation were not exceed 1- 2 mm in order to keep case under control. The arch arms contacts all posterior teeth, the contacts was close to but not touched the soft tissue at the cervical margin.

Patients were appointed every week for evaluation and instructed to clean the appliance after every meals daily by tooth brush and mouth wash and call us if any emergency was happened. When the palatal cusp tips of the maxillary first molars were in contact with the corresponding buccal cusps of the mandibular first molars, expansion was rendered complete and post expansion records were obtained. Case presented before

and after treatment Fig. 2, 3 and soft tissues landmark Fig. 4.

The same appliance was left in place as a retainer for 3-4 months during second phase of treatment (Fig. 5).

Each patient had their panoramic, lateral cephalometric x-rays before and just after the expansion. Hand wrist was taken only before treatment for growth and maturity indication.

Lateral cephalometric radiographs were performed in a standardized fashion by the same technician. All cephalometric radiographs were hand traced by the same examiner soft tissue measurements (Table 1) were utilized for the evaluation of soft tissue changes. Linear and angular measurements were carried out on each radiographic image. The landmarks were located and the measurements according to the definitions provided by Holdaway (1983).

Statistical analysis: The distributions of quantitative variables of soft tissues measurements were tested for normality. Significance of the obtained results was judged at the 5% level. Paired t-test was used for normally quantitative variables, to compare between pre and post-expansion (T1 and T2) respectively.

Results

All included cases successfully achieved the intended expansion in 3 to 4 months. The values of the lateral cephalometric variables, before and immediately after expansion, Table 1, showed significant increase in the means of Upper lip thickness (.054) and Basic upper lip thickness (.039) with no apparent alteration in soft tissues facial angle and H angle.

Table 1: Soft tissues findings before treatment (T1), after expansion (T2) and the mean difference of each variable before and after expansion (T2-T1)

Measurements	Pre-expansion (T1)		Post- expansion (T2)		Mean	S.D	P values
	Mean	S.D	Mean	S.D			
Angular							
Soft tissue facial angle (°)	90.056	3.8927	91.056	2.8553	1.0000	2.8395	.322
H angle (°)	20.167	1.6202	21.222	2.8186	1.0556	2.9202	.310
Linear							
SK profile convexity	3.5278	.50690	3.056	1.3333	.47222	1.07851	.225
Upper lip thickness	11.000	1.9365	9.444	2.2973	1.5556	2.0683	.054
Basic upper lip thickness	11.556	1.6667	12.444	1.8105	.8889	1.2693	.039
Soft tissues chin thickness	9.278	2.4381	9.444	2.8333	.1667	1.2247	.694
Superior sulcus depth	3.833	2.1213	3.111	1.0541	.7222	1.3017	.135
Nose prominence	8.844	2.2176	9.333	1.5000	.4889	1.9624	.476




Fig. 1: The Quad Helix Expander

- (a) lateral arms left and right sides
- (b) Anterior bridge
- (c) Posterior bridge
- (d) Anterior helix
- (e) Posterior helix

Fig. 2: Case presented before expansion

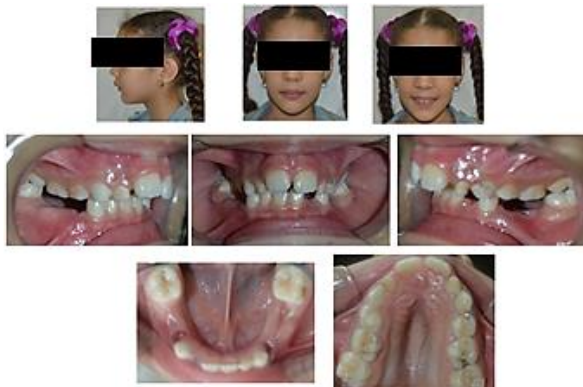

Fig. 3: Case presented after expansion

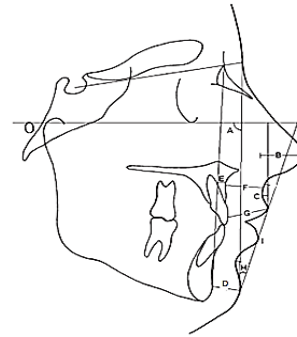
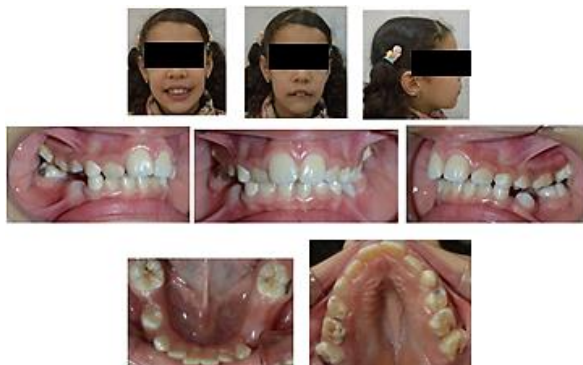

Fig. 4: Soft tissues Land mark Points

- A, soft tissue facial angle
- B, nose prominence
- C, superior sulcus depth
- D, soft tissue chin thickness
- E, skeletal profile convexity
- F, basic upper lip thickness
- G, upper lip thickness
- H, H angle

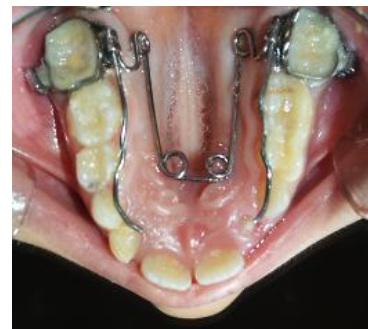

Fig. 5: The Quad Helix inserted in palatal sheath and the arch arms contacts all posterior teeth

Conclusion

- The soft tissue facial angle, H angle and profile convexity showed insignificant changes after the expansion period.
 - Significant increase in upper lip thickness and Basic upper lip thickness after the expansion period.
- SME procedures may affect soft tissue measurements, and these effects should be taken into consideration when utilizing SME.

Discussion

The lower face, besides its functions (digestion, speech and respiration), influences the social acceptance and psychological wellbeing of the individual. According to that author, appearance is one of the primary functions of the face.⁽¹⁵⁾

The improvement of facial aesthetics has rapidly become one of the desirable objectives of orthodontic

treatment. As orthodontic diagnosis and treatment planning have become more sophisticated and scientific, clinicians should be aware of possible changes in the hard and soft tissues in producing a well-proportioned, balanced, and harmonious soft tissue facial profile at the end of orthodontic treatment.^(16,14,17)

the soft tissues, not the skeletal proportions, should be the goal of orthodontic treatment, The relationships between nose, lips, and chin can be altered by both growth and orthodontic treatment.⁽¹⁸⁾

There is a strong, but complex, relationship between hard and soft tissue changes.⁽¹⁹⁾ While the maxilla and maxillary incisors moved anteriorly because of expansion, the nose tip and soft tissue point A followed the hard tissue movements. However, Tindlund and Rygh (1993) found no significant change in the soft tissue profile during the maxillary expansion period. This finding is coincident with the results of the present study.⁽¹³⁾ This agree may be explained by the fact that those authors carried out maxillary expansion in cleft lip and palate patients using a quad helix appliance.

In the present study, no statistically significant change in soft tissue chin and nose prominence was after the expansion period, with there is no forward movement of the maxilla together with the clockwise rotation of the mandible resulted in an no significant change in skeletal profile convexity.

Also there was significant increase in upper lip thickness and Basic upper lip thickness due to dentally effect of the expander and increasing arch perimeter of maxilla.

Several studies have addressed the effects of different orthodontic and orthopedic treatment modalities on facial soft tissues.^(20,21,22) Unfortunately, there is a limited database of evidence of the soft tissue changes subsequent to SME.

Contribution of Knowledge

The quad-helix appliance developed with a vision to generate low force magnitudes. The inclusion of four helical loops in the design led to increased appliance size and improved the system's flexibility. The patient enjoys greater comfort and better adaptation.

References

1. Binder RE. Correction of posterior crossbites: diagnosis and treatment. *Pediatr Dent* 2004;26(3):266–72.
2. Petré S., Bjerklin K., Marké LÅ., Bondemark L. Early correction of posterior crossbite-a cost-minimization analysis. *Eur J Orthod* 2013;35(1):14–21.
3. Arvinth R., Rana S., Duggal R., Kharbanda O. Simultaneous correction of functional posterior cross bite and midline shift. *Contemp Clin Dent* 2016;7(3):413.
4. Toroglu MS., Uzel E., Kayalioglu M., Uzel I. Asymmetric maxillary expansion (AMEX) appliance for treatment of true unilateral posterior crossbite. *Am J Orthod Dentofac Orthop* 2002;122(2):164–73.
5. Bell A. A review of maxillary of expansion and patient ' s age. *Am J Orthod* 1982;81(1):32–7.
6. Petré S., Bondemark L. Correction of unilateral posterior crossbite in the mixed dentition: A randomized controlled trial. *Am J Orthod Dentofac Orthop* 2008;133(6):7–13.
7. Argawal A. Maxillary Expansion. *Int J* 2010;3(December):139–46.
8. Wong CA., Sinclair PM., Keim RG., Kennedy DB. Arch dimension changes from successful slow maxillary expansion of unilateral posterior crossbite. *Angle Orthod* 2011;81(4):616–23.
9. Germane N., Lindauer SJ., Rubenstein LK., Revere JH., Isaacson RJ. Increase in arch perimeter due to orthodontic expansion. *Am J Orthod Dentofac Orthop* 1991;100(5):421–7.
10. Corbridge JK., Campbell PM., Taylor R., Ceen RF., Buschang PH. Transverse dentoalveolar changes after slow maxillary expansion. *Am J Orthod Dentofac Orthop* 2011;140(3):317–25.
11. Vizzotto MB., de Araújo FB., da Silveira HED., Boza AA., Closs LQ. The quad-helix appliance in the primary dentition--orthodontic and orthopedic measurements. *J Clin Pediatr Dent* 2008;32(2):165–70.
12. Marzban R. slow maxillary expansion with Nickel Titanium. *JCO* 1999;XXXIII(8).
13. Tindlund R S R. Soft-tissue profi le changes during widening and protraction of the maxilla in patients with cleft lip and palate compared with normal growth and development. *Cleft PalateCraniofacial J* 1993;(30):454 – 468.
14. Holdaway RA. use in orthodontic treatment planning. Part I. *Am J Orthod* 1983;84(1).
15. Arnett GW., Jelic JS., Kim J., Cummings DR. Soft tissue cephalometric analysis : Diagnosis and treatment planning of dentofacial deformity. *Am J Orthod Dentofac Orthop* 1999:239–53.
16. Ricketts RM. Esthetics, environment, and the law of lip relation. *Am J Orthod* 1968;272 – 289(54).
17. Merrifield L L. The profile line as an aid in critically evaluating facial esthetics. *Am J Orthod* 1966;804 – 822(52).
18. Nanda R S, Meng H, Kapila S G. Growth changes in the soft tissue facial profi le. *Angle Orthod* 1990:60 : 177 – 190.
19. Ksai K. Soft tissue adaptability to hard tissues in facial profiles. *Am J Orthod Dentofac Orthop* 1998;674 – 684(113):674–84.
20. Bravo L A. Soft tissue facial profi le changes after orthodontic treatment with four premolars extracted. *Angle Orthod* 1994:64 : 31 – 42.
21. Quintão C., Brunharo IHVP., Menezes RC., Almeida MAO. Soft tissue facial profi le changes following functional appliance therapy. *Eur J Orthod* 2006;28(August 2005):35–41.
22. Basciftci FA., Uysal T., Buyukerkmen A. The Influence of Extraction Treatment on Holdaway Soft-Tissue Measurements. *Angle Orthod* 2004;74(2).