

## The role of orthodontist in distraction osteogenesis

Vedavathi H.K.<sup>1</sup>, Chirag Arora<sup>2,\*</sup>, Bharath Reddy<sup>3</sup>, Sowmya K.S.<sup>4</sup>, Goutham N<sup>5</sup>

<sup>1,3,4,5</sup>Reader, <sup>2</sup>PG Student, Dept. of Orthodontics, V.S. Dental College & Hospital, Bengaluru, Karnataka

**\*Corresponding Author:**

Email: arora.9090@gmail.com

### Abstract

Although orthognathic surgery has gained recognition over the last few decades it still has not overcome several limitations like acute advancement of bone segments and adaptation of soft tissue relative to the new position. With the advent of distraction osteogenesis these limitations have been omitted. Recently, several experimental and clinical investigations have established that controlled progressive mechanical traction of bone segments at an osteotomy site created in the craniofacial region can form new bone parallel to the direction of traction. Thorough planning, careful evaluation and communication between the orthodontist and maxillofacial surgeon is the key to a successful outcome of the treatment and resolution of malocclusion. In addition, management of dentition prior to distraction need careful assessment for better finish of occlusion after distraction osteogenesis has been performed. Hence, the purpose of this article is to review the historic development and biologic foundation of mandibular distraction osteogenesis, and role of orthodontist in distraction osteogenesis.

**Keyword:** Distraction osteogenesis, Soft tissue capsule, Neuromuscular

### Introduction

Facial asymmetry, mandibular hypoplasia, and congenital malformation of jaws are common abnormalities of the craniofacial complex. Traditionally, skeletal deformities have been corrected via functional orthopedics in growing patients or orthognathic surgery with skeleton fixation in non-growing patients.<sup>(1-4)</sup> Adaptation and stability of the adjacent muscles and soft tissues are one of the limitations and controversies related to orthognathic surgery and functional orthopedics.<sup>(2,4,5)</sup> Many congenital deformities require large amount of skeletal movements which is perhaps not possible with orthognathic surgery may lead to compromise in function and esthetics.<sup>(6-7)</sup> One of the major demerits of orthognathic surgery is that it permits only acute changes in the spatial arrangement of skeleton rather than provide de novo bone formation and which requires the needs of bone graft. It does not permit the change in shape and size of the bones to maximize the structural integrity, functional balance and esthetic of the patient.

Taking into account of these limitations, recent approaches have been directing at new bone growth which is called as "distraction osteogenesis". Distraction Osteogenesis is defined as the creation of de novo bone and adjacent soft tissue after the gradual and controlled displacement of a bone fragment obtained by surgical osteotomy. Periosteal matrix adjacent to skeletal tissue have been noted to form under stress, which includes mucosa, skin, tendon, muscle, blood vessel, cartilage and peripheral nerves.<sup>(8-15)</sup> Steady bone remodeling, in varied directions without surgical interventions is now possible by utilization of distraction osteogenesis. The traction by the distractor appliance institutes tension within the callus which stimulates new bone formation parallel to the vector of

distraction. By applying distraction forces sequence of adaptive changes surrounding periosteal matrix is propagated, termed as distraction histogenesis. Due to the influence of tensional stresses generated by gradual distraction, active histogenesis occurs in surrounding tissues. These adaptive changes may permit larger skeletal movements while diminishing the potential relapse seen in acute orthopedic corrections.

Distraction process includes following fundamental sequential phases in which different biologic phenomenon are induced.

1. Osteotomy cut
2. Latency period
3. Distraction phase
4. Consolidation phase

The distraction technique presents wide possibilities of use in some areas of dentistry, i.e. surgical orthodontics, facial orthopedics and in oral rehabilitation where one of the major problems is the alveolar bone loss for the support for prosthesis, implantation and adjacent soft tissues. Recent clinical reports have acknowledged the successful application of osteodistraction in treating skeletal deformities of the craniofacial region.<sup>(16-33)</sup> The use of gradual incremental traction of the mandible has allowed up to 20 mm of lengthening with no associated pain. Because these conditions are typically treated by a team approach, a thorough understanding of the evolution and future development of osteodistraction is of paramount importance to the orthodontist.

### History

The progression of craniofacial distraction osteogenesis was based on the development and refinement of dentofacial traction, craniofacial osteotomies, and skeletal fixation methods. Later, modifications of these techniques were merged into

osteodistraction procedures that were finally standardized based on experiences with distraction osteogenesis on long bones.

The application of tensile and compressive forces to bones of the craniofacial skeleton in the field of orthodontics and dentofacial orthopedics is not a new concept. Since eighteenth century principles of dental traction for the correction of skeletal deficiencies have been popular in dentistry. In 1728, Pierre Fauchard illustrated the use of the expansion arch. When the metal plate was ligated to the crowded dentition, the teeth were widened to a normal form. However, the limitation of this form of traction was that only tooth movement arose with little effect on the skeletal tissue.

In 1859, Wescott was the first who reported the implementation of mechanical forces on the bones of the maxilla. He used two double clasps separated by a telescopic bar to correct a crossbite in a 15-year-old girl. However, the demerits of this procedure were that it was slow and tedious and prolonged treatment duration. Later on, Angell performed a similar procedure with a differentially threaded jackscrew connected to the premolars. Palatal expansion was achieved through the separation of the maxillary bones at the midpalatal suture in 2 weeks. A new protocol for palatal expansion was further standardized by Goddard in 1893. He activated the device twice a day for 3 weeks followed by a stabilization period to allow the deposition of "osseous material" in the created gap.

In 1905, Alessandro Codivilla<sup>(34)</sup> introduced surgical techniques for lengthening of the lower extremities. In 1934, the New York hospital for joint disease worked on an early method developed by Illizarov. The US team of surgeons came up with the concept of metal frame to hold the limb in place until the healing was complete. Major amelioration came with a technique introduced by Russian orthopedic surgeon Gavril Illizarov. He developed procedure which induced new bone formation and regeneration of surrounding soft tissues under the tension.<sup>(35-36)</sup>

According to Wassmund in 1927,<sup>(37)</sup> intraoral tooth borne appliances for first mandibular distraction osteogenesis which was gradually activated over a period of 1 month which was carried out by Rosenthal. In 1937, Kazanjian<sup>(38)</sup> implemented a new protocol for mandibular osteodistraction by using gradual incremental fraction. After L-Shaped osteotomies in corpus he attached a wire hook to the symphysis, thereby providing direct skeletal fixation.

In 1948, even though Crawford<sup>(39)</sup> followed gradual incremental traction to fracture the callus of mandible, this technique did not gain immediate acceptance.

In 1957, Traucher and Obwegeser<sup>(2)</sup> introduced the concept of sagittal split osteotomy. Various experimental studies were carried out using distraction device in craniofacial bones in 1976 on animals, specially dogs. The first publication that enlightened the

application of Illizarov's principle to the mandible appeared in 1973 by Snyder et al.

External fixation device for mandibular lengthening was first applied given by McCarthy in 1989. Illizarov (1990) showed that the fibrous matrix in the tensioned area was capable of differentiating by itself into lamellar bone tissue. He entitled the so called "Illizarov effect". A comprehensive analysis of distraction regeneration at different stages of formation was given by Karp and co-workers based on experimental studies in 1990.

McCarthy et al (1992)<sup>(40)</sup> was the first author to relate distraction osteogenesis application in human. Querido and Fan were among the first authors to use an intra-buccal distraction in human for orthopedic corrections.

### Indications of Mandibular Distraction Osteogenesis<sup>(41-43)</sup>

1. Severe mandibular retrognathia/micrognathia
2. Craniofacial syndromes: hemifacial microsomia, Treacher Collins syndrome, Nager syndrome, Pierre Robin sequence
3. Severe mandibular asymmetry
4. Post-traumatic deficient mandibular growth and temporomandibular joint ankylosis
5. Revision mandibular orthognathic surgery
6. Mandibular retrognathia with temporomandibular joint disease or juvenile rheumatoid arthritis
7. Mandibular retrognathia with obstructive sleep apnea
8. Mandibular defects from tumor resection

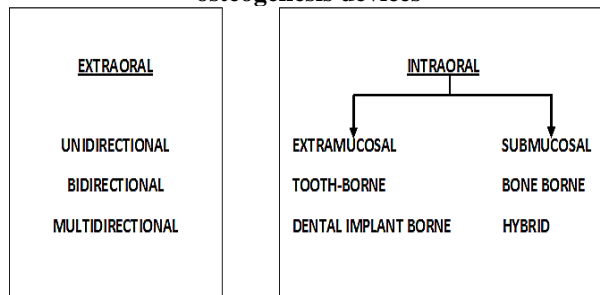
### Advantages of Distraction Osteogenesis<sup>(40,44-49)</sup>

1. Allows greater mandibular lengthening of 10–30 mm
2. Can be applied to unusual bony and soft tissue anatomy
3. Allows slow gradual soft tissue adaptation to extreme mandibular lengthening
4. Minimal to no skeletal relapse after extreme mandibular lengthening
5. Can be applied to neonates, infants, and pediatric patients with obstructive sleep apnea
6. Less invasive surgery compared with bone-grafting procedures
7. Avoids intermaxillary fixation
8. Avoids bone grafting and potential donor-site morbidity
9. Can be used for mandibular widening
10. Fewer adverse temporomandibular joint effects in response to asymmetric lengthening
11. Decreased hospitalization time and cost compared with bone grafting
12. Less need for blood transfusion

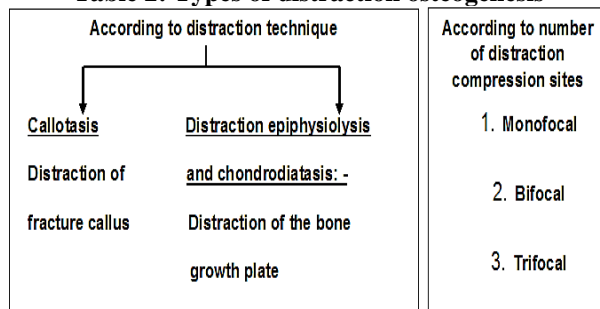
**Drawbacks of Distraction Osteogenesis<sup>(50)</sup>**

1. Skin scars
2. Technique sensitive surgery, equipment sensitive surgery
3. Possible need for second surgery to remove distraction device and patient compliance
4. Transient changes in temporomandibular joint
5. An adequate bone stock is necessary to accept the distraction appliances and to provide suitable opposing surface capable of generating a healing callus
7. Damage to tooth germ
8. Premature consolidation
9. Damage to inferior alveolar nerve
10. Bilateral Coronoid Ankylosis
11. Tendency towards clockwise rotation

**Table 1: Classification of mandibular distraction osteogenesis devices**



**Table 2: Types of distraction osteogenesis**



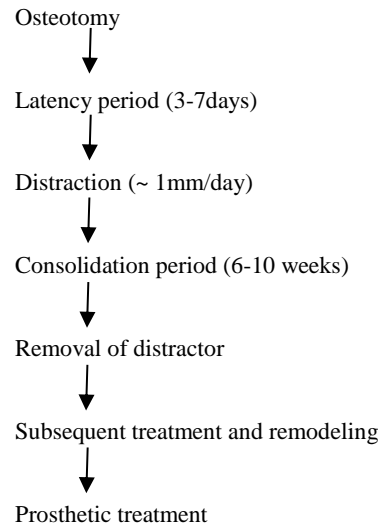
**Distraction Phases**

**Latency Phase:** It is the period between performance of osteotomy and start of distraction during which soft callus is formed. Time period usually ranges from 0 to 7 days and co-inside with initial events in the normal process of bone repair. Approximately 1mm of defect is created by the osteotomy cut in most cases. Histologically, the initial clot is converted into granulation tissue (inflammatory cells and fibroblasts) at 3 days, which becomes increasingly vascular through the emergence of new capillaries. At this stage, recruitment of mesenchymal stem cells from the bone medullar and adjacent periosteum begins.

**Distraction Phase:** The period in which traction is applied to the transport bone fragment and the formation of new woven and parallel- fibered bone

commences. The phase usually last 1-2 weeks and traction modifies the normal development of the regeneration process. Usually the distraction device is activated at the rate of 1 mm and rhythm of 4 (increments of 0.25 mm each) done using axial screw.

**Time Table of Distraction**



If the rate of distraction is too small, there is risk of premature consolidation. Whereas, if the rate of distraction is too great it may place stress on the soft callus, resulting in thinning of all dimensions in the mid portion of the regenerate and an “Hour Glass” at the distraction site. This can be linked to the effect of “Pulling Taffy Apart”.

**Consolidation Phase:** Consolidation phase is the period that allows the maturation and corticalization of the regenerated bone. Typically, this phase is twice as long as the time required for activation. In craniofacial bones, 3-5 weeks phase is recommended for children and 6-12 weeks phase for adults, although the appearance of bone with identical characteristics of those of the initial bone may take more than a year.

Once adequate distraction has been obtained, the device is left in place while the regenerated bone matures and remodels. The distractor must be rigid enough to prevent movement of the bone during the period of healing. If the movement occurs, either from inadequate fixation or premature removal of the appliance, a fibrous non-union may occur.

In the case of large advancements additional stabilization can be obtained from a brief period of maxillo-mandibular fixation during the consolidation phase. Ideally this consolidation phase should be adequate so as to achieve complete mineralization of the bone. The maturity of bone at the end of the consolidation period is perhaps the most critical aspect of the distraction process with regard to stability and potential for relapse.

Histologic specimens from human subjects show that by 60 days the new bone in the distraction area is

likely to still be relatively immature (i.e. woven bone) in contrast to well organized mature bone present at 120 days. In the literature, it has been repeatedly stated that a cortical outline on radiographs indicates maturation of bone adequate to allow removal of distraction device. This occurs in early consolidation process and may not be good indicator especially with large advancements, unless maintaining fixation for 120 days presents a major clinical or psychosocial problem. The acceptability of the distraction device over a long consolidation phase should be considered in planning of the procedure.

After the distraction phase, central fibrous and osteoid areas mineralize in large intramembranous manner which form the remodeling areas for transformation into mature bones. The ossification in the maxillary bone is largely inter membranous, through foci of endochondral ossification have been reported. Such endochondral ossification foci may be due to the instability of the bone segments or from a high distraction rate which interferes with final regeneration. Daily distraction aligns the collagen into parallel bundles that channels the growing vessels and perivascular cells into longitudinal components. Histochemical study reveals that there was increase in levels of pyruvic acid, lactic acid and alkaline phosphate (products of enzymatic metabolism). Hence the moderate and controlled tension exerted by the distractor on the granulation tissue produces a greater differentiation of mesenchymal stem cells into osteoblasts and also favors high production of bone proteins.

The bony fragments to be distracted and the soft callus of the gap must be mobilized during the distraction and consolidation phase. Slight movement in these areas would interrupt the chondroblast, which require less oxygenation in their formation. It is important to enable continuous blood supply by a careful surgical handling of the periosteum.

### **Orthodontic considerations in distraction osteogenesis**

The role of orthodontics in treatment using distraction osteogenesis falls into three temporal phases:

#### **1. Pre-surgical Orthodontic Preparation:**

Commencement of pre-surgical orthodontic preparation of the dentition is started after treatment plan of mandibular distraction has been formulated. For optimal functional and esthetic results, a well contemplated pre-surgical orthodontic treatment is required. The teeth should be positioned ideal to basal bone so that the existing dental malocclusion will not hinder the maxillomandibular skeletal relationship. For example, constricted maxillary arch due to localized malocclusion would interfere with forward movement of mandibular incisors. The

appraisal of maxillomandibular transverse relationships is important because several patients with severe mandibular retrognathia may have a transverse maxillary deficiency.<sup>(51)</sup> It is appropriate to widened the maxilla either before or during distraction to accommodate the width of the advanced mandible.

Another important aspect of pre-distraction orthodontic treatment is the fabrication of distraction stabilization appliance. Distraction appliances are usually inserted before surgery who are undergoing distraction osteogenesis. These appliances maintain mediolateral dental interarch relationship and may be used for those patient who do not require specific tooth movement and have limited compliance. The distraction appliance consist of a banded maxillary expansion appliance and a mandibular lingual arch with symmetrically placed buccal and lingual ball hooks. These ball hooks provide multiple opportunities for the use of interarch elastics to control mandibular position during the distraction, consolidation, and post-consolidation phases.

#### **2. Orthodontic Treatment during Distraction and Consolidation:**

Once the pre-surgical orthodontic preparation is completed, the surgical procedure is performed. This orthodontic/orthopedic treatment may include the use of bands, brackets, distraction stabilization appliances, elastics, headgear, acrylic guidance appliances, maxillary expansion appliances, functional appliances, etc. The use of these appliances improves the quality of the surgical/orthodontic result by directing the tooth-bearing segment toward its planned post-distraction position.

In pre-distraction planning, the orthodontist evaluates and determines the desired vector based on a skeletal appraisal. However, the clinically observed vector often varies from the planned vector. Four influences that are presumed to affect the observed vector are:<sup>(52,53)</sup>

1. The unique biomechanical characteristics of the selected distraction device
2. Orientation of the distraction device to the mandibular anatomy
3. Neuromuscular influence and
4. Externally exerted forces.

#### **A. Orientation of distraction device to the mandibular anatomy**

1. For the vertical elongation of the ramus- vector of the distraction is perpendicular or acute to the patient's occlusal plane
2. For the sagittal advancement- vector of distraction is parallel to the patient's occlusal plane

3. For both ramus and body lengthening-placement of distraction device oblique to the occlusal plane
- B. The unique biomechanical characteristics of the selected distraction device:** Distraction devices with multidirectional capability are able to alter the observed vector as it deviates from the planned vector. Further, they allow for differential vertical, horizontal or transverse vector components to be added as the distraction progresses. These alterations of the vectors are sometimes part of the original preoperative distraction plan or may be introduced during distraction by the orthodontic or surgeon to redirect the tooth bearing segment.
- C. Neuromuscular influence:** Patients undergoing distraction develop functional compensations for their gradually changing occlusion. Often these patients will position their mandible anteriorly or laterally to pick up occlusal contacts that has been lost during distraction to aid them in masticatory function. These functional positional changes represent a recurrent force that is likely to influence the path of the tooth-bearing segment. In addition, the orofacial musculature and soft tissue envelope exert forces on the tooth-bearing segment that may alter the direction in which these segment move. The orthodontist must recognize the presence of these influences and compensate for them with orthodontic and/or orthopedic measures.
- D. Externally exerted forces:** These external forces are applied by the clinician and consist of angular, transverse, or linear activation of the distraction device and orthodontic/orthopedic manipulation of the tooth-bearing segment. Although there may be a possibility of changing the direction that the tooth-bearing segment is moving during distraction, the clinician may also be affecting a change in the proximal segment position. This may create unfavorable positional changes of the condyle/ramus (proximal) segment that must be monitored and controlled.

Interarch elastic traction applied during distraction has been shown to influence the vectors of distraction in the vertical, anteroposterior, and transverse directions. Class II malocclusion, as a result of distraction, may be corrected with Class II interarch elastics. A Class III malocclusion may be corrected with Class III interarch elastics. Class III elastic traction may be further supported by the use of protraction headgear.

3. **Post-consolidation orthodontic/ orthopedic management:** After consolidation, the distraction device is removed and the tooth-bearing segment of the mandible derives its support from the new bone that was formed across the distraction gap. The post-distraction orthodontic needs vary depending on whether the mandibular distraction was unilateral or bilateral. In the growing bilateral

distraction patient, overcorrection of mandible can be a temporary treatment objective in order to compensate for the deficient mandible. Orthognathic surgery may be taken into consideration in growing children which may be required after growth cessation. In non-growing bilateral distraction patient, orthodontic finishing is completed at this time. There is, however a population of patients in whom an orthognathic surgical procedure may be indicated after mandibular distraction. These patients would undergo surgical orthodontic preparation at this time.

In unilateral distraction patients, the post-distraction orthodontic therapy will most likely involve occlusal plane management, correction of the dental midlines, and correction of the maxillomandibular transverse disharmony. Unilateral mandibular distraction usually requires intensive post-distraction orthodontic support. This may include eruption guidance, alignment of the dentition over alveolar bone, correction of laterognathism and controlled vertical closure of the unilateral posterior open bite.

## Conclusion

A new approach to de novo bone formation has been improvised since 19<sup>th</sup> century after extensive studies and experiments on distraction osteogenesis. The basic mechanism for mandibular distraction has been emerged from the concept of distraction of long bones. Bone may be molded three dimensionally to correct the underlying craniofacial deformities and asymmetries, resembling the natural biological phenomena the added advantage of distraction osteogenesis is that there is minimum relapse due to gradual adaptation of soft tissues. This technique offers less risk of infection, reduce hospitalization time and better patient compliance. Further research and developments are required in the area of acceleration of distraction and rapid healing at distraction sites.

## References

1. Wolford LM, Wardrop RW, Hartog JM. Coralline porous hydroxylapatite as a bone graft substitute in orthognathic surgery. *Journal of Oral and Maxillofacial Surgery*. 1987 Dec 1;45(12):1034-42.
2. Trauner R, Obwegeser H. The surgical correction of mandibular prognathism and retrognathia with consideration of genioplasty: Part I. Surgical procedures to correct mandibular prognathism and reshaping of the chin. *Oral surgery, oral medicine, oral pathology*. 1957 Jul 1;10(7):677-89.
3. Schendel SA, Epker BN. Results after mandibular advancement surgery: an analysis of 87 cases. *Journal of oral surgery (American Dental Association)*: 1965). 1980 Apr;38(4):265-82.
4. Converse JM, Horowitz SL. The surgical-orthodontic approach to the treatment of dentofacial deformities. *American journal of orthodontics*. 1969 Mar 1;55(3):217-43.

5. Cassidy DW, Herbosa EG, Rotskoff KS, Johnston LE. A comparison of surgery and orthodontics in "borderline" adults with Class II, division 1 malocclusions. *American Journal of Orthodontics and Dentofacial Orthopedics*. 1993 Nov 30;104(5):455-70.
6. Longaker MT, Siebert JW. Microsurgical correction of facial contour in congenital craniofacial malformations: the marriage of hard and soft tissue. *Plastic and reconstructive surgery*. 1996 Nov 1;98(6):942-50.
7. Vargervik K, Ousterhout DK, Farias M. Factors affecting long-term results in hemifacial microsomia. *Cleft Palate J*. 1986 Dec;23.
8. Yasui N, Kojimoto H, Shimizu H, Shimomura Y. The effect of distraction upon bone, muscle, and periosteum. *The Orthopedic clinics of North America*. 1991 Oct;22(4):563-7.
9. Shevtsov VI, Asonova SN, Yerofeyev SA. Morphological characteristics of angiogenesis in the myofascial tissues of a limb elongated by the Ilizarov method. *Bulletin (Hospital for Joint Diseases (New York, NY))*. 1994 Dec;54(2):76-84.
10. Block MS, Daire J, Stover J, Matthews M. Changes in the inferior alveolar nerve following mandibular lengthening in the dog using distraction osteogenesis. *Journal of oral and maxillofacial surgery*. 1993 Jun 1;51(6):652-60.
11. Schumacher B, Keller J, Hvid I. Distraction effects on muscle: leg lengthening studied in rabbits. *Acta Orthopaedica Scandinavica*. 1994 Jan 1;65(6):647-50.
12. Lee DY, Choi IH, Chung CY, Chung PH, Chi JG, Suh YL. Effect of tibial lengthening on the gastrocnemius muscle: a histopathologic and morphometric study in rabbits. *Acta Orthopaedica Scandinavica*. 1993 Jan 1;64(6):688-92.
13. Fisher E, Staffenberg DA, McCarthy JG, Miller DC, Zeng J. Histopathologic and biochemical changes in the muscles affected by distraction osteogenesis of the mandible. *Plastic and reconstructive surgery*. 1997 Feb 1;99(2):366-71.
14. Shevtsov VI, Asonova SN. Ultrastructural changes of articular cartilage following joint immobilization with the Ilizarov apparatus. *Bulletin (Hospital for Joint Diseases (New York, NY))*. 1994 Dec;54(2):69-75.
15. Nakamura E, Mizuta H, Sei A, Takagi K. Knee articular cartilage injury in leg lengthening: histological studies in rabbits. *Acta Orthopaedica Scandinavica*. 1993 Jan 1;64(4):437-40.
16. Havlik RJ, Bartlett SP. Mandibular distraction lengthening in the severely hypoplastic mandible: a problematic case with tongue aplasia. *Journal of Craniofacial Surgery*. 1994 Nov 1;5(5):305-10.
17. McCarthy JG. The role of distraction osteogenesis in the reconstruction of the mandible in unilateral craniofacial microsomia. *Clinics in plastic surgery*. 1994 Oct;21(4):625-31.
18. Molina F, Monasterio FO. Mandibular elongation and remodeling by distraction: a farewell to major osteotomies. *Plastic and reconstructive surgery*. 1995 Sep 1;96(4):825-40.
19. Habal MB. New bone formation by biological rhythmic distraction. *Journal of craniofacial surgery*. 1994 Nov 1;5(5):344-7.
20. Chin M, Toth BA. Distraction osteogenesis in maxillofacial surgery using internal devices: review of five cases. *Journal of Oral and Maxillofacial Surgery*. 1996 Jan 31;54(1):45-53.
21. Moore MH, Guzman-Stein G, Proudman TW, Abbott AH, Netherway DJ, David DJ. Mandibular lengthening by distraction for airway obstruction in Treacher-Collins syndrome. *Journal of Craniofacial Surgery*. 1994 Feb 1;5(1):22-5.
22. Takato T, Harii K, Hirabayashi S, Komuro Y, Yonehara Y, Susami T. Mandibular lengthening by gradual distraction: analysis using accurate skull replicas. *British journal of plastic surgery*. 1993 Dec 1;46(8):686-93.
23. Pensler JM, Goldberg DP, Lindell B, Carroll NC. Skeletal distraction of the hypoplastic mandible. *Annals of plastic surgery*. 1995 Feb 1;34(2):130-7.
24. Klein C, Howaldt HP. Lengthening of the hypoplastic mandible by gradual distraction in childhood—a preliminary report. *Journal of Cranio-Maxillofacial Surgery*. 1995 Apr 1;23(2):68-74.
25. Perrott DH, Berger R, Vargervik K, Kaban LB. Use of a skeletal distraction device to widen the mandible: a case report. *Journal of oral and maxillofacial surgery*. 1993 Apr 1;51(4):435-9.
26. McCarthy JG, Schreiber J, Karp N, Thorne CH, Grayson BH. Lengthening the human mandible by gradual distraction. *Plastic and reconstructive surgery*. 1992 Jan 1;89(1):1-8.
27. Guerrero C, Bell W, Flores A, Modugno V, Contasti G, Rodríguez AM, Meza L. Distracción osteogénica mandibular intraoral. *Odontol. dia*. 1995 Aug;11(2):116-32.
28. Klein C, Howaldt HP. Correction of mandibular hypoplasia by means of bidirectional callus distraction. *Journal of Craniofacial Surgery*. 1996 Jul 1;7(4):258-66.
29. Guyette TW, Polley JW, Figueroa AA, Cohen MN. Mandibular distraction osteogenesis: effects on articulation and velopharyngeal function. *Journal of Craniofacial Surgery*. 1996 May 1;7(3):186-90.
30. Kocabalkan O, Leblebicioğlu G, Erk Y, Enacar A. Repeated mandibular lengthening in Treacher Collins syndrome: a case report. *International journal of oral and maxillofacial surgery*. 1995 Dec 1;24(6):406-8.
31. Corcoran J, Hubli EH, Salyer KE. Distraction osteogenesis of costochondral neomandibles: a clinical experience. *Plastic and reconstructive surgery*. 1997 Aug 1;100(2):311-5.
32. Polley JW, Figueroa AA. Distraction osteogenesis: its application in severe mandibular deformities in hemifacial microsomia. *Journal of Craniofacial Surgery*. 1997 Sep 1;8(5):422-30.
33. Guerrero C. Expansion mandibular quirurgica. *Rev. venez. ortod*. 1990;7(1/2):48-50.
34. Codivilla A. On the means of lengthening, in the lower limbs, the muscles and tissues which are shortened through deformity. *JBJS*. 1905 Apr 1;2(4):353-69.
35. Ilizarov GA. The tension-stress effect on the genesis and growth of tissues: Part I. The influence of stability of fixation and soft-tissue preservation. *Clinical orthopaedics and related research*. 1989 Jan 1;238:249-81.
36. Ilizarov GA. The tension-stress effect on the genesis and growth of tissues: Part II. The influence of the rate and frequency of distraction. *Clinical orthopaedics and related research*. 1989 Feb 1;239:263-85.
37. Wassmund M. *Lehrbuch der Praktischen Chirurgie des Mundes und der Kiefer*. Band 1. Leipzig: Hermann Meusser 1935;275.
38. Kazanjian VH. The Interrelation of Dentistry and Surgery in the Treatment of Deformities of the Face and Jaws. *American Journal of Orthodontics and Oral Surgery*. 1941 Jan 1;27(1):C10-30.
39. Crawford MJ. Selection of appliances for typical facial fractures. *Oral Surgery, Oral Medicine, Oral Pathology*. 1948 May 1;1(5):442-51.

40. Karp NS, Thorne CH, McCarthy JG, Sissons HA. Bone lengthening in the craniofacial skeleton. *Annals of plastic surgery*. 1990 Mar 1;24(3):231-7.
41. Huang CS, Ross RB. Surgical advancement of the retrognathic mandible in growing children. *American journal of orthodontics*. 1982 Aug 1;82(2):89-103.
42. Dolce C, Van Sickels JE, Bays RA, Rugh JD. Skeletal stability after mandibular advancement with rigid versus wire fixation. *Journal of oral and maxillofacial surgery*. 2000 Nov 30;58(11):1219-27.
43. Cascone P, Agrillo A, Spuntarelli G, Arangio P, Iannetti G. Combined surgical therapy of temporomandibular joint ankylosis and secondary deformity using intraoral distraction. *Journal of Craniofacial Surgery*. 2002 May 1;13(3):401-9.
44. Cope JB, Samchukov ML, Cherkashin AM. Mandibular distraction osteogenesis: a historic perspective and future directions. *American journal of orthodontics and dentofacial orthopedics*. 1999 Apr 30;115(4):448-60.
45. Castaño FJ, Troulis MJ, Glowacki J, Kaban LB, Yates KE. Proliferation of masseter myocytes after distraction osteogenesis of the porcine mandible. *Journal of oral and maxillofacial surgery*. 2001 Mar 31;59(3):302-7.
46. Cutbirth M, Van Sickels JE, Thrash WJ. Condylar resorption after bicortical screw fixation of mandibular advancement. *Journal of oral and maxillofacial surgery*. 1998 Feb 28;56(2):178-82.
47. Mercuri LG. Alloplastic temporomandibular joint reconstruction. *Oral Surgery, Oral Medicine, Oral Pathology, Oral Radiology, and Endodontology*. 1998 Jun 1;85(6):631-7.
48. Riley RW, Powell NB, Guilleminault C. Obstructive sleep apnea syndrome: a review of 306 consecutively treated surgical patients. *Otolaryngology--Head and Neck Surgery*. 1993 Feb 1;108(2):117-25.
49. Waite PD, Wooten V, Lachner J, Guyette RF. Maxillomandibular advancement surgery in 23 patients with obstructive sleep apnea syndrome. *Journal of oral and maxillofacial surgery*. 1989 Dec 1;47(12):1256-61.
50. Van Strijen PJ, Breuning KH, Becking AG, Perdijk FB, Tuinzing DB. Cost, operation and hospitalization times in distraction osteogenesis versus sagittal split osteotomy. *Journal of Cranio-Maxillofacial Surgery*. 2003 Feb 28;31(1):42-5.
51. Hanson PR, Melugin MB. Orthodontic management of the patient undergoing mandibular distraction osteogenesis. In *Seminars in orthodontics* 1999 Mar 1 (Vol. 5, No. 1, pp. 25-34). WB Saunders.
52. Grayson BH, McCormick S, Santiago PE, McCarthy JG. Vector of device placement and trajectory of mandibular distraction. *Journal of Craniofacial Surgery*. 1997 Nov 1;8(6):473-80.
53. Losken HW, Patterson GT, Tate D, Coit DW. Geometric evaluation of mandibular distraction. *Journal of Craniofacial Surgery*. 1995 Sep 1;6(5):395-400.