

Therapeutic extraction for management of palatally impacted maxillary canine- A case report

Anadha N. Gujar^{1,*}, Kiran Kumar N.², MS Rani³

¹Assistant Professor, KLES Institute of Dental Sciences, Bangalore, ³Professor, Dept. of Orthodontics, VS Dental College, Bangalore, ²Associate Professor, Dept. of Conservative Dentistry & Endodontics, Govt. Dental College, Bangalore

***Corresponding Author:**

Email: anadha@gmail.com

Abstract

Palatal impaction of maxillary canine is the most common amongst the canine impactions with several treatment options proposed for it. Therapeutic extractions are most of the times controversial. This case report describes the diagnosis and treatment of palatally impacted maxillary canine by surgical exposure and orthodontic positioning of it.

Keyword: Closed flap technique; Impaction; Lateral incisor extraction; Maxillary canine, Surgical exposure.

Introduction

Impaction refers to failure of a tooth to emerge into the dental arch. The etiology of impaction is multifactorial. Some of the causes are: genetic predisposition, developmental anomalies, syndromes, inadequate arch space.⁽¹⁾ Maxillary canines have the longest period of development, the deepest area of development, and the most difficult path of all the teeth.^(2,3) Canine impaction is more prevalent in the maxilla than in the mandible.⁽⁴⁾

Palatal displacement of the maxillary canines is defined as the developmental dislocation to a palatal site often resulting in tooth impaction requiring surgical and orthodontics treatment.⁽⁵⁻⁷⁾

Few authors studied the factors affecting the management of impacted maxillary permanent canines and they stated that, the decision to expose or remove an impacted maxillary permanent canine seemed to be guided by the labiopalatal crown position and angulation to the midline.⁽⁸⁾

Some authors believed that asymptomatic impacted teeth could be left in place, but in these patients a series of successive radiographs should be taken periodically.⁽⁹⁾

The purpose of this paper was to describe the diagnosis and treatment of palatally impacted maxillary canine by surgical exposure and orthodontic positioning of it.

Diagnosis and etiology: A 15 year 6 months old girl reported with a chief complaint of missing upper front tooth and wanted to get the treatment done for the same. She was physically healthy and had no history of medical or dental trauma. No signs or symptoms of Temporomandibular joint dysfunction were noted at the initial examination.

The extraoral clinical examination (Fig. 1) showed a slight concave profile with average nasolabial angle. There were no gross asymmetries. The intraoral examination (Fig. 1 and 2) showed an Angle's Class II div 1 subdivision malocclusion and Class I incisor

relationship with retained upper right deciduous canine. The maxillary right permanent canine was impacted. The maxillary arch showed space shortage of 8mm and the mandibular arch showed moderate crowding of 8 mm. There was increased overbite of 4mm and overjet of 2mm.

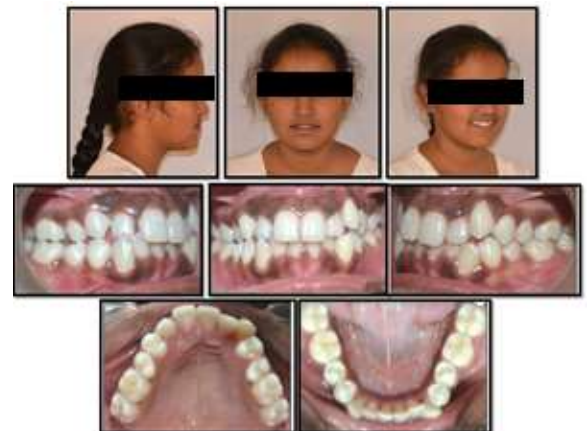

Fig. 1

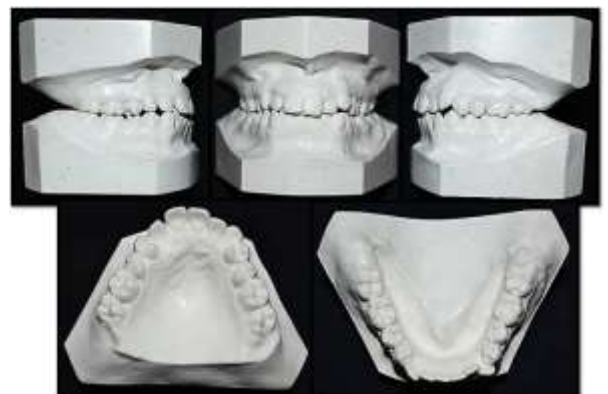

Fig. 2

Cephalometrically (Fig. 3), the patient had a Class III skeletal relationship (ANB angle: -3°) with both maxillary and mandibular retrognathism (SNA: 71° ,

SNB: 74°). A vertical growth pattern was seen (SN.GoGn: 38°). Maxillary incisors were proclined with the upper incisor at 10mm and 29° to NA. The lower incisors were retroclined with an IMPA of 86° and the lower incisor at 23° and 3mm to NB, resulting in a reduced interincisal angle (Table 1). The panoramic radiograph showed all permanent teeth with a retained deciduous upper right deciduous canine, including the maxillary and mandibular unerupted third molars. The maxillary right canine was impacted (Fig. 3). The palatal position of the impacted maxillary canine was confirmed with the help of maxillary occlusal radiograph.

Table 1: Pre and post treatment cephalometric status

Measurement	Norm	Pre-treatment	Post treatment
Maxillary components			
SNA(°)	82	71	73
A-Nperp (mm)	2	-9	-7
Mandibular components			
SNB (°)	80	74	75
Maxillomandibular relationship			
ANB (°)	2	-3	-2
Convexity (NAP) (°)	0	-8	-6
Facial growth pattern			
SN.GoGn (°)	32	38	39
Maxillary dentoalveolar components			
MxI.NA (°)	22	29	29
MxI-NA (mm)	4	10	7
Mandibular dentoalveolar components			
MdI.NB (°)	25	23	25
MdI-NB (mm)	4	3	4
IMPA (°)	90	86	88
Overjet (mm)	2.08	2	2
Overbite (mm)	2.87	4	2
Soft tissue components			
Nasolabial angle (°)	110	95	95
Upper I exposure(mm)	2	4	2
Upper lip to E (mm)	-3±1	-6	-5
Lower lip to E (mm)	-2±1	0	-2

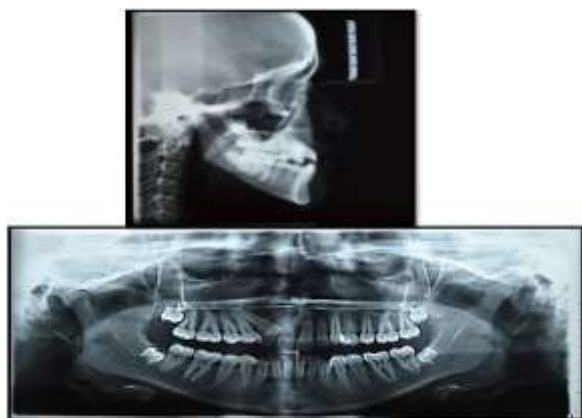
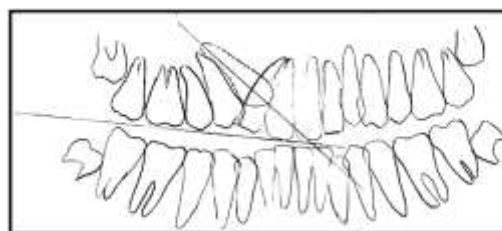


Fig. 3

Bayesian network analysis⁽¹⁰⁾(Fig. 4 and Table 2) on the Orthopantomogram tracing was done to evaluate the possible relationships among the variables considered for diagnosis and treatment of impacted left mandibular canine. The favorability of the impacted canine to erupt into the arch was analysed and it was found to be good.

Table 2: Bayesian network analysis

Parameters	Normal	Pretreatment
Alpha Angle	≤35°±15°	36°
Distance	≤15±4mm	12mm
Sector	1 or 2	2



Mean Values:

{a} Alpha angle: ≤35±3

{d} Distance: 15±4

{s} sector: 1 or 2

Beyond the range: Unfavourable Impaction

Fig. 4

Treatment objectives: The initial treatment objective was to disimpact the maxillary right canine and bring it into alignment. The orthodontic procedure would align the maxillary and mandibular dental arches. Our treatment objective also included maintaining Class III skeletal relationship, bringing the end on molar relationship on right side into full cusp Class II molar relationship and maintaining the Class I molar relationship on the left side with, achieving Class I canine relationship with a pleasing profile and to improve the smile arc.

Treatment alternatives: Three alternatives were presented to the patient.

1. Extraction of maxillary and mandibular first premolars. The two main advantages of this treatment option were the efficiency to bring the impacted maxillary right permanent canine into alignment in the arch with space created by extraction of premolars. Nevertheless, mandibular first premolars extraction treatment would not resolve the arch length discrepancy but would end up in excess space. It also would not achieve ideal incisal relationship and might even worsen the profile, resulting in excess of overjet.
2. Extraction of the mandibular left lateral incisor. This would address the arch length discrepancy in lower arch. The non-extraction treatment plan of maxillary arch, would help in good arch alignment

by gaining space for it through arch widening. However, the facial and smile esthetics would not be optimized.

3. Extraction of maxillary right first premolar and mandibular left lateral incisor. This would create sufficient space to bring the impacted maxillary right canine into alignment and occlusion. The arch-length deficiency in mandibular arch would be resolved. This would enhance both the profile and the smile esthetics by achieving ideal incisal and canine relationship.

The third treatment option was adopted because it would optimize facial and smile esthetics. Co-operation and stability issues were discussed with the patient.

Treatment progress: Both the esthetic concerns and the patient's desires called for a challenging solution for an unusual impacted maxillary canine treatment to align into its ideal position in the arch. The preoperative orthodontic preparation was performed with conventional 0.022-in MBT appliances. The initial alignment and leveling was achieved with 0.016" NiTi archwires. The impacted maxillary right canine was surgically exposed and bonded during the 0.018' AJ Wilcock archwire stage. The impacted maxillary canine was exposed with closed flap surgical approach palatally.⁽¹⁰⁾ The maxillary right retained deciduous canine and first premolar of the same side were extracted immediately after bonding the Begg bracket on the palatal surface of the exposed tooth (Fig. 5). The ligature wire was tied from the bonded attachment on the canine. Surgical exposure was carried out under local anesthesia. The alignment and leveling was completed with .019 X 0.025-in NiTi and 0.019 X 0.025-in stainless steel rectangular archwires. Elastic traction was given from the ligature wire attached to the Begg bracket on the exposed crown of the impacted maxillary right canine to the 0.019 X 0.025 stainless steel maxillary arch wire. In order to bring the maxillary right canine in the arch, a overlay ("Piggy Back") wire of 0.014 NiTi, over the 0.019 X 0.025 stainless steel mandibular arch wire was engaged on the Begg bracket of the maxillary right canine. The overlay wire extended from second premolar on right side to the second premolar on the left. As the maxillary right canine started erupting, MBT 0.022 maxillary right canine bracket was bonded on the labial surface of the tooth and couple force was given in order to de-rotate the tooth (Fig. 6). After the maxillary right canine was brought into the arch, the Begg bracket on its palatal surface was debonded. Settling was done with 0.014" Stainless steel archwire. This entire orthodontic procedure took 18 months.

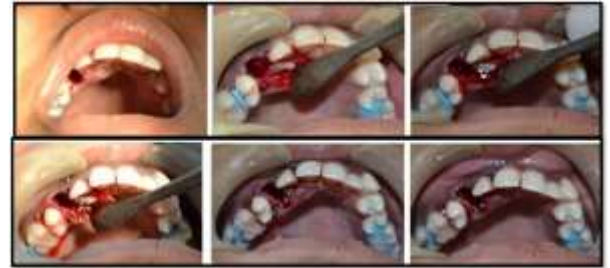

Fig. 5

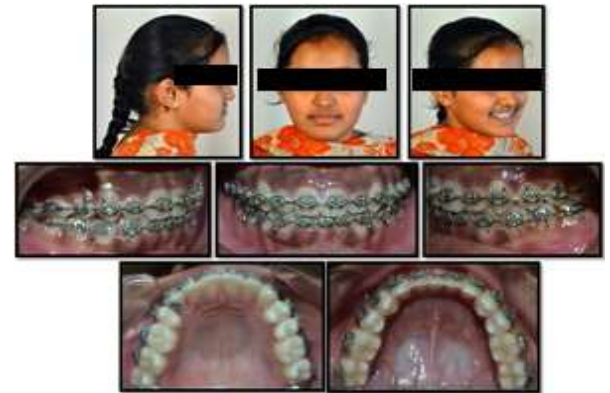

Fig. 6

Treatment results: The facial esthetic was improved with better lip support, maintaining the average nasolabial angle (Fig. 7). The smile was enhanced and the consonant smile arc was achieved. Intraorally, ideal overjet and overbite was achieved with Class I canine relationship. The end-on molar relationship on the right side was brought into full cusp Class II molar relationship while the Class I molar relationship on the left side was maintained.

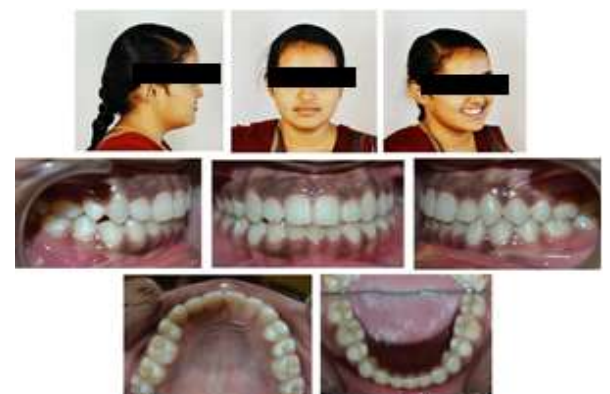

Fig. 7

The post treatment panoramic radiograph (Fig. 8) showed good overall root parallelism and lack of root resorption. Post treatment lateral Cephalogram (Fig. 8) showed satisfactory improvement in ANB angle by 1°. The position of lower incisors were improved, with lower incisor at 25° and 4mm to NB. The arch length discrepancies in both upper and lower arches were

resolved. A favorable profile change in facial profile contour angle was seen.

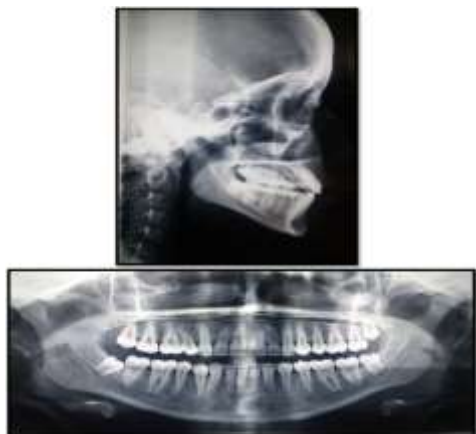

Fig. 8

Discussion

Canines are important in establishing and maintaining the dentition's form, function and esthetics. The maxillary canine is one of the most frequently impacted teeth with an incidence of 2% with palatal impaction being most commonly seen in 85% of ectopically positioned maxillary canines.⁽¹¹⁻¹³⁾ Diagnosis and localization is the most important step in the management of impacted teeth.⁽⁹⁾

Surgical exposure of the impacted maxillary canine and the use of fixed orthodontic appliances is the most frequently used treatment alternative as long as the tooth position is favorable. Various methods have been used for moving the canine into proper alignment.⁽¹⁴⁻¹⁶⁾ The procedures used for surgical exposure and traction are important in any impaction case.^(14,17,18)

Guiding the tooth into occlusion requires a team approach. Surgical exposure of the impacted tooth involves placing a full thickness mucoperiosteal incision and exposing the tooth under local anaesthesia. This may be carried out via an open or an alternative approach known as closed method. The main advantage of closed eruption method was it provided better periodontal health compared to canines managed with open method, with less recovery period with this closed technique.⁽¹⁹⁾

Class II Subdivisions are difficult to treat, owing to an asymmetric occlusal relationship.⁽²⁰⁾ Owing to the complexities, regarding the cause, the treatment planning may vary in clinician's hands. In our case, we took the decision to extract the maxillary right first premolar so as to gain sufficient space for alignment of impacted maxillary canine as well to achieve full cusp class II molar relationship by protracting maxillary right first molar.

Therapeutic extraction has been one of the major controversies in orthodontics.⁽²¹⁾ The teeth most commonly extracted for orthodontic treatment (therapeutic extraction) are either first premolar or

second premolar. In case of borderline space discrepancy, extraction of premolar might create more than required amount of space. In such cases of borderline space discrepancy in mandibular arch, a better alternative is to follow an atypical therapeutic extraction viz extracting one or two mandibular incisors.⁽²²⁾ The concept of removing the lower incisor for the purpose of relieving the crowding was introduced by Hahn.^(23,24) The critical decision of which incisor to extract depends on several considerations, mainly periodontal conditions, mesio-distal width of each tooth etc. It is especially suitable for patients with mild skeletal Class III malocclusion.^(22,25)

All the advantages and disadvantages of surgical and orthodontic repositioning as well as the risks (including that of being unable to achieve the desired goals) and the need for good cooperation were discussed, and these were understood and accepted by the patient.

Conclusion

A pleasing external soft tissue profile was achieved. The combined effect of surgical exposure of impacted maxillary canine and orthodontically correcting its position was instrumental in reestablishing the major components of a balanced smile for this patient, whose main concern was her unpleasant smile.

References

1. Yati Kirti, Vivek Misra, Poonam K, Akram Ansari. Impacted canine – an orthodontic approach. *TMU J. Dent* 2014;1(2):72-73.
2. Jacoby H. The etiology of maxillary canine impaction. *Am J Orthod* 1983;84:125-132.
3. Chien-Lun Peng; Yu-Yu Su; Sheng-Yang Lee. Unilateral Horizontally Impacted Maxillary Canine and First Premolar Treated with a Double Archwire Technique. *Angle Orthodontist* 2016;76(3):502-509.
4. Nezar Watted, Emad Hussein, Obaida Awadi, and Muhamad Abu-Hussein. Transmigration of Impacted Canines: A Report of Two Cases and a Review of the Literature. Research and reviews: journal of dental sciences 2014;2(4):23-32.
5. Ali Alqerban, Reinhilde Jacobs, Steffen Fieuws, Guy Willems. Comparison of two cone beam computed tomographic systems versus panoramic imaging for localization of impacted maxillary canines and detection of root resorption. *Eur J Orthod* 2011;33:93-102.
6. Peck S, Peck L, Kataja M. Site-specificity of tooth maxillary agenesis in subjects with canine malpositions. *Angle Orthod.* 1996;66:473-6.
7. Rajiv Yadav, Basanta K. Shrestha. Maxillary Impacted Canines: A Clinical Review. *Orthodontic Journal of Nepal*, Vol. 3, No. 1, June 2013.
8. Stivaros N, Mandall NA. Radiographic factors affecting the management of impacted upper permanent canines. *J Orthod.* 2000;27:169-173.
9. Monika R, Mahesh G, Nikhi M. Bilateral Mandibular Canine Impaction: A Rare Case Report. *Journal of Oral Health and Community dentistry.* 2009;3(2):38-41.
10. Michele N, Aldo C, Roberto R, Tiziano B, Pierpaola C, Giovan PP. Factors affecting the clinical approach to

- impacted maxillary canines: A Bayesian network analysis. *Am J Orthod Dentofacial Orthop.* 2010;137(6):755–762.
11. Thilander B, Jakobsson SO. Local factors in impaction of maxillary canines. *Acta Odontol Scand.* 1968;26:145–168.
 12. Ericson S, Kurol J. Longitudinal study and analysis of clinical supervision of maxillary canine eruption. *Community Dent Oral Epidemiol.* 1986;14:112–116.
 13. Egle Zasciurinskiene; Krister Bjerklin; Dalia Smailiene; Antanas Sidlauskas; Algirdas Puisys. Initial Vertical and Horizontal Position of Palatally Impacted Maxillary Canine and Effect on Periodontal Status Following Surgical-Orthodontic Treatment. *Angle Orthodontist* 2008;78(2):275-280.
 14. Bishara SE. Impacted maxillary canines: a review *Am J Orthod Dentofacial Orthop.* 1992;101:159-171.
 15. Levin MP, D'Amico RA. Flap design in exposing unerupted teeth. *Am J Orthod.* 1974;65:419-422.
 16. Crescini A, Clauser C, Giorgetti R, Cortellini P, Pini Prato GP. Tunnel traction of infraosseous impacted maxillary canines. A three-year periodontal follow-up. *Am J Orthod Dentofacial Orthop.* 1994;105:61-72.
 17. Ngan P, Hornbrook R.; and Weaver, B.: Early timely management of ectopically erupting maxillary canines, *Semin. Orthod.* 11:152-163,2005.
 18. Antonio Gracco, Ivano Maltoni, Manuela Maltoni, Lucia Zoli. *J Clin Orthod* 2012;46(10):625-630.
 19. S. M. Iondhe, Prasanna Kumar, Sanjeev Datana, Atul Kotwal, Vivek Saxena. Guided tooth eruption: Comparison of open and closed eruption techniques in labially impacted maxillary canines. *Journal of Dental Research and Review* 2014;1(3):148-151.
 20. Azevedo ARP, Janson GRP, Henriques JFC, Frietas MR. Evaluation of asymmetries between subjects with Class II subdivision and apparent facial asymmetry and those with normal occlusion. *Am J Orthod dentofacial Orthop* 2006; 129: 376-383.
 21. John C Bennet, Richard P. First bicuspid in orthodontic management of the dentition with the preadjusted appliance. Isis Medical Media Ltd, Oxford, UK 1997, p. 195.
 22. Raju DS, Veereshi AS, Naidu DL, Raju BHVR, Goel M, Maheshwari A. Therapeutic Extraction of Lower Incisor for Orthodontic Treatment. *J Contemp Dent Pract* 2012;13(4):574-577.
 23. Canut JA. Mandibular incisor extraction: Indications and long term evaluation. *Eur J Orthod* 1996;18:485-9.
 24. Vignesh T, Senthil Kumar K. P, Senthil Kumar T. Mandibular incisor extraction in orthodontics: A systematic review. *Journal of Indian Academy of Dental Specialist Researchers.* 2014;1(1); 1-5.
 25. Miller RJ, Duong TT, Derakhshan M. Lower incisor extraction treatment with the Invisalign system. *J Clin Orthod* 2002;36:95-102.