

Comparative evaluation of hard and soft tissue mid-face dimensions of Class I and Class III Individuals using CBCT

Raghu Devanna^{1,*}, Yousef Althomali², Nayef H. Felemban³, Bheema S. Manasali⁴, Prashant M. Battepati⁵

^{1,2}Associate Professor, ³Assistant Professor, Orthodontic Division, Dept. of Preventive, ⁴Assistant Professor, Dept. of Prosthodontics, ⁵Assistant Professor, Pediatric Dentistry, Dept. of Preventive, Faculty of Dentistry, Taif University, Taif, KSA

***Corresponding Author:**

Email: drraghu@tudent.edu.sa

Abstract

Introduction: Augmenting the malar area enhances the angularity and fullness of the mid face. Pop culture portrays people with high malar prominence and angular faces as beautiful and exotic.⁽¹⁾ On the other hand, people with mid face deficiency tend to have a gaunt or hollow mid face leading to increased show of the sclera inferior to the pupil.

Materials and Method: Thirty Class I and 30 Class III CBCT images (16 male, 14 female - each group) between the age group of 14-20 years were included in the study. Data collected from the patients reporting to the Insight CBCT Center, Pune. The CBCT images were analyzed with creation of hard and soft tissue slices for PPA and results were drawn with statistical analysis.

Results: The Class I male horizontal slices had smaller measurements ($P < .05$) in both the soft and hard tissue than Class III by 0.4 to 1.5 mm at nearly nine measurements of PPA. The Class III sample pattern profile measurements were larger by 0.6 to 1.7 mm. The laterality measurements also found to be larger for the Class III as compared to Class I.

Discussion & Conclusion: Class III males found to have a larger mid face deficiency than Class I male. Anterior component of the Class III male's mid face showed posterior positioning. Class I and Class III female sample showed similar size and position of the mid facial complex (Statistically Insignificant). Class III male's mid facial deficiency was more, mid face complex positioned further laterally and elongated more anteriorly as compared to the Class I male and female Class III.

Keywords: Malar Area, Mid Face Deficiency, Class I, Class III

Introduction

Malar augmentation is a common procedure among plastic surgeons and otolaryngologists.⁽¹⁾ Oral surgeons use different designs of Le Fort I, II, and III surgical procedures to help increase malar projection during orthognathic surgery.^(2,4) Increasing the malar area enhances the angularity and fullness of the mid face. Pop culture portrays people with high malar prominence and angular faces as beautiful and exotic.⁽¹⁾ On the other hand, people with mid face deficiency tend to have a gaunt or hollow mid face leading to increased show of the sclera inferior to the pupil.^(5,6) The hollow mid face creates a perpetually tired, worn out, older and sad appearance.^(1,7) Aging augments the hollowness as soft tissue atrophy and sagging reduce malar soft tissue prominence and move it more inferior.⁽⁸⁾

To achieve facial beauty there must be balance among the facial promontories.⁽⁹⁾ The nose, lips, chin, glabella, and malar prominence related to each other and they create a positive perspective within the face.⁽¹⁰⁾ Any single promontory out of proportion with the rest makes the other promontories more or less protrusive. A large nose decreases the apparent size of the chin and malar prominences. Flat malar areas make the nose large and unseemly. Likewise, a large nose masked by augmenting the malar prominences and chin.⁽¹¹⁾

Orthodontists are concerned with establishing facial beauty and balance. In particular, they diagnose and treat according to the facial profile and the effects that treatment will have on the facial profile.^(12,13) The lips move in proportion to the amount of tooth

movement and lip fullness can be increased or decreased with orthodontic treatment.^(14,15) Additionally, the relationship of the maxilla and mandible and their relationship to the profile of the patient given utmost consideration.⁽¹⁶⁾ In patients with retrognathic mandibles, treatment plans are created to advance the mandible or reduce the prominence of the maxilla to mask the mandibular retrusion.⁽¹⁷⁾ Mandibular advancement decreases the perception of mid face fullness or increases the hollowness of a patient already deficient. Mandibular setback would increase the perception of the malar fullness.

In three dimensions, the malar prominence becomes more important. The prominence creates width to the anterior face and cheek fullness. The orthodontic treatments affecting the mandible and lips also affect the perception of the nose and malar prominence.⁽¹⁸⁾ Skeletally Class III individuals have maxillae that are by definition behind the mandible and thus should appear to have increased incidence of malar deficiency.

Misdiagnosis of facial asymmetry can result in inaccurate orthodontic treatment plans. Precise evaluation of facial asymmetry is a key step in orthodontic diagnosis.⁽¹⁹⁾ Consequently, in recent years, the use of CBCT for evaluation of facial asymmetry has become more common. CBCT not only overcomes the disadvantages of 2D radiographs without exposing the patient to high levels of radiation and great expense^(20,21) but also improves the ability to understand the 3D nature of facial asymmetry, enabling the

simultaneous evaluation of both hard and soft tissues, and enhances treatment outcomes.^(22,23) Recent studies have recommended the use of CBCT for diagnosing facial asymmetry and classified 3D imaging as the best method for understanding a patient's morphology.⁽²⁴⁾ The introduction of three-dimensional imaging techniques injected new vitality into the study of facial dimensions. Facial dimensions could now be measured as they actually are and not as projections of three-dimensional objects on to two-dimensional surfaces. The limit is no longer photographs, videos and two-dimensional x-rays. Initially, the use of linear measurements and angles previously used in two-dimensional studies was applied to the three-dimensional images.⁽²⁵⁾ However, treatment outcomes now possible to analyze volumetrically and compare to determine changes in volume ratios brought about by various treatment techniques. Further, hard and soft tissue surface characteristics and changes could be mapped and portrayed via isolines and color maps.^(22,26) Current methods of three-dimensional analysis include magnetic resonance imaging, three-dimensional cephalometry, conventional computed tomography, optical three-dimension surface imaging and cone-beam computed tomography. Optical three-dimensional surface imaging and cone-beam computed tomography are those most utilized in the orthodontic research.^(24,27)

The purpose of this CBCT study is to evaluate and compare the mid face dimensions of untreated class I and class III individuals using CBCT.

Materials and Method

Thirty Class I and 30 Class III CBCT images (16 male, 14 female - each group) between the age group of 14-20 years were taken for the study. Data collected from the patients reporting to the Insight CBCT Center, Pune. Informed consent obtained from all the participants. The teeth placed in maximum intercuspation and the head in natural head posture. The resolution was 1024 x 1024 and 12 bits per pixel equaling 4096 scales of gray. Scans taken in the F mode with a twelve-inch field of view, two mA and 120kV. Horizontal slices taken of the mid face area from each CBCT. A pattern profile analysis completed on each slice of both the hard and soft tissue mid face dimensions. Measurements made relating the analysis to the patient's midline (Y-axis) and cranial base (X-axis). The initial search completed in Dolphin Imaging version 11.0 using the cephalometric data search function. The initial search criteria used included patients from 14 to 20 years old and the ANB angle to determine Class I or Class III status. ANB angles of less than 0 degrees considered Class III and ANB angles of 0.1 to 3.1 degrees considered Class I. The samples segregated into male and female and visually inspected for race. Patients with multiple missing teeth, no initial photos, clefts or apparent syndromes excluded. The remaining Class I sample was larger than

the Class III sample and so matched to the Class III sample by the number of each sex. The sample was subsequently de-identified.

Creation of Slices: In the Dolphin Imaging Software version 11.0, each cone-beam was oriented with the transporonal axis and Frankfort horizontal parallel to the floor with the right infraorbital rim as the anterior reference. Using the Build X-rays Tool, a submentovertex horizontal slice generated at the level of both porion and the right infraorbital rim. The slice thickness varied from 2 to 4 mm in order to include all structures needed within the slice. It was necessary to make this slice 4 to 6 mm thick in order to visualize all structures. All slices then moved into the Corel DESIGNER X4, version 14.1 for further analysis. (Fig. 1 & 2).

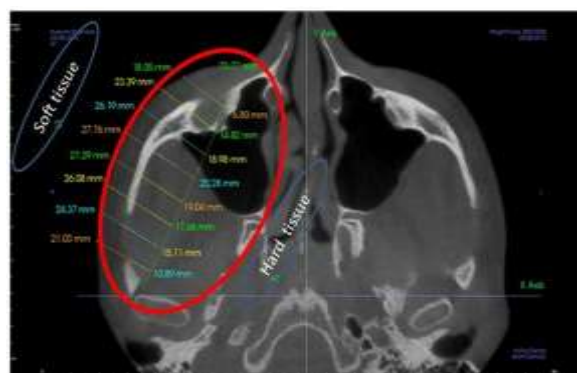


Fig. 1: Corel Designer X4, Version 14.1, A Submentovertex horizontal slice

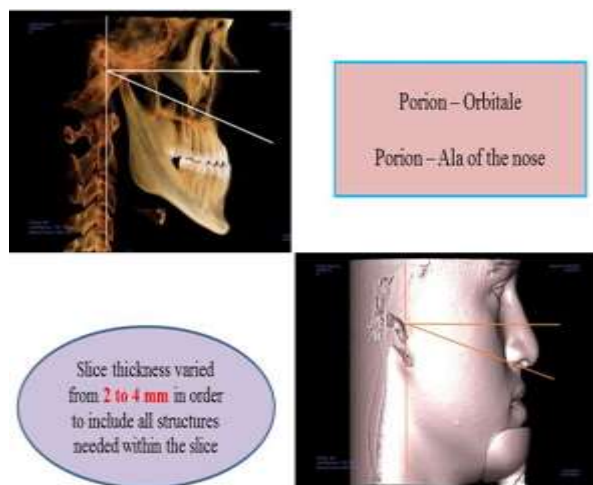


Fig. 2: Horizontal & Oblique slices – Mid face area from each CBCT

Pattern Profile Analysis and Image Measurement: A pattern profile analysis was completed for each slice on the right malar hard tissue similar to Roberts,^(22,26) but with modifications (Fig. 3). The anterior point of the pattern profile analysis was the junction of the anterior projection of the maxilla along the lateral wall of the nose with the anterior border of the maxilla inferior to

the orbital rim. As a further reference in locating the point, these two walls create a triangle of bone with the lateral wall of the nasal cavity when viewed in cross section. The center of the base of the triangle of bone used as the anterior point.

The posterior point defined using the posterior border of the internal arc of the zygomatic arc anterior to the articular tubercle as a reference. A line (Called the "X-Axis") parallel to the transcoronal axis was drawn from the depth of the arc laterally to the lateral border of the zygomatic arch (Fig. 1).⁽²¹⁾

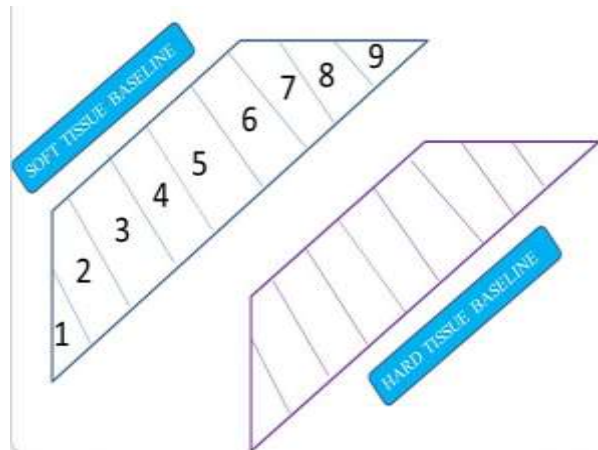


Fig. 3: Pattern Profile Analysis

The anterior and posterior points connected with a line (Called the "Baseline") and divided into 10 segments. At the junction of each segment, a perpendicular measurement (Called the "Pattern Profile Analysis Measurement") taken from the baseline to the border of the malar hard tissue. Pattern profile analysis measurements were labeled 1 through 9 from posterior to anterior.

To create the pattern profile analysis for the soft tissue the hard tissue landmarks used as reference (Fig. 3). The anterior point transposed anteriorly along a line 45 degrees to the transporonal axis until the soft tissue border was met. The posterior point was determined from the X-axis line. The posterior point transposed along this line onto the border of the soft tissue. All measurements then calculated using the same procedure as previously outlined.

Finally, a Cartesian coordinate system was created using the X-axis and a line dividing the face in half based on of an average of the cranial base structures and the width of the piriform aperture. Using the Cartesian coordinate system, cranial measurements made relating the pattern profile analysis to other cranial structures. The X and Y distances measured for the anterior point. The X distance measured for the posterior point. Finally, the posterior most intersection of the cranial base and the Y-axis measured. The absolute value of each distance recorded for comparison.

Statistical analysis: The data coded and entered into Microsoft Excel spreadsheet. Analysis completed using SPSS version 15 (SPSS Inc. Chicago, IL, USA) Windows software program. The variables assessed for normality using the Kolmogorov-Smirnov test. Descriptive statistics were calculated. Means of both groups compared by independent student t-test. Level of significance was set at p=0.05.

Results

Thirty Class I and 30 Class III CBCT images (16 male, 14 female - each group) between the age group of 14-20 years were taken for the study. Data collected from the patients reporting to the Insight CBCT Center, Pune. The Class I male horizontal slices had smaller measurements (P<.05) in both the soft and hard tissue than Class III by 0.4 to 1.5 mm at nearly all 9 measurements. The Class III pattern profile measurements were larger by 0.6 to 1.7 mm. The laterality measurements found to larger for the Class III as compared to Class I. In the female sample, no significance difference existed in the Class I and Class III PPA measurements on the horizontal slices (Fig. 4, 4a, 4b).

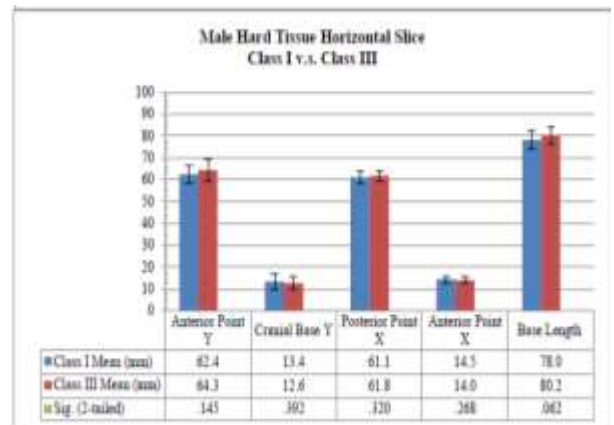


Fig. 4: Male hard tissue horizontal slice Class I versus Class III

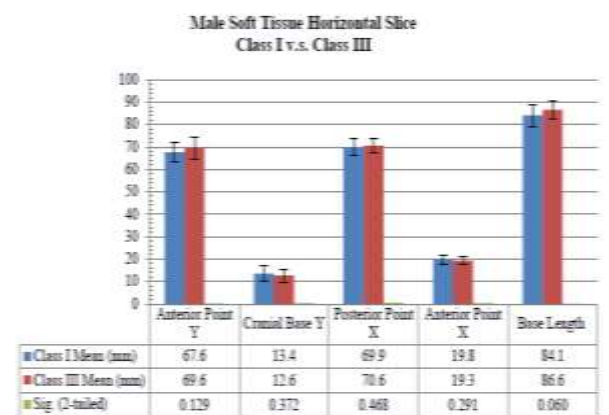


Fig. 4a: Male soft tissue horizontal slice Class 1 v.s. Class III

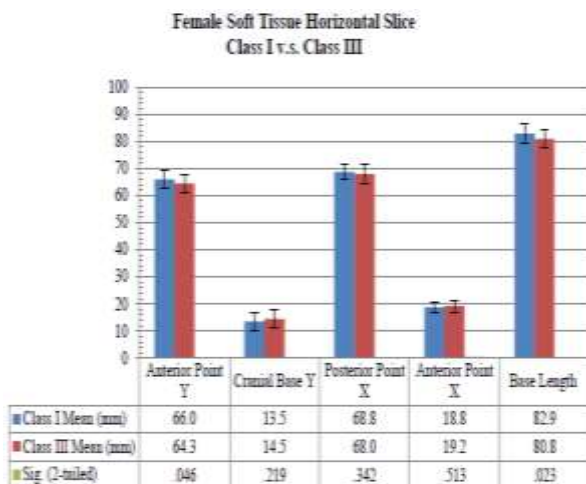


Fig. 4b: Female soft tissue horizontal slice Class 1 v.s. Class III

The Class I male and female pattern profile analysis showed no significant differences. Moreover, the cranial measurements in the Class I male and female comparison were not significant, with two exceptions. The hard tissue horizontal slice indicated that the male anterior point X value was 1 mm larger and that the posterior point X value was 1.4 mm larger.

The comparison of Class III male and female pattern profile analysis found that Class III males to be significantly greater ($P < 0.05$) for all points on the hard tissue horizontal slices. Significant differences with the PPA values for male being larger at points 1 through 4 by 0.4 to 0.9 mm. The horizontal soft tissue slice indicated no significant differences between the male and female slices. The cranial measurements found that the males had significantly greater measurements at the anterior point Y value, the posterior point X value and the baseline value. The males had larger anterior point Y values by 4.4 to 5.5 mm, larger posterior point X values by 2.6 to 3.0 mm and larger baseline measurements. On the other hand, the cranial base measurement for the males was significantly smaller by 1.8 to 1.9 mm, thus indicating that the cranial base point was closer to the X-axis in males (Fig. 5 & 5a).

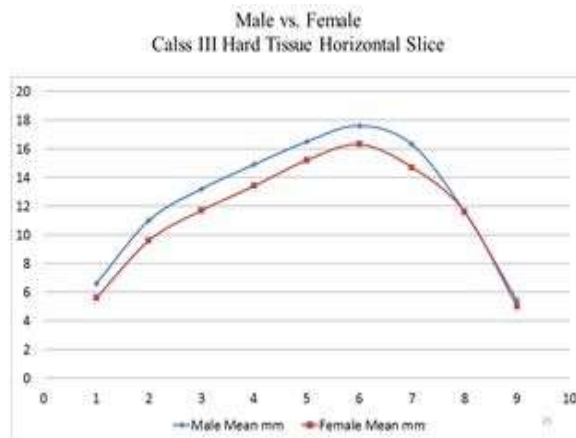


Fig. 5: Male vs. Female Class III hard tissue horizontal Slice

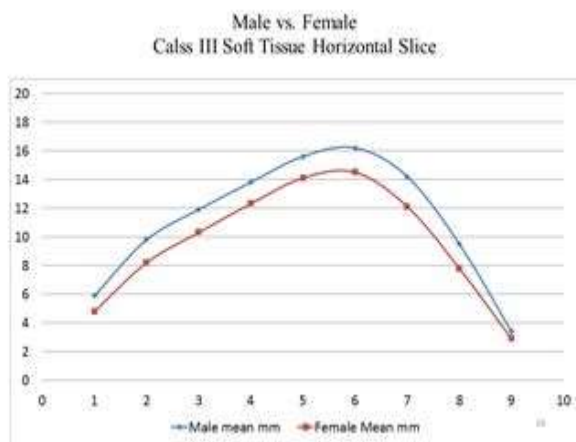


Fig. 5a: Male vs. Female Class III soft tissue horizontal Slice

Discussion

Craniofacial asymmetry previously been investigated using several different diagnostic methods. In the past, postero-anterior radiographs suggested for evaluation of facial asymmetry.⁽²⁸⁾ However, studies showed that these radiographs have limited reliability and provide incomplete assessment of soft tissues. Furthermore, they are subject to superimposition problems for deeper bony structures and rotation effects related to the patient's head position.^(9,29) Hwang et al⁽³⁰⁾ reported that this technique is not suitable for determining chin morphology, which is the region of the craniofacial complex most affected by asymmetry.⁽³¹⁾

Present study identifies the presence of soft tissue camouflage for hard tissue asymmetries in all three planes of spacing using 3D hard and soft tissue imaging. Thirty Class I and 30 Class III CBCT images (16 male, 14 female - each group) between the age group of 14-20 years were taken for the study. One of the benefits of the pattern profile analysis is that it enables comparison between similar structures on two

different individuals even though the structures are of different sizes. It does so by taking the same number of pattern profile measurements equally spaced along the baseline of each structure. Therefore, even though two objects may have different baseline lengths, their heights at each pattern profile measurement correspond to similar locations on each structure.

In Class III male, the pattern profile analysis shows that the Class III malar deficiency is greater. The comparison of female Class I and Class III is instructive as well. The pattern profile analysis showed that there was no significant difference between the malar prominence of the female Class I and Class III individuals. However, there was a significant difference in the anterior Y point and the baseline measurements, but not the cranial base and the posterior point measurements.

While comparing the male and female slices, the Class I male was 1 mm wider at the anterior and posterior X values on the hard tissue horizontal slice. Moreover, the pattern profile analysis showed no a difference on any slice or the hard or soft tissue.

The Class I male horizontal slices had smaller measurements ($P < .05$) in both the soft and hard tissue than Class III male measurements by 0.4 to 1.5 mm at nearly all 9 measurements. The Class III pattern profile measurements were larger by 0.6 to 1.7 mm. Ko et al found that more than 85% of their patients with skeletal Class III had facial asymmetry and deviated structural midlines.⁽³¹⁻³³⁾ Therefore, it was appropriate to select class III malocclusions for the study.

Class III male and female pattern profile analysis comparison found the Class III males to be significantly larger ($P < .03$) for all points on the hard tissue horizontal slices by 1 to 2 mm. Cranial measurements depict that the males had significantly larger measurements. The Class III male was larger than the Class III female in nearly all of the pattern profile analysis measurements, the anterior point Y measurements, the posterior point X values and the baseline measurements, but had a shorter cranial base measurement. Hence, the actual size of the malar prominence was greater and its position relative to other cranial structures was more prominent.

Limitation of the study is average age and sample size. A more accurate representation of the differences in the malar complex between Class I and Class III individuals is possible, if a larger sample size is opted for future study where all of the participants had finished growing. Further, sexual dimorphism exists in the Class III population. This can be a promising futuristic study to define the malar augmentation decisions in male and female class III patients to improve their facial appearance.

Conclusion

Class III male sample found to have a larger mid face deficiency than Class I male. Anterior component

of the Class III male's mid face showed posterior positioning. Class I and Class III female sample showed similar size and position of the mid facial complex (Statistically Insignificant). Class III male's mid facial deficiency was more, mid face complex positioned further laterally and elongated more anteriorly as compared to the Class I male and female Class III.

References

1. Terino EO, Flowers RS: The art of alloplastic facial contouring: Mosby Inc, 2000.
2. Kim Y-I, Park S-B, Son W-S, Hwang D-S: Midfacial soft-tissue changes after advancement of maxilla with Le Fort I osteotomy and mandibular setback surgery: comparison of conventional and high Le Fort I osteotomies by superimposition of cone-beam computed tomography volumes. *Journal of Oral and Maxillofacial Surgery* 2011, 69:e225-e33.
3. Jensen J, Reiche-Fischel O, Sindet-Pedersen S: Autogenous mandibular bone grafts for malar augmentation. *Journal of oral and maxillofacial surgery* 1995,53:88-90.
4. Nout E, Cesteleyn L, van der Wal K, van Adrichem L, Mathijssen I, Wolvius E: Advancement of the midface, from conventional Le Fort III osteotomy to Le Fort III distraction: review of the literature. *International journal of oral and maxillofacial surgery* 2008,37:781-9.
5. Hinckley RK: Characterization of malar deficiency in Class I and Class III individuals using CBCT. Saint Louis University, 2012.
6. Schmidseder J: Aesthetic dentistry: Univ of California Press, 2000.
7. Bell WH: Modern practice in orthognathic and reconstructive surgery: WB Saunders Company, 1992.
8. Powell NB, Riley RW, Laub DR: A new approach to evaluation and surgery of the malar complex. *Annals of plastic surgery* 1988, 20:206-14.
9. Terino E: Alloplastic facial contouring by zonal principles of skeletal anatomy. *Clinics in plastic surgery* 1992,19:487-510.
10. Siemionow MZ, Sonmez E: Face as an organ: the functional anatomy of the face. *The Know-How of Face Transplantation*: Springer, 2011. pp. 3-10.
11. Nkenke E, Vairaktaris E, Kramer M, Schlegel A, Holst A, Hirschfelder U, Wiltfang J, Neukam FW, Stamminger M: Three-dimensional analysis of changes of the malar-midfacial region after LeFort I osteotomy and maxillary advancement. *Oral and maxillofacial surgery* 2008,12:5-12.
12. Holdaway RA: A soft-tissue cephalometric analysis and its use in orthodontic treatment planning. Part I. *American journal of orthodontics* 1983,84:1-28.
13. Merrifield LL: The profile line as an aid in critically evaluating facial esthetics. *American journal of orthodontics* 1966,52:804-22.
14. Proffit WR, Fields Jr HW, Sarver DM: Contemporary orthodontics: Elsevier Health Sciences, 2014.
15. Graber TM, Vanarsdall RL: Orthodontics: current principles and techniques. 1994.
16. Koshy JC, Feldman EM, Chike-Obi CJ, Bullocks JM: Pearls of mandibular trauma management. *Seminars in plastic surgery*: © Thieme Medical Publishers, 2010. pp. 357-74.
17. Proffit WR, White RP, Sarver DM: Contemporary treatment of dentofacial deformity: Mosby St Louis, Mo, 2003.

18. Sutherland CT: Three-dimensional Age-related Changes in the Adult Face: African American Female Population. The University of Alabama at Birmingham, 2015.
19. Baik H-S, Kim S-Y: Facial soft-tissue changes in skeletal Class III orthognathic surgery patients analyzed with 3-dimensional laser scanning. *American journal of orthodontics and dentofacial orthopedics* 2010,138:167-78.
20. Božič M, Kau CH, Richmond S, Ovsenik M, Hren NI: Novel method of 3-dimensional soft-tissue analysis for Class III patients. *American Journal of Orthodontics and Dentofacial Orthopedics* 2010,138:758-69.
21. Kau CH, Richmond S: Three-dimensional analysis of facial morphology surface changes in untreated children from 12 to 14 years of age. *American Journal of Orthodontics and Dentofacial Orthopedics* 2008,134:751-60.
22. Cevidanes LH, Heymann G, Cornelis MA, DeClerck HJ, Tulloch JC: Superimposition of 3-dimensional cone-beam computed tomography models of growing patients. *American Journal of Orthodontics and Dentofacial Orthopedics* 2009,136:94-9.
23. Kim M, Lee D-Y, Lim Y-K, Baek S-H: Three-dimensional evaluation of soft tissue changes after mandibular setback surgery in class III malocclusion patients according to extent of mandibular setback, vertical skeletal pattern, and genioplasty. *Oral Surgery, Oral Medicine, Oral Pathology, Oral Radiology, and Endodontology* 2010, 109:e20-e32.
24. De Vos W, Casselman J, Swennen G: Cone-beam computerized tomography (CBCT) imaging of the oral and maxillofacial region: a systematic review of the literature. *International journal of oral and maxillofacial surgery* 2009,38:609-25.
25. Kim Y-I, Kim J-R, Park S-B: Three-dimensional analysis of midfacial soft tissue changes according to maxillary superior movement after horizontal osteotomy of the maxilla. *Journal of Craniofacial Surgery* 2010,21:1587-90.
26. Bozic M, Kau CH, Richmond S, Ihan Hren N, Zhurov A, Udovič M, Melink S, Ovsenik M: Facial morphology of Slovenian and Welsh white populations using 3-dimensional imaging. *The Angle orthodontist* 2009,79:640-5.
27. Roberts F, Pruzansky S, Aduss H: An x-radioccephalometric study of mandibulofacial dysostosis in man. *Archives of oral biology* 1975,20:265-IN5.
28. Djordjevic J, Pirttiniemi P, Harila V, Heikkinen T, Toma AM, Zhurov AI, Richmond S: Three-dimensional longitudinal assessment of facial symmetry in adolescents. *The European Journal of Orthodontics* 2011:cjr006.
29. Nur RB, Çakan DG, Arun T: Evaluation of facial hard and soft tissue asymmetry using cone-beam computed tomography. *American Journal of Orthodontics and Dentofacial Orthopedics* 2016,149:225-37.
30. Prendergast M, Schoenrock LD: Malar augmentation: Patient classification and placement. *Archives of Otolaryngology-Head & Neck Surgery* 1989,115:964-9.
31. Retna Kumari Narayanan M, Kumar TA: Prevalence of Malocclusion among 10-12-year-old Schoolchildren in Kozhikode District, Kerala: An Epidemiological Study. *International journal of clinical pediatric dentistry* 2016,9:50.
32. Massler M, Frankel JM: Prevalence of malocclusion in children aged 14 to 18 years. *American journal of orthodontics* 1951,37:751-68.
33. Ko EW-C, Huang CS, Chen YR: Characteristics and corrective outcome of face asymmetry by orthognathic surgery. *Journal of Oral and Maxillofacial Surgery* 2009,67:2201-9.