

Reliability of Submentoververtex Projection in Assigning a Reference Cranial Midline for the Assessment of Condylar Asymmetry- A cross-sectional study

Ashutosh Kumar Singh^{1,*}, Parita K. Chitroda², Nikhat M. Attar³, Shashi Shanker Chaubey⁴

^{1,3,4}PG Student, ²Professor, Dept. of Oral Medicine & Radiology, Al-Badar Rural Dental College, Gulbarga, Karnataka

***Corresponding Author:**

Email: kumarsingh.ashutosh409@gmail.com

Abstract

Introduction: The aim of the study was to compare the validity and reliability of two different methods for localization of the cranial midline through a cephalometric analysis of mandibular condylar asymmetry in a representative adult population. The hypothesis that the most reliable landmark for identifying transverse craniofacial asymmetry on SMV is spinosum foramina was tested.

Materials and Method: This cross-sectional study was performed by analyzing the SMV radiograms of 70 patients. Two different cephalometric analyses were chosen to trace the basicranium midline. The first considers the craniostat ear rods as initial landmarks and the second analysis uses the spinosum foramina (SF) as main landmarks to identify the axis of symmetry. Quantification of the condylar asymmetry was performed using eight parameters and their symmetrical ratio (Symmetry ratio (SR) = Left parameter/Right parameter).

Results: Statistical analysis of the results showed substantial equivalence and reliability of both tracing methods used. This reliability results from the fact that the left/right discrepancy for midline MP & MSP is not statistically significant. The extent of asymmetry falls within physiologic limit [2-3mm for left/right discrepancy from midsagittal plane is normal limit].

Conclusion: Submentoververtex radiograms can provide assistance in diagnosing condylar asymmetries and planning the most appropriate treatment. The results of this study failed to validate our hypothesis indicating that the midline traced with spinosum foramina as landmark approximates the ideal midsagittal more closely. However another study with bigger sample size should be conducted before refuting or accepting this hypothesis.

Keyword: Submentoververtex, Condylar asymmetry, Foramen Spinosum.

Introduction

Asymmetry of craniofacial structures is a normal biometric finding in population, although this asymmetry is often unnoticeable.⁽¹⁾ These little inconsistencies are considered as esthetically pleasing and add normalcy to the appearance. Asymmetry of the craniofacial complex is thought to be greater in childhood and adolescence because of relative growth imbalances between the left and right sides. Mandibular asymmetry may fluctuate in magnitude and side prevalence with increasing age. Facial asymmetry in children and adolescents might be related to gender. In adults no such association between gender and craniofacial asymmetry has been reported till date. Temporomandibular joint (TMJ) pathology, such as degenerative joint disease, has been identified to have significant contribution in growth disturbances, including mandibular deficiency and open bite. Occlusal instability, asymmetry of vertical facial dimension, and deviation of chin to the affected side are other clinical signs associated with TMJ pathology.⁽²⁾

Internal derangement (ID), i.e., disc displacement of the TMJ, is a common intra-articular disorder occurring as a result of abnormal relationship of the articular disc relative to the mandibular condyle, fossa, and articular eminence. It has been stated that 80% of patients with temporomandibular joint disorders (TMD) have a form of internal derangement. 94% of the pediatric TMD population has been found to have

Internal derangement. In asymptomatic juvenile orthodontic patients who were subjected to MRI, disc displacement has been discovered in 5% to 11.8% of patients.^(3,4)

Several authors have suggested that both TMJ internal derangement and degenerative joint disease could result in mild to moderate facial asymmetry because of mandibular growth deficit in a growing child or adolescent.^(3,5,6) This asymmetry has to be quantified during treatment planning of TMDs, orthodontic or surgical correction of asymmetry and for follow up. Magnetic resonance imaging is the gold standard for diagnosing abnormalities of TMJ, but it is costly and technically complex procedure that cannot be used for regular screening of condylar and craniofacial asymmetry in a normal dental set up. Submentoververtex (SMV) radiograms can overcome these limitations posed by the MRI as it provides good visualization of the skull base, mandible and condyles; it is relatively inexpensive, easily available and easier to perform in a regular clinical set up.⁽¹⁾

For assessment of asymmetry, determination of a reference midline of the cranium is of vital importance however no such universally accepted reference midline exists. Over the past several years many studies were done to evaluate the asymmetry using various reference midlines, however not many studies exist that have assessed the suitability of ear rods and spinosum

foramina as reference markers for drawing midline of cranial base on SMV radiographs.

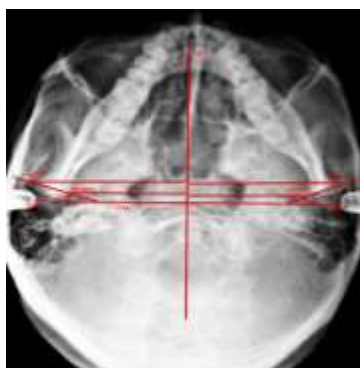
The aim of the study was to compare the suitability and reliability of two different methods for assigning a cranial reference midline, through analysis of SMV radiographs, for assessment of mandibular condylar asymmetry in a representative adult population. The hypothesis that the most reliable landmark for identifying transverse craniofacial asymmetry on SMV is spinosum foramina was tested.

Materials and Method

This cross-sectional study was carried out by analyzing the SMV radiographs of 70 patients, 31 females and 39 males; in the age range: 25-35years. All the subjects included in the study showed normal growth & development. Subjects with clinically apparent facial asymmetry, second or third class malocclusion, history of previous orthodontic treatment, functional mandibular deviation and subjects displaying any signs or symptoms of systemic pathologies or syndromes were excluded from participation.

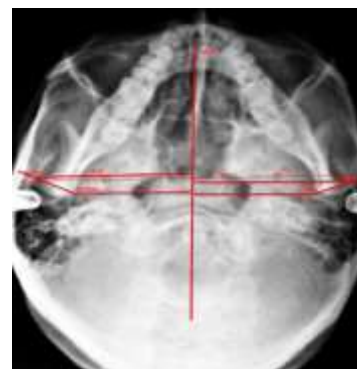
SMV projection radiographs were acquired by a single operator with a Kodak 8000C digital panoramic and cephalometric system. Radiographs were acquired after proper standardization of technique and were then traced manually by a single investigator. The anatomic landmarks used in the SMV analysis were extrapolated from work done by Lew and Tay and terminologies and parameters were derived from study done by Michele Maglione and Fulvia Costantinides.^(1,7)

Two different analyses were done to trace the reference midline. In first analysis craniostat ear rods are taken as reference landmarks (Tracing 1) and in second analysis spinosum foramina (SF) is considered as reference landmarks (Tracing 2) for assigning the reference midline for assessment of asymmetry.



Tracing 1- (i) MP-mid plane formed by perpendicular bisector of the line joining the mid points of terminal portion of the ear rods i.e. right and left mei (RM & LM), (ii) TPA- transporionic axis, (iii) RCOM-Medial terminal point of right condyle(right condyilion medialis), (iv) LCOM- Medial terminal point of left

condyle(left condyilion medialis), (v) RCOL- lateral terminal point of right condyle(right condyilion lateralis), (vi) LCOL- lateral terminal point of left condyle(left condyilion lateralis), (vii) R condyle-TPA angle- angle formed by line joining RCOM to RCOL with TPA in degree, (viii) L condyle-TPA angle - angle formed by line joining LCOM to LCOL with TPA in degree.



Tracing 2- (i) MSP- mid sagittal plane formed by perpendicular bisector of the line mid point of left and right foramen spinosum, (ii) RFS- mid point of right foramen spinosum, (iii) LFS- mid point of left foramen spinosum, (iv) TSA- trans-spinosal axis i.e. line joining RFS and LFS, (v) R condyle-TSA angle- angle formed by line joining RCOM to RCOL with TSA in degree, (vi) L condyle-TSA angle- angle formed by line joining LCOM to LCOL with TSA in degree.

Assessment of the condylar asymmetry was performed using eight parameters:

1. Left Condylar Width: distance between LCOM and LCOL
2. Right Condylar Width: distance between RCOM and RCOL
3. Left Condylar Angle: L condyle-TPA angle for tracing 1 & L condyle-TSA angle for tracing 2
4. Right Condylar Angle: R condyle-TPA angle for tracing 1 & R condyle-TSA angle for tracing 2
5. Left Intracondylar Hemidistance: distance between LCOM and MP for tracing 1(LCOM-MP) and LCOM and MSP for tracing 2 (LCOM-MSP).
6. Right Intracondylar Hemidistance: distance between RCOM and MP for tracing 1 (RCOM-MP) and RCOM and MSP for tracing 2 (RCOM-MSP).
7. Left Extracondylar Hemidistance: distance between LCOL and MP for tracing 1 (LCOL-MP) and LCOL and MSP for tracing 2 (LCOL-MSP).
8. Right Extracondylar Hemidistance: distance between RCOL and MP for tracing 1 (RCOL-MP) and RCOL and MSP for tracing 2 (RCOL-MSP).

Symmetrical ratio (SR) was taken as ratio of left to right parameter (SR =Left parameter/Right parameter).

For absolute symmetry SR is equal to 1.

All statistical analyses were performed with the SPSS software (11.5 version) using the Student's t-test for independent samples.

Result

- Mean values of the left and right parameters and their symmetrical ratios for Tracing 1 & 2 are summarized in Table 1 & 2 respectively. The mean condylar width found in this study is in accordance with the stated physiological range determined by various studies. The SR calculated for condylar angulation showed no significant variation for TPA and TSA (t-test; P = NS; C.I. 95%).
- The comparison of the SRs of the intracondylar and extracondylar hemidistance for the same tracing (for Tracing 1 using MP: t-test; P = 0.053 NS; C.I. 95%; for Tracing 2 using MSP: t-test; P = 0.14 NS; C.I. 95%) did not show any statistically significant variation, similar was the case for evaluation of SRs from the two different tracings

i.e. tracing 1 & 2 for same parameter (intracondylar hemidistance SR for MP versus MSP: t-test; P = 0.93; C.I. 95%; extracondylar hemidistance SR for MP versus MSP: t-test; P = 0.66; C.I. 95%).

Statistical analysis of the results shows suitability and reliability of both tracing methods used are reasonably equivalent. This supposition results from the fact that there is no significant left/right discrepancy for midline MP & MSP. The extent of asymmetry detected is in range of physiologic limit [2-3mm for left/right discrepancy is normal]. Mean SR for intra condylar and extracondylar hemidistance for both tracing 1 & 2 is equal, but symmetrical ratio is less than 1 for both hemidistances. Subjects included in this study were all Angle's class I patients with no clinical evidence of any TMD or history of orthodontic correction, i.e. they represent the most symmetrical subjects in the population. So the degree of asymmetry observed in this study represents the degree of physiological asymmetry.

Table 1: Shows the mean of left and right parameters and symmetrical ratios for tracing 1, using MP as midsagittal axis

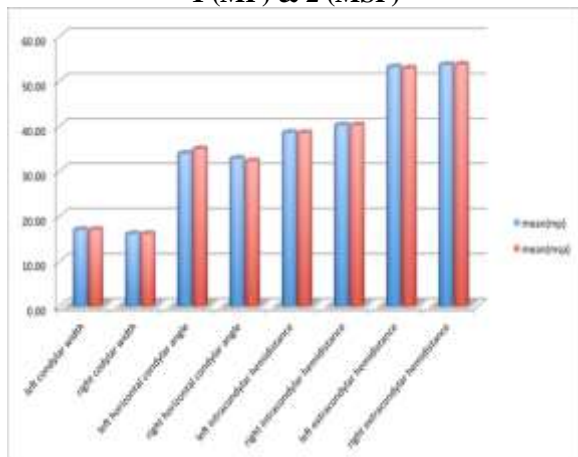
Tracing 1	Mean	St Dev.	left/right (symmetrical ratio SR)	St Dev.(SR)
Left condylar width	16.90	2.48	1.05	0.17
Right condylar width	15.97	2.04		
L condyle-TPA angle	33.83	7.76	1.07	0.26
R condyle-TPA angle	32.73	8.64		
LCOM-MP	38.47	2.66	0.96	0.07
RCOM- MP	40.1	2.41		
LCOL-MP	53.03	2.47	0.99	0.05
RCOL-MP	53.53	3.04		

Table 2: Shows mean of left and right parameters and symmetrical ratios for tracing 2, using MSP as midsagittal axis

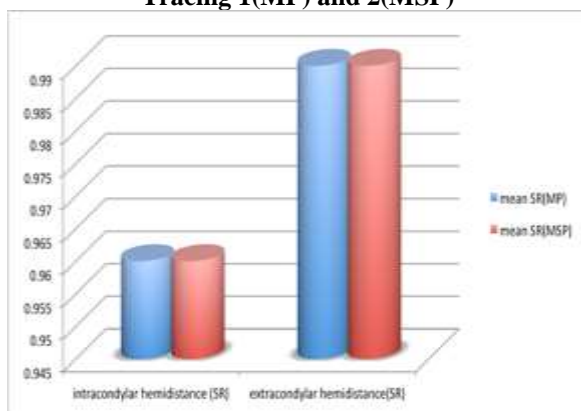
Tracing 2	Mean	St Dev	Left/right (symmetrical ratio SR)	St Dev(SR)
Left condylar width	16.90	2.48	1.05	0.17
Right condylar width	15.97	2.04		
L condyle-TSA	34.83	7.94	1.22	0.84
R condyle-TSA	32.13	9.8		
LCOM-MSP	38.4	2.8	0.96	0.08
RCOM- MSP	40.13	2.45		
LCOL-MSP	52.73	2.49	0.99	0.06
RCOL-MSP	53.6	3.38		

	Tracing 1 (MP)	Tracing 2 (MSP)
intracondylar hemidistance (SR)	0.96(0.07)	0.96(0.08)
extracondylar hemidistance(SR)	0.99(0.05)	0.99(0.06)

Graph 1: The bar graph shows the comparison of mean of all the eight parameters relative to Tracing 1 (MP) & 2 (MSP)



Graph 2: comparison of symmetrical ratios for intracondylar and extracondylar hemidistance for Tracing 1(MP) and 2(MSP)



Discussion

As reported by Haraguchi et al., asymmetry is a normal feature of a normal face and is determined by the discrepancy in size of left and right hemifaces.⁽⁸⁾ However in patients with significant asymmetry or asymmetry associated with pathological conditions it becomes imperative to record and assess this asymmetry for the purpose of diagnosis, treatment planning and follow-up following correction.

SMV provides good image of the base of the cranium and associated anatomic structures and is thus more helpful than other cephalometric views in determining a reference mid sagittal plane. Usefulness of this technique is limited by its two dimensional nature, its propensity for image distortion and difficulty in patient positioning.^(1,9,10) Quality and accuracy of this technique depends on multitude of variables and controlling all of them is difficult making the skill of the operator indispensable.

Although 3D radiographic techniques are standard and more popular for assessing TMDs and asymmetry of craniofacial structures, SMV remains a good choice

in clinical practice for diagnosing uncomplicated asymmetries.

Williamson et al and Trpkova et al. in their, study underlined the necessity to test the suitability of reference midline used for the evaluation of asymmetry as it has profound effect on magnitude of asymmetry, the values obtained changed significantly depending on the midline taken under consideration.^(2,11)

Our study consisted of 70 subjects, 39 males & 31 females. This was taking into consideration that no association between asymmetry and gender among adult population has been reported in the literature till date.^(12,13)

Results of this study revealed considerable similarity between both tracing methods and found them to be equally reliable in estimation of condylar asymmetry. The incongruity of left and right side for midline MP & MSP is not significant, also though not significant the subjects in this study showed slight dominance of right side, which is also, reflected in the mean symmetrical ratio of less than 1 for both intra & extracondylar hemidistances, this finding is in accordance with the findings of Haraguchi et al. Though the mean hemidistances for right side is slightly more, the mean horizontal angulation is more for the left condyle. The condylar width for both right and left condyle on an average is almost same. The range of asymmetry found in this study is in the range of physiologic limit. Mean SR for intra condylar and extracondylar hemidistance for both tracing 1 & 2 is equal, but symmetrical ratio is less than 1 for both hemidistances.

Subjects included in this study were all Angle's class I patients with no clinical evidence of any TMD, i.e. they represent the most symmetrical subjects in the population. So the degree of asymmetry observed in this study represents the degree of physiological asymmetry.

SR calculated for MSP does not agree with data obtained by Marmary et al. in their study on dry skull and study by Maglione M et al using SMV radiogram.^(1,14) Our study results failed to confirm higher reliability of foramen spinosum as a landmark for tracing co-ordinate system for condylar asymmetry.

The hypothesis that the spinosum foramina represent the most reliable starting points for identifying transverse craniofacial asymmetry and tracing its coordinate system is based on the fact that Spinosum foramina is located in the central part of cranial base that reaches adult dimensions in an early age and preserves its morphology throughout life. Specifically, Sejrnsen et al. found that the central area of the external cranial base reaches its maximum dimension at the age of 4-5 years' this is demarcated by the magnus foramen, by the stylomastoid foramina and spinosum foramina. As a result this area grows expeditiously until 4-5 years of age and decreases steadily and ultimately stops after this age. This is the

stated argument behind the suggestion that neurovascular foramina can serve as a landmark for assessment of maxillomandibular complex. However the subjects included in this study were adults with no history of any orthodontic intervention or TMD and as such reliability of both foramen spinosum and external acoustic meatus was found to be substantially similar in this study.⁽¹⁵⁾

Contradiction of our results with the study done by Maglione M et al, and recommendations of Arnold TG et al. regarding reliability of foramen spinosum for assessment of asymmetry, may be attributed to multiple variables involved in standardization of technique, differences in sample size and patient selection criteria. Limitations of this study include small sample size, lack of comparison with growing individuals and lack of comparison with 3d imaging modalities.

Conclusion

Submentoververtex radiograms are a reliable instrument in the assessment of condylar and craniofacial asymmetry. A careful analysis of SMV can be used with reasonable confidence for assessment and measurement of physiologic as well as pathological condylar asymmetry associated with TMDs. This study found that the both craniostat ear rods as well foramen spinosum are suitable markers for tracing the reference cranial midline for assessment of condylar asymmetry with neither being more reliable or suitable than the other in the adult population. The results of this study did not provide any evidence to support the hypothesis that the midline traced with spinosum foramina as landmark approximates the ideal midsagittal more closely. However another study with bigger sample size should be conducted before refuting or accepting this hypothesis.

References

1. Maglione M and Costantinides F. Localization of Basicranium Midline by Submentoververtex Projection for the Evaluation of Condylar Asymmetry. *Int J Dent* [internet]. 2012 Oct 11 [cited 2014 March 4]; 285693 [8 p]. Available from: <http://www.hindawi.com/journals/ijdent/2012/285693/> Free full tekst pdf. DOI:10.1155/2012/285693.
2. Trpkova B, Major P, Nebbe B, Prasad N. Prasad. Craniofacial asymmetry and temporomandibular joint internal derangement in female adolescents: a posteroanterior cephalometric study. *Angle Orthodont*. 2000;70(1):81–88.
3. Schellhas KP, Pollei SR, Wilkes CH. Pediatric internal derangements of the temporomandibular joint: effect on facial development. *Am J Orthod Dentofac Orthop*. 1992;101:79–83.
4. Tallents RH, Katzberg RW, Murphy BS, Proskin H. Magnetic resonance imaging findings in asymptomatic volunteers and symptomatic patients with temporomandibular disorders. *J Prosthet Dent*. 1996;75:529–533.
5. Nickerson JW, Boering G. Natural course of osteoarthritis as it relates to internal derangement of the temporomandibular joint. *Oral Maxillofac Clin North Am*. 1989;1(1):27–45.
6. Legrell PE, Isberg A. Mandibular height asymmetry following experimentally induced temporomandibular joint disk displacement in rabbits. *Oral Surg Oral Med Oral Pathol Oral Radiol Endod*. 1998;86:280–285.
7. Lew KKK and Tay DKL. Submentoververtex cephalometric norms in male Chinese subjects. *Am J Orthod Dentofac Orthop*. 1993;103(3):247–252.
8. Haraguchi S, Iguchi Y and Takada K. Asymmetry of the face in orthodontic patients. *Angle Orthodont*. 2009;78(3):421–426.
9. Uysal T and Malkoc S. Submentoververtex cephalometric norms in Turkish adults. *Am J Orthod Dentofac Orthop*. 2005;128(6):724–730.
10. Cheng AC, Lew KK and Bhole S. Head positioning and projection errors in submentoververtex radiographic analysis. *Singapore Dent J*. 1997;22(1):13–17.
11. Williamson PC, Major PW, Nebbe B, Glover KE and West K. Landmark identification error in submentoververtex cephalometrics: a computerized method for determining the condylar long axis. *Oral Surg Oral Med Oral Pathol Oral Radiol Endod*. 1998;86(3):360–369.
12. Ferrario VF, Sforza C, Poggio CE, Tartaglia G. Distance from symmetry: a three-dimensional evaluation of facial asymmetry. *J Oral Maxillofacial Surg*. 1994;52:1126–1132.
13. Arnold TG, Anderson GC, Liljemark WF. Cephalometric norms for craniofacial asymmetry using submental-vertical radiographs. *Am J Orthod Dentofac Orthop*. 1994;106(3):250–256.
14. Marmary Y, Zilberman Y and Mirsky Y. Use of foramina spinosa to determine skull midlines. *Angle Orthodont*. 1979;49(4):263–268.
15. Sejrnsen, Jakobsen J, Skovgaard LT and Kjær I. Growth in the external cranial base evaluated on human dry skulls, using nerve canal openings as references. *Acta Odontol Scand*. 1997;55(6):356–364.