

Orthodontic management of impacted teeth: An overview

Navneet Singh^{1*}, Dinesh Bagga², Tulika Tripathi³, Prateek Gupta⁴, Ritu Singh⁵

¹Senior Research Associate, ³Senior Professor & HOD, ⁴Research Fellow, Maulana Azad Institute of Dental Sciences, New Delhi, ²Professor & HOD, Dept. of Orthodontics & Dentofacial Orthopedics, School of Dental Sciences, Greater Noida, ⁵PG Student, Dept. of Oral Medicine & Radiology, ITS Centre for Dental Studies & Research, Muradnagar, Ghaziabad

***Corresponding Author:**

Email: dr.navneetgujjar@gmail.com

Abstract

Orthodontic management of impacted teeth can be very complex and requires a carefully planned inter-disciplinary approach. The development of treatment plans must be based on the careful analysis of the clinical situation and identification of the correct force system necessary to obtain the desired tooth movement. Appliance design is developed according to the treatment objectives and desired force systems. This article presents an overview of Prevalence, Etiology, Sequelae, Diagnosis, and orthodontic management of impacted tooth.

Introduction

Impaction refers to total or partial lack of eruption of a tooth well after the normal age of eruption.⁽¹⁾ An impacted tooth may result due to variety of reasons such as inadequate space, some physical barrier like bone, mucosa, retained deciduous tooth, supernumerary tooth etc. in the eruption path or lack of eruptive force. Normally tooth erupts when root length reaches three-fourth of its final length.⁽²⁾

Although the majority of impacted teeth are third molars, it is possible for any teeth to be impacted. These teeth often pose challenges in treatment planning, surgical care and orthodontic management. Favourable treatment outcome relies on patient compliance; proper and earlier age of diagnosis; level, inclination and depth of impaction; proportion of root development; type of surgical exposure and orthodontic mechanics employed. All these parameters play an important role when managing impacted teeth to achieve a good alignment in the arch, good gingival level and achieve good integrity of periodontium. The methods and techniques of resolution of impaction are numerous and their selection depends on individual case. Hence a review was warranted to summarize the various techniques used for disimpaction and evaluates their efficacy in successful alignment of the impacted teeth.

Prior studies on impacted teeth have been discussed but they are mainly case reports and review article only on maxillary impacted canine but no review article provides comprehensive information about all impacted teeth. This could indicate that few reports have been published on this subject and thus, make it necessary that dentists must increase their information in this field.

Incidence and Prevalence: The most commonly impacted teeth are third molars, maxillary canines, mandibular premolars and maxillary central Incisor in decreasing order.^(3,4) The incidence of mandibular and maxillary third molar impaction were reported to be 20% and 18% respectively and while maxillary canine

impaction has an incidence of 0.82%-2.8%.^(3,5) A high incidence of 3.29% of maxillary canine impaction has been reported in Turkish population.⁽⁵⁾ The lowest incidence has been reported in the Japanese population.⁽⁶⁾ Of all patients with maxillary impacted canines, it is estimated that 8% have bilateral impactions. The ratio of Palatal impactions is more than buccal canine impactions 2:1 or 3:1.^(7,8) The frequency of maxillary incisor impaction ranges from 0.06% to 0.2%.⁽⁴⁾ The incidence of mandibular canine impaction is 0.35%. Mandibular canine impaction is less frequent and the incidence has been reported to be 20 times lower than that for maxillary canines.⁽⁹⁾

Etiology of Impacted Teeth

Multiple factors are responsible for impaction. In this literature, the most commonly reported etiological factors were divided into two groups.⁽¹⁰⁻¹³⁾

Local Causes

- Irregular position or pressure of adjacent teeth.
- Greater density of overlying or surrounding bone.
- Fibrosis of overlying mucous membrane. (Due to long continued chronic inflammation)
- Lack of space due to under developed jaws.
- Over retained deciduous teeth.
- Premature loss of deciduous teeth.
- Changes due to infections or abscesses.
- Inflammatory changes due to exanthematous diseases.

Systemic Causes: Impactions are found in the absence of local predisposing factors:

- Prenatal causes: heredity.
- Postnatal causes: conditions that interfere with growth and development of the child such as Rickets, Anemia, Congenital syphilis, Tuberculosis, Endocrine dysfunction, Malnutrition, Irradiation.
- Rare conditions Cleidocranial dysplasia, Oxycephaly, Progeria, Achondroplasia, Cleft palate.

Sequelae of Impaction: Shafer et al⁽¹⁴⁾ outlined consequences of impaction which are (a) impacted tooth malpositioning, (b) arch length shortening due to migration of adjacent teeth (c) internal resorption, (d) root resorption of the impacted tooth, or adjacent teeth, (e) development of dentigerous cyst (f) infection, (g) pain, and (h) combinations of the above sequelae.

Diagnosis of Impaction: The diagnosis of impaction is made by synergistic evaluation of case history, clinical and radiographic examinations.

Case History: Prior history of any episode of trauma especially to the region of the mouth should be carefully recorded with approximate dates of occurrence.

Clinical examination: The following clinical signs are indicative of impactions which are presence of mucosal bulge (buccal or palatal) (Fig. 1), delayed eruption of permanent teeth, prolonged retention of deciduous teeth and the mesial and distal tipping or migration of adjacent teeth. Palpation compounds our understanding as a widening of labiolingual plates indicates presence of tooth at this level and narrowing indicates absence at this level. Moreover, hard swelling in the place where a shallow depression on either side of the anterior nasal spine is expected in case of dilacerated or impacted incisor. Palpation of a dilacerated central incisor is often made in two places, one being high in the upper labial sulcus and the other as a small and hard lump in the palate.

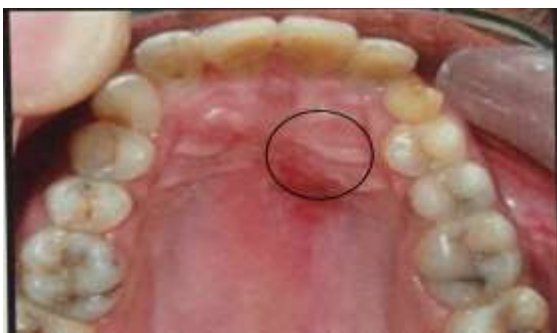

Fig. 1: Mucosal bulge on the palate depicting impacted canine

Radiographic examination

1. **Periapical films** A periapical film is the two dimensional picture of an area of dentition. To obtain a three- dimensional visualization, two periapical films are taken of the same area, with the horizontal angulations of the cone changed (Tube-shift technique or **Clark's rule** or **SLOB method**) (Fig. 2) or vertical angulations of the cone is changed by approximately 20° (**Buccal-object rule**), when the second film is taken. In other words, first film would relate the impacted tooth to the neighboring teeth both mesiodistally and superoinferiorly, A second periapical film would

provide position of the impacted tooth buccolingually.

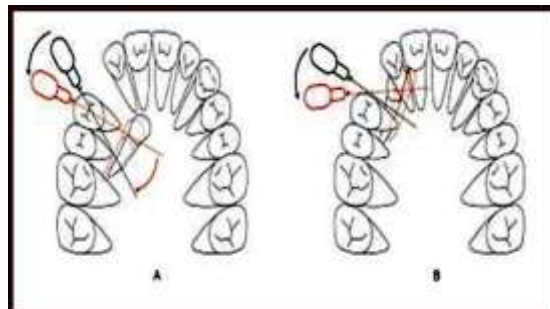


Fig. 2: Clark's method of buccolingual location of impacted object. Two IOPA X-rays are made while keeping the film in same location but X-ray tube is moved either mesially or distally. An object closer to the X-ray film, i.e. palatal will appear to move in the same direction as the X-ray beam while opposite is true for a buccal object. A. Palatal impacted canine moved distally with distal movement of X-ray B. Buccal impacted canine moved mesially with distal movement of X-ray

2. **Occlusal films** also help in visualizing the buccolingual position of the impacted tooth concurrent with the periapical films.
3. **Extraoral films**
 - a. Frontal and lateral cephalograms can sometimes aid in the determination of the position of the impacted tooth, particularly its relationship to other facial structures (e.g., the maxillary sinus and the floor of the nose).
 - b. Panoramic films are also used to localize impacted teeth in all three planes of space, much the same as with two periapical films in the tube-shift method, with the understanding that the source of radiation comes from behind the patient; thus the movements are reversed for position.
4. **Cone Beam Computed Tomography** is a novel method, which provides the orientation of the impacted tooth in all the three planes of space along with the 3 dimensional relationships with adjacent structures (Fig. 3).

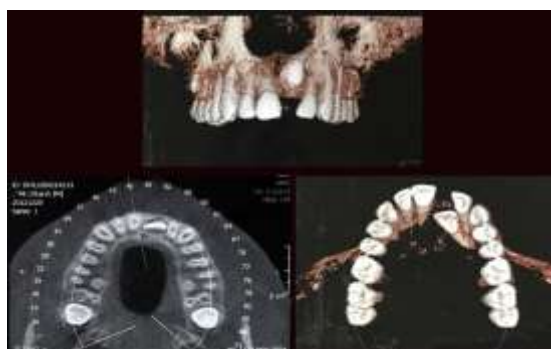

Fig. 3: Cone beam computed tomography images of impacted central incisor

Management of Impacted Teeth

General principles of mechanotherapy

1. **Appliance selection:** The appliance selected should have the capability to level and rotate all the teeth with controlled crown and root movements to open adequate space to accommodate the impacted tooth. This stage requires the use of fine leveling and aligning archwires.
2. **Preparation of anchorage unit:** With the initial alignment achieved and no further movement of individual erupted teeth needed, these teeth are transformed into a composite and rigid anchorage unit, this is done by substituting the flexible archwires with a heavier wire.
3. **Space regaining for impacted tooth:** Space for the impacted tooth should be created before surgical exposure by closure of existing incisor spacing, improving the arch form or by extraction of teeth. Space for the impacted tooth can be maintained by vertical stops bent in arch wire, stainless steel hollow tubing, coil spring, and tissue guards.
4. **Surgical exposure:** The surgical exposure of the crown of the impacted tooth should be performed in a manner that will achieve a good periodontal prognosis of the treated result. An attachment is bonded to it and the flap fully closed, with only a fine ligature wire leading through the gingival tissue to the recovered tooth.
5. **Active eruption of impacted tooth:** Using an auxiliary means of traction from the rigid orthodontic appliance, a gentle and continuous light force (about 60 gms), with a wide range of activation is applied to the tooth, and is aimed at erupting the impacted tooth.
6. **Final detailing** - There should be final detailing of the position of the formerly impacted tooth.

Management of Impacted Central Incisors: Early management of impacted central incisors is necessary as it can cause unesthetic appearance, compromised oral function and speech disturbance. Appliance modifications are required in early mixed dentition as all the teeth cannot be bonded, thus, orthodontic appliances used are:

1. A "two by four" appliance: At this age, two molars and no more than two incisor teeth of the maxillary permanent dentition are bracketed. Deciduous canines and molars have insufficient crown height and unfavorable anatomy to allow placement of a fixed multi-bracketed appliance.
2. Johnson's (modified) twin wire arch: Unique features consist of fixed molar bands, interconnected by a soldered palatal arch. Long narrow gauge (0.020" internal diameter) tubes slide freely in the round molar buccal tubes (0.036") and are made to extend anteriorly to the deciduous canine area.

3. Removable appliance: A modified labial bow with a helix was used along with elastic traction was used for disimpaction of impacted central incisors.⁽¹⁵⁾

Management of the Impacted Maxillary Canine:

Developmental considerations: The crowns of permanent canines develop in close relation to the lateral incisor roots. According to Dewel,⁽¹⁶⁾ maxillary canines have the longest period of development, as well as the longest and most tortuous course to travel from the point of formation, lateral to the piriform fossa, until they reach their final destination in full occlusion.

Broadbent advised to be wary of correcting flared and distally tipped lateral incisors before eruption of canines to check canine impaction or root resorption of the lateral incisors.

Management of the palatally Impacted Canine:

There are many surgical methods available for exposing the impacted canine. Two of the most commonly used methods are:

- a. Surgical exposure to facilitate natural eruption- The applicability of this method lies with correct axial inclination of canine without the need for uprighting. But its movement should closely monitored with the aid of radiographs at regular intervals.
- b. Surgical exposure with the placement of an attachment- After the surgical exposure of the impacted tooth, an attachment is placed on the crown followed by application of orthodontic forces to facilitate tooth movement.

Different methods of attachment to the impacted tooth have been suggested, including crowns, wire ligatures, chain links, bands, and directly bonded brackets.

Two approaches are generally recommended in regard to the timing of placing the attachment

Two-step approach:⁽¹⁷⁾ First, the canine is surgically uncovered and the area is packed with a surgical dressing to avoid the filling in of tissues around the tooth. Pack is removed after surgical wound healing and an attachment is placed on the impacted tooth.

One-step approach: After the surgical exposure, attachment is placed followed by excision of overlying tissues and placement of periodontal pack. This method is commonly applied for eruption of palatally impacted teeth. One of the important advantages of such an approach is that when the force is applied to the impacted tooth, the clinician is able to visualize the crown of the tooth and to have better control over the direction of tooth movement, thus avoiding damage to adjacent teeth or the impacted tooth itself.

Management of Labially Impacted Canines: Palatal impaction of the maxillary canine is more frequent than labial impaction and is usually the consequence of insufficient arch length. As a result, the canine is often positioned high in the alveolar bone and erupts through the alveolar mucosa. Fournier et al⁸ suggested that

labially impacted tooth with favourable vertical position will erupt on its own in younger patients after surgical exposure, whereas in older patients traction is required.

The adequate width of attached gingiva is necessary to prevent inflammation of the periodontium around the erupting canine. Vanarsdall and Corn⁽¹⁸⁾ stated that moving the impacted teeth through the area of inflammation is harmful to the periodontium.

Thus, it is suggested that eruption of impacted tooth should be attempted through band of attached gingiva. Otherwise, improper soft-tissue management may lead to mucogingival recession and loss of alveolar bone.

For guiding the impacted tooth into to the oral environment, several appliance designs have been advocated such as:

Ballista spring:⁽¹⁹⁾ It is a 0.014, 0.016 or 0.018 inch round wire, which accumulates its energy by being twisted on its long axis. It is placed in the head gear tubes of first maxillary molars, and it is ligated to this tube so that it cannot rotate in the tubes.

TMA box loop:⁽²⁰⁾ A 0.017 X 0.025 TMA wire is used. It produces sagittal and horizontal corrections while continuing vertical eruption.

Nickel titanium closed-coil spring:⁽²¹⁾ A 0.009" X 0.041" spring. It provides 80 gm of force when stretched to twice its resting length.

Mandibular anchorage:⁽²²⁾ A Lingual arch is fabricated with 0.036 inch stainless steel wire with vertical hooks (5-6mm in length). Elastic force should not exceed 40-60 gm.

The K- 9 spring:⁽²³⁾ It is made in 0.017" X 0.025" TMA wire. It is simple in design and exerts light continuous eruptive and distalizing forces.

Australian helical arch wire:⁽²⁴⁾ It is made in special plus .016" arch wire and force should not exceed 200 gm. It is activated by twisting the steel ligature wire every two weeks.

The Monkey hook:⁽²⁵⁾ It is a simple auxiliary with an open loop on each end for the attachment of intra oral elastic or elastomeric chain for connecting to a bondable loop button. A combination of monkey hooks and bondable loop-buttons allows the production of forces in a variety of directions such as vertical eruptive forces.

Easy-Way-Coil (EWC) system:⁽²⁶⁾ This EWC system consists of a Remanium closed-coil stainless steel spring, a .010" ligature wire, and a bondable lingual button. Last few coils of the spring were bend to make an eyelet and eyelet was attached to lingual button with a ligature wire. The EWC system allows the constant application of force throughout the eruption of impacted teeth.

Retention considerations: Becker et al⁽²⁷⁾ evaluated the post treatment results of the impacted teeth in patients whose orthodontic treatment had been completed. They observed an increased incidence of rotations and spacing on the impacted side in 17.4% of the cases,

whereas the incidence was found to be 8.7% on the control side. To minimize or prevent rotational relapse, a fibrotomy or a bonded fixed retainer may be considered by the clinician. Clark suggested that after the alignment of palatally impacted canines, lingual drift can be checked by removing halfmoon shaped wedge of tissue from the lingual aspect of the canine.

Management of Mandibular Canine: When the crown of an unerupted mandibular canine is inclined more than 30 degrees to the median sagittal plane, orthodontic treatment may be necessary to correct the inclination. To uncover a bonding surface on the crowns; an apically and laterally retracted flap must be created without damaging the periodontal integrity of the adjacent lateral incisor. Once an attachment is bonded, the orthodontist can begin to move the impacted canine distally to correct its path of eruption. When insufficient space is available in the arch, the treatment plan may need to include extraction of premolars.

When the unerupted mandibular canine has an inclination of more than 45 degrees, conservative treatment will be risky and uprighting the tooth into correct position will probably cause dehiscence of enveloping bone and serious periodontal defects.

Management of Impacted Second Premolars: The most common cause of impacted second premolars is space loss in the dental arch following early loss of deciduous second molar and drifting of two adjacent teeth, particularly the first permanent molars. The treatment may include creating space for impacted premolar by extraction of adjacent premolars to resolve the existing overcrowding in the entire dentition; re-siting drifted teeth to their ideal positions using fixed orthodontic appliance or extraction of the impacted tooth followed by alignment of other teeth in available space. The second premolars in the maxillary arch may even erupt spontaneously and resolve their palatal displacement.

Management of Impacted first Molar: Disimpaction of ectopic first molar from beneath the distal bulbosity of the second deciduous molar can be carried out with wedges including elastic separating ring/orthodontic separators. Placement of elastomeric separators mesial to the first molar should be avoided to prevent their dislodgement in apical direction and causing harm to the periodontium. A removable appliance, incorporating a cantilever spring passing across the interproximal area mesial to the impacted tooth can be used to apply a distal force or a fixed appliance can also be used.^(10,28-29)

Management of Impacted Mandibular Second Molars: Impaction of mandibular second molar is uncommon. Invariably impaction is due to a mesial inclination of the tooth, which brings it into contact with the distal side of the first molar, below its bulbosity and close to the cervical area, which probably is a sign of a short arch length and retro molar

crowding. Treatment includes surgical exposure of the occlusal surface of the molar by excising overlying mucosa followed by employment of a removable or a fixed molar uprighting spring.⁽³⁰⁻³⁶⁾

Management of Impacted Third Molars: Usually the Extraction of Third molar is done in cases where second molar is extracted, it can be dealt with same as second molar impaction.

Summary and Conclusion

Impacted tooth is the common challenge faced by dentists in routine practice. Successful and untroubled management of impaction depends on comprehension of mechanism of impaction, which depends on detailed knowledge of the development and eruption paths and patterns of the teeth. Usually management of impacted tooth requires the collaborative efforts of the orthodontist, periodontist and oral surgeon. But early recognition and keen understanding of impaction sometimes is sufficient to correct or check the development of malocclusion by interceptive treatment alone.

References

1. St. Louis: American Association of Orthodontics; 1993. Orthodontic Glossary.
2. Gron AM. Prediction of tooth emergence. *J Dent Res* 1962;41: 573-85.
3. Dachi SF, Howell FV: A survey of 3874 routine full-mouth radiographs. II. A study of impacted teeth. *Oral Surg Oral Med Oral Pathol* 1961, 14,1165–1169.
4. Grover PS, Lorton L: The incidence of unerupted permanent teeth and related clinical cases. *Oral Surg Oral Med Oral Pathol* 1985,59,420–425.
5. Aydin U, Yilmaz HH, Yildirim D: Incidence of canine impaction and transmigration in a patient population. *Dentomaxillofac Radiol* 2004,33,164–169.
6. Takahama Y, Aiyama Y. Maxillary canine impaction as a possible microform of cleft lip and palate. *Eur J Orthod* 1982;4:275-7.
7. Urbanowicz KK, Zadurska M, Czochrowska E. Impacted Teeth: An Interdisciplinary Perspective. *Adv Clin Exp Med* 2016,25,3,575–585.
8. Fournier A, Tourcotte J, Bernard C: Orthodontic considerations in the treatment of maxillary impacted canines. *Am J Orthod Dentofacial Orthop* 1982,81,236–239.
9. Ngan P, Hornbrook R, Weaver B. Early timely management of ectopically erupting maxillary canines. *Semin Orthod* 2005;11:152-63.
10. Becker A: Orthodontic treatment of impacted teeth. Wiley-Blackwell 2012, 3rd edition.
11. Archer W.H. Oral and maxillofacial surgery. 15th ed. W.B. Saunders Co. 1975.
12. Jacoby H. The etiology of maxillary canine impactions. *Am J Orthod* 1983;84:125-32.
13. Peterson LJ: Principles of management of impacted teeth. In Contemporary oral and maxillofacial surgery. Edited by Peterson LJ, Ellis EIII, Hupp JR, Tucker MR. St Louis: CV Mosby 1988, 223–256.
14. Shafer WG, Hine MK, Levy BM. A Textbook of Oral Pathology. 4th ed. Philadelphia Pa: WB Saunders; 1983:66-8.
15. Singh N, Tripathi T, Rai P, Kalra S, Neha. Impacted Central Incisor with Dilacerated Root-Treat with Ease. *J Clin Diagn Res.* 2016 Mar;10(3):ZJ07-8.
16. Dewel BF. The upper cuspids its development and impaction. *Angle* 1949;19:79-90.
17. Lewis PD. Pre-orthodontic surgery in the treatment of impacted canines. *Am J Orthod* 1971;60:382-97.
18. Vanarsdall, Corn. Soft tissue management of labially positioned unerupted teeth. *Am J Orthod* 1977;72:53-64.
19. Jacoby H. The ballista spring system for impacted teeth. *Am J Orthod* 1979;75:143-51.
20. Patel S, Cacciafesta V, Bosch C. Alignment of impacted canines with cantelivers and box loops. *J Clin Orthod* 1999;33:82-5.
21. Ross LL. Nickel titanium closed coil spring for extrusion of impacted canines. *J Clin Orthod* 1999;33 :99-100.
22. Sinha PK, Nanda RS. Mangement of impacted maxillary canine using mandibular anchorage. *Am J Orthod Dentofac Orthop* 1999;115:254-7.
23. Kalra V. The K-9 spring for alignment of impacted canines. *J Clin Orthod* 2000;34:606-10.
24. Hauser C, Lai YH, Karamalika E. Eruption of impacted canines with an Australian helical archwire. *J Clin Orthod* 2000;34:538-41.
25. Bowman S. A monkey hook- An auxiliary for impacted, rotated, and displaced tooth. *J Clin Orthod* 2002;36:375-8.
26. Schubert M. A new Technique for forced eruption of impacted teeth. *J Clin Orthod* 2008;34:175-9.
27. Becker A, Kohavi D, Zilbermann Y. Periodontal status following alignment of palatally impacted canine teeth. *Am J Orthod* 1983;84:332-6.
28. Hennessy J, Al-Awadhi EA, Dwyer LO, Leith R. Treatment of ectopic first permanent molar teeth. *Dent Update.* 2012 Nov;39(9):656-8, 660-1.
29. Yaseen SM, Naik S, Uloopi KS. Ectopic eruption - A review and case report. *Contemp Clin Dent.* 2011 Jan-Mar;2(1): 3–7.
30. Sawicka M, Racka-Pilszak B, Mazurkiewicz AR. Uprighting Partially Impacted Permanent Second Molars. *Angle Orthod* 2007;77(1):148-154.
31. Capelluto E, Lauweryns I. A simple technique for molar uprighting. *J Clin Orthod.* 1997 Feb;31(2):119-25.
32. Park DK. Australian Uprighting Spring for Partially Impacted Second molars. *J Clin Orthod* 1999;33:404-5.
33. Ruellas ACO, Pithon MM, Santos RL. Miniscrew supported coil spring for molar uprighting: description. *Dental Press J Orthod* 2013 Jan-feb;18(1):45-9.
34. Santoro M, Kim ES, Teredesai M, Karaggiannopoulos N. Modified removable transpalatal bar for uprighting of Impacted Second Molars. *J Clin Orthod* 2002 36(9):496-499.
35. Peterbantleon H, Droschil H. Molar Uprighting with Crossed Tip back Springs. *J Clin Orthod.* 1992;26(6):335-337.
36. Melsen B, Fiorelli G, Bergamini A. Uprighting of lower molars. *J Clin Orthod.* 1996 Nov;30(11):640-5.