

Assessment of cephalometric changes in pharyngeal airway involving first premolar extractions in Class II Division 1 Patients and Class I bimaxillary protrusion patients treated with fixed mechanotherapy: A retrospective study

Priyanka Patel^{1,*}, Nagaraj K.², Abhishek Jain³, Dhvani Doshi⁴, Ankita Ringane⁵

¹Private Practice, Surat, Gujarat, ²Reader, ^{4,5}PG Student, KLE VK Institute of Dental Sciences, Belagavi, ³Assistant Professor, Dept. of Orthodontics & Dentofacial Orthopaedics, Mansarovar Dental College, Bhopal, Madhya Pradesh

***Corresponding Author:**

Email: dr.priyanka.smile@gmail.com

Abstract

Introduction: Since the recent paradigm shift is towards the soft tissue considerations, pharyngeal airway evaluation is an important aspect of orthodontic diagnosis as well as treatment planning. Less is known about the effects of extraction of premolars on the pharyngeal airway dimensions in different malocclusions.

Aims and Objectives: To evaluate and compare the effects of first premolar extractions on changes in pharyngeal airway in Class II division 1 patients and Class I Bimaxillary protrusion patients treated with fixed mechanotherapy.

Methodology: Pre- and Post- orthodontic treatment lateral cephalograms of 40 patients with Class I Bimaxillary Protrusion and Class II Division 1 Malocclusion were chosen and various cephalometric linear and angular measurements were made.

Results: All the pharyngeal airway dimensional changes and hyoid bone positions in both the groups were non-significant. Among the other variables, skeletal parameters were not statistically significant but significant findings were found in dentoalveolar measurement indicating the amount of retraction of the anterior teeth.

Conclusions: The pharyngeal airway in Class II Division 1 Malocclusion and Class I Bimaxillary Protrusion Malocclusion is not affected by the extractions of the premolars. Further studies by 3-D imaging and dynamic airway resistance studies are required to validate these results.

Keywords: Pharyngeal airway, Class II division 1 malocclusion, Class I Bimaxillary Protrusion malocclusion.

Introduction

The upper airway has always been an area of interest because the oropharyngeal and nasopharyngeal structures play an important role in the growth and development of the craniofacial and orodental complex.⁽¹⁾ Hence, the ultimate goal of orthodontic treatment should not only be the coordination and stability of dentofacial structures and facial appearance but also the normal functioning of the stomatognathic system and airway.

Class II Division 1 malocclusion is often associated with obstruction of the upper pharyngeal airway and mouth breathing. Term “Adenoid facies” is often used to describe an aberrant craniofacial growth pattern characterized by lip incompetency, prominent mouth breathing, underdeveloped nose, increased anterior facial height, constricted dental arches and proclined maxillary incisors with a Class II occlusal relationship.⁽²⁻⁵⁾ Literature also suggests that the pharyngeal airway dimensions in Class II malocclusion subjects are relatively narrower than normal Class I subjects, hence predisposing them to sleep disordered breathing.⁽⁶⁻⁷⁾

Bimaxillary dentoalveolar protrusion usually presents with a convex lower facial profile, procumbent lips, and a protrusive anterior dentition, often resulting in lip incompetency, mentalis muscle strain, and excessive gingival display.

Extraction treatment improves facial aesthetics for many patients who present with a combination of

crowding and protrusion.⁽⁹⁾ Since, literature has reported narrower airway dimensions in Class II subjects, it is imperative to shed some light on their airway dimensional changes with camouflage treatment.⁽³⁻⁵⁾ Hence, this retrospective study aims to evaluate the effects of premolar extractions on pharyngeal airway dimensions in Class II Division 1 malocclusion patients and compare the same Class I Bimaxillary Protrusion Patients.

Materials and Methods

This retrospective study was carried out on the available Pre- and Post- orthodontic treatment records (Lateral cephalograms) of 20 patients each with Class II Division 1 Malocclusion and Class I Bimaxillary Protrusion who were treated at KLE V.K. Institute of Dental Sciences, Belagavi. An ethical approval was obtained for the same.

Inclusion criteria:

- Subjects in the age group 16-25 years
- Orthodontic treatment involving extractions of upper first premolars
- Patients treated with fixed mechanotherapy [MBT Prescription]
- Pre and post treatment radiographs with good hard and soft tissue outlines and teeth in good occlusion, lips resting in natural position
- **Class II division 1 Subjects:**
- Class II molar relation

- Overjet: ≥ 6 mm
- **Class I Bimaxillary protrusion Subjects:**
- Class I molar relation
- Interincisal Angle: $\leq 125^\circ$
- Upper Incisor to Maxillary Plane angle $\geq 115^\circ$

Exclusion criteria:

- Obvious hyperplasia of tonsils or adenoids on cephalograms
- Records of patients with medical history of chronic mouth breathing, tonsillectomy or adenoidectomy.
- Treatment involving use of a functional appliance or any orthognathic surgical procedure.

Table 1: Gender distribution and mean age of the sample

| | Class II Division 1 Malocclusion | Class I Bimaxillary Protrusion |
|------------------|----------------------------------|--------------------------------|
| Males | 4 | 6 |
| Females | 16 | 14 |
| Total number (n) | 20 | 20 |
| Mean age (years) | 18.2 \pm 3.086 years | 17.45 \pm 2.064 years |

Methodology

For each lateral cephalogram, landmarks for sagittal and vertical airway measurements, skeletal and dental measurements were identified, yielding 9 linear and 9 angular measurements.

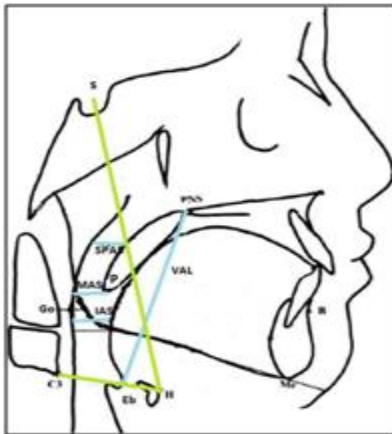


Fig. 1: Various measurements of airway dimensions and hyoid bone position

For evaluation of pharyngeal airway space, the upper pharyngeal airway space was divided into naso-, oro- and hypopharyngeal airways, according to the horizontal lines from PNS and Gonion to the posterior pharyngeal wall. The nasopharynx is above the PNS line and oropharynx is between the PNS and gonion lines. The hypopharynx is under the gonion line. The parameters included Superior pharyngeal airway space (SPAS), Middle airway space(MAS), Inferior airway space(IAS), vertical airway dimensions (VAL), vertical position of hyoid bone (SH) and horizontal position of hyoid bone(C3H).

Statistical Analysis: All the measured variables were expressed as means and standard deviations. Paired t test conducted to measure the differences between pre- and post-treatment measured variables for the same individuals in both the groups. Significance was predetermined at 0.05 levels. Independent t test was used to analyse the differences between measured variables in both the groups (Group 1: Class I Bimaxillary Protrusion Malocclusion, Group 2: Class II Division 1 Malocclusion).

Results

All the pharyngeal airway dimensional changes and hyoid bone position (SPAS, MAS, IAS, VAL, C3H, SH) in Class II Division 1 Malocclusion patients were non-significant, indicating that the extraction of premolars does not affect the pharyngeal airway in Class II Division 1 subjects.

Table 2: Pre and post-treatment changes in pharyngeal airway and hyoid bone position in Class II Division 1 Malocclusion

| | Pre-treatment values | Post-treatment values | Mean change | Std. Deviation | Significance |
|------|----------------------|-----------------------|-------------|----------------|--------------|
| SPAS | 11.45 | 11.09 | 0.36 | 1.97 | 0.423 |
| MAS | 8.86 | 8.15 | 0.72 | 2.20 | 0.161 |
| IAS | 7.97 | 7.32 | 0.65 | 1.86 | 0.132 |
| VAL | 52.15 | 52.28 | -0.13 | 4.00 | 0.884 |
| C3H | 29.01 | 28.64 | -0.36 | 2.10 | 0.438 |
| SH | 86.02 | 85.81 | 0.21 | 4.38 | 0.83 |

Table 3: Pre and post-treatment changes in pharyngeal airway and hyoid bone position in Class I Bimaxillary Protrusion

| | Pre-treatment values | Post-treatment values | Mean change | Std. Deviation | Significance |
|------|----------------------|-----------------------|-------------|----------------|--------------|
| SPAS | 11.54 | 11.27 | 0.27 | 2.29 | 0.601 |
| MAS | 9.18 | 8.54 | 0.64 | 2.02 | 0.171 |
| IAS | 9.38 | 9.32 | 0.06 | 2.00 | 0.9 |
| VAL | 54.39 | 54.15 | 0.23 | 4.07 | 0.8 |
| C3H | 32.24 | 32.05 | -0.206 | 1.57 | 0.569 |
| SH | 94.48 | 93.65 | -0.87 | 2.53 | 0.140 |

Table 4: Dentoalveolar Dimensions of Class II Division 1 Malocclusion and Class I Bimaxillary Protrusion

| | Class II Division 1 Malocclusion group | | | Class I Bimaxillary Protrusion group | | |
|------------|--|----------------|------------|--------------------------------------|----------------|-------------|
| | Pre-treatment | Post-treatment | Change | Pre-treatment | Post-treatment | Change |
| SNA | 83.16±3.86 | 79.9 ±3.09 | 1.70±2.72 | 82.48 ± 2.9 | 82.12 ± 3.14 | 0.35 ± 2.49 |
| SNB | 76.2±3.30 | 75.8±3.05 | 0.40±2.58 | 82.12 ± 3.14 | 78.7 ± 3.29 | -0.10 ±2.38 |
| ANB | 5.45±1.63 | 4.1±1.74 | 1.35±1.27 | 3.88 ± 1.83 | 3.42 ±1.84 | 0.45 ± 1.31 |
| U1-NA | 35.35±10.2 | 21.75±8.37 | 13.60±7.76 | 32.4 ± 6.05 | 21.4 ± 4.35 | 11.00±7.20 |
| LI-NB | 31.4±6.86 | 27.85±5.10 | 3.55±6.51 | 34.4 ± 6.66 | 23.45±4.85 | 10.95±7.76 |
| U1-SN | 118±8.21 | 101.55±9.18 | 16.45±8.50 | 115.25 ± 6.68 | 103.2±4.75 | 12.05±7.56 |
| L1-MP | 101.25±8.72 | 97.45±6.04 | 3.80±7.66 | 101.25±10.44 | 92.3 ± 8.03 | 8.95±10.84 |
| L1-APog | 3.26 ±2.05 | 1.77±1.46 | 1.49±2.04 | 5.44 ± 2.65 | 1.7 ± 1.94 | 3.74 ± 2.31 |
| U1-ANS-PNS | 126.4±6.2 | 110.05±7.93 | 16.35±6.48 | 122.85±5.53 | 110.2±5.42 | 11.95±8.53 |
| MP-FH | 26.35±4.83 | 26.45±4.8 | -0.10±1.77 | 27.7 ± 7.96 | 27.05±7.78 | 0.65 ± 3.30 |
| U1-NA(mm) | 8.45±2.62 | 3.18±2.02 | 5.27±2.33 | 7.7 ±2.53 | 3.48 ± 1.78 | 4.23 ± 3.09 |
| L1-NB | 6.96±2.07 | 5.26±1.9 | 1.70±2.02 | 8.53 ±2.64 | 4.64 ± 2.09 | 3.89 ± 2.81 |

Table 5: Comparison between the groups (Class II Division 1 Malocclusion and Class I Bimaxillary Protrusion)

| Parameter | Groups | Mean Value | Std Deviation | |
|-----------|---------|------------|---------------|--------|
| SPAS Pre | Group 1 | 11.45 | 2.55 | 0.905 |
| | Group 2 | 11.54 | 2.355 | |
| SPAS POST | Group1 | 11.09 | 2.211 | 0.809 |
| | Group 2 | 11.27 | 2.525 | |
| MAS PRE | Group 1 | 8.86 | 2.378 | 0.638 |
| | Group 2 | 9.18 | 1.791 | |
| MAS POST | Group1 | 8.15 | 2.364 | 0.592 |
| | Group2 | 8.54 | 2.192 | |
| IAS PRE | Group 1 | 7.97 | 2.559 | 0.067 |
| | Group 2 | 9.38 | 2.151 | |
| IAS POST | Group1 | 7.32 | 1.944 | 0.009* |
| | Group2 | 9.32 | 2.592 | |
| VAL PRE | Group 1 | 52.15 | 4.614 | 0.155 |
| | Group 2 | 54.39 | 5.114 | |
| VAL POST | Group1 | 52.28 | 3.882 | 0.223 |
| | Group2 | 54.15 | 5.525 | |
| C3H PRE | Group 1 | 29.01 | 2.77 | 0.003* |
| | Group 2 | 32.24 | 3.707 | |
| C3H POST | Group1 | 28.64 | 2.68 | 0.025* |
| | Group 2 | 32.05 | 3.83 | |

| | | | | |
|---------|---------|-------|--------|--------|
| SH PRE | Group 1 | 86.02 | 13.853 | 0.021* |
| | Group 2 | 94.48 | 7.417 | |
| SH POST | Group1 | 85.81 | 13.861 | 0.036* |
| | Group2 | 93.65 | 8.304 | |

Discussion

The relationship between craniofacial morphology and respiratory function has been studied extensively. Some authors claim that patients with deficient respiratory functions present with lip incompetency, increased anterior face height, maxillary constriction, protruded maxillary incisors with Class II molar relationship, open bite, and narrow external nares, so called 'adenoid facies'.⁽³⁻⁶⁾

In extraction treatment, one may think that altering incisor and soft tissue position and arch dimensions could affect tongue position and ultimately, the upper airway dimension. It has been speculated that the retraction of anterior teeth decreases the arch length, causing dorsal movement of the anterior boundary of oral cavity. Thus, the respiratory form and size of the pharyngeal airway should be taken into consideration, especially when extraction of four premolars and maximal retraction of anterior teeth is planned.^(1,9)

Pre- and post-treatment lateral cephalometric radiographs were used to measure the airway dimensions. Using lateral cephalograms to assess the airway dimension is considered a reliable method. The effect of growth may play a role when evaluating the dimensions of the pharyngeal airway. Hence, in this study, the age range selected was between 16-25 years to ensure that the pharyngeal structures have acquired their adult dimensions and that results would not be affected by the growth.

Pharyngeal Airway: In Class II Division 1 malocclusion groups, the mean overjet was 8.15 mm and the pre- and post-treatment pharyngeal airway dimensions (SPAS, MAS, IAS) were in agreement with the findings of Bollhalder et al,^(10,11) but the age group they used was mean 10.2 years thus, having an influence of growth. The findings of the present study were also in concordance with the results of T Muto et al.⁽¹²⁾ Kirjavainen and Kirjavainen⁽⁴⁾ concluded that the children with Class II malocclusion had a wider or similar nasopharynx than the control Class I Malocclusion but narrower oropharyngeal (OP) and hypopharyngeal areas. Presently, there are no studies that evaluate the effects of extractions of premolars on pharyngeal airway widths in Class II Division 1 malocclusion, and hence, the study results cannot be compared. In fact, the findings of this study may serve as a preliminary investigation in the matter.

In Class I Bimaxillary Protrusion malocclusion group, the mean pre- and post-treatment values for the superior, middle, inferior pharyngeal spaces and vertical airway length respectively are in agreement with those

of T Muto et al,⁽¹²⁾ Qingzhu et al⁽¹³⁾ and Maaitah E et al.⁽¹⁴⁾ Thus, the pharyngeal airway dimensions in Class I Bimaxillary Protrusion group in the present study were well within the ranges as described by the previous studies.

The Pharyngeal airway dimensions, however, did not show any significant differences post extraction despite considerable corresponding decreases in the dentoalveolar measurements. These findings are in concordance with the previous studies by Valiathan et al⁽¹⁾ and Maaitah E.⁽¹⁴⁾ Valiathan et al did not find any significant changes due to the age range they chose, as normal growth process, attributed these non-significant increases in the oropharyngeal volumes.⁽¹⁾ Maaitah E et al also evaluated the effects of first premolar extractions on the upper airway dimensions in 40 Class I Bimaxillary Protrusion patients in the range of 18-23 years and showed a decrease in the upper and lower incisor inclinations, and lower incisor to A-Pog line, but no airway dimensional changes, which is in agreement with the present study.⁽¹⁴⁾ In contrast, Germac-Cakan⁽¹⁵⁾ et al had carried out a study to investigate the upper respiratory airway dimensions in non-extraction and extraction subjects treated with minimum or maximum anchorage and reported the superior airway space and the middle airway space were increased significantly (mean 1.5mm) in the minimum anchorage group significant reduction of the middle airway space and inferior airway space in maximum anchorage group.

Hyoid Position: The hyoid position depends on the relative balance of muscle attachment from the base of the cranium bilaterally and the region of the mandibular symphysis.⁽¹⁶⁾ Wang et al confirmed that the horizontal spaces around the tongue were decreased with the downward movement of the hyoid bone caused by the retraction of incisors. It is believed that this movement is an adaptation preventing an encroachment of the tongue into the pharyngeal airway.⁽¹⁷⁾ Chen et al also inferred that the main reason for narrowing of the hypopharynx might have been the retraction of the hyoid, which in turn is caused by the retraction of the central incisors.⁽¹⁵⁾

There was no statistically significant difference in the pre- and post-treatment vertical and horizontal positions of the hyoid bone in Class II Division 1 group indicating that extractions of premolars did not affect the position of the hyoid bone. In the present study, pre and post treatment values for Class I Bimaxillary Protrusion group the horizontal and vertical positions of hyoid bone are in concordance to those found by Maaitah E et al⁽¹⁴⁾ and Wang et al.⁽¹⁶⁾

Comparison of groups: For pharyngeal airway, significant differences were found only in Inferior Airway Space post-treatment values where for Class II Division 1 groups, it was 7.32 ± 1.944 mm which was significantly less in comparison to that of Class I Bimaxillary Protrusion group (9.32 ± 2.592 mm). This may indicate that the influence of extractions leads to the narrowing of inferior airway space in Class II Division 1 malocclusion patients, especially with already present predisposition to a compromised airway.

It has been mentioned in the literature that malocclusion type does not influence pharyngeal airway width.⁽¹⁸⁻²⁰⁾ However, Kim *et al.* found that the mean total airway volume of retrognathic patients was significantly smaller than patients with normal antero-posterior relationship.⁽⁶⁾ Grauer *et al.* also confirmed that airway volume and shape differed among patients with different antero-posterior jaw relationships.⁽²¹⁾ Hakan El et al reported lowest oropharyngeal and nasopharyngeal airway volumes in Class II subjects with a retrusive mandible.⁽²²⁾ Kerr (1985) stated that subjects with Class II malocclusion showed smaller nasopharyngeal and adenoid areas.⁽⁵⁾ In a 3-D study by Kim et al, they found that the nasal airway volume of Class I subjects was bigger than Class II subjects, but it was not significant.⁽⁸⁾

In the present study, pre- and post-treatment comparative values of C3H and SH in both groups showed a more anterior and inferior position of the hyoid bone in Class I Bimaxillary Protrusion group than in Class II division 1 Malocclusion group. This is in agreement with the study by Kirjavainen M et al, where they associated a higher position of the hyoid bone in children with Class II Division 1 malocclusion than in controls.⁽⁴⁾ Chen et al inferred that the main reason for narrowing of hypopharynx could be retraction of the hyoid bone.⁽⁹⁾

Bollhalder et al stated that it seems that the size of the airway shows a wide inter-individual variation and is quite independent of the skeletal parameters. An explanation to this was given as that among the individuals with a small airway, there is an overlapping between those that have normal craniofacial structure and those that have normal craniofacial structures but are obese, have excessive soft tissue thickness or reduced airway dilator muscle activity.⁽¹¹⁾ This might a reason for the findings in the present study as the samples were not matched for the weight and BMI values.

It should be noted that airway size and shape is extremely variable depending on the head posture and the breathing stage and there are no norms or studies at this point to compare with our results.^(22,23)

Limitations of the study include a small sample size, use of lateral cephalograms for representation of a complex 3-D pharyngeal entity, difficulty in landmark identification, influence of breathing stage on the pharyngeal airway widths, and the groups were not matched for the body mass index, height and weight.

Future Scope of the present study: The same study may be carried out on a larger sample size with matched gender, weight and age to validate the results in a better way. Further studies may be aimed at long-term effects of orthodontic treatment on pharyngeal airway with three-dimensional imaging and long term research on dynamic analysis of airway resistance. A CBCT study may be carried out to evaluate the extraction effects on the pharyngeal airway and hyoid bone position in Class II Division 1 malocclusion patients and comparing the same with Class I Bimaxillary Protrusion patients. Cephalometric norms may be established for the upper airway dimensions in the Indian populations.

Summary

The respiratory form, size and the mechanobiological response of the pharyngeal airway should be taken into consideration, particularly, when extraction of four premolars and maximal retraction of anterior teeth are planned, as the pursuit of large incisor retraction may lead to a narrowing of the upper airway.

Conclusions

The present study concludes that:

- Extractions of either upper first premolars alone or upper and lower premolars in Class II Division 1 malocclusion subjects as well as Class I Bimaxillary Protrusion patients did not cause any significant pharyngeal airway dimensional changes or hyoid bone position, despite significant changes in dentoalveolar measurements.
- Decrease in Inferior Airway Space (IAS) was significantly more in Class II Division 1 malocclusion group than in Class I Bimaxillary Protrusion malocclusion group.

References

1. Valiathan M; El H; Hans M; Palomo M. Effects of extraction versus non-extraction treatment on oropharyngeal airway volume. *Angle Orthod.* 2010;80:1068-74.
2. Preston B. The upper airway and cranial Morphology. *Graber* 2011; pg 165.
3. Hakan El and Palomo J. An airway study of different maxillary and mandibular sagittal positions. *European journal of orthodontics.* 2013;(35):262-270.
4. Kirjavainen M; Kirjavainen T. Upper Airway Dimensions in Class II Malocclusion Effects of Headgear Treatment. *Angle Orthodontist*, 2007;77(6).
5. Kerr WJ. The nasopharynx, face height, and overbite. *Angle Orthodontist.* 1985;55:31-36.
6. Kim YJ, Hong JS, Hwang YI, Park YH. Three dimensional analysis of pharyngeal airway in preadolescent children with different anteroposterior skeletal patterns. *American Journal of Orthodontics and Dentofacial Orthopedics.* 2010;137:301-11.
7. Scott SH, Johnston LE. The perceived impact of extraction and non-extraction treatments on matched samples of African American patients. *Am J Orthod Dentofacial Orthop.* 1999;116:352-58.

8. Rains MD, Nanda R. Soft-tissue changes associated with maxillary incisor retraction. *Am J Orthod.* 1982;81:481–88.
9. Chen Y; Hong L; Wang C; Zhang S; Cao C; Wei F; Lv T; Zhang F; Liu D. Effect of large incisor retraction on upper airway morphology in adult bimaxillary protrusion patients: Three-dimensional multi-slice computed tomography registration evaluation. *Angle Orthod.* 2012;82:964–70.
10. Bollhalder J, Hanggi M, Schatzle M, Markic G, Roos M, Peltomaki T. Dentofacial and upper airway characteristics of mild and severe Class II Division 1 subjects. *EJO.* 2013;35:447-53.
11. Bollhauder. A cephalometric evaluation of the pharyngeal airway space in patients with mandibular retrognathia and prognathia, and normal subjects. *Int J Oral Maxillofac Surg.* 2008;37:228-31.
12. Muto T, Yamazaki A, Takeda S, Kawakami J, Tsuji Y, Shibata T, Mizoguchi I. Relationship between the pharyngeal airway space and craniofacial morphology, taking into account head posture. *Int J Oral Maxillofac Surg.* 2006;35:132–36.
13. Wang Q; Jia P; Anderson N; Wang L; Lin J. Changes of pharyngeal airway size and hyoid bone position following orthodontic treatment of Class I bimaxillary protrusion. *Angle Orthod.* 2012;82:115–21.
14. Emad Al Maaitah. First Premolar extraction effects on upper airway dimension in bimaxillary proclination patients. *Angle Orthod.* 2012;82:853-59.
15. Germec-Cakan D1, Taner T, Akan S. Uvulo-glossopharyngeal dimensions in non-extraction, extraction with minimum anchorage, and extraction with maximum anchorage. *Eur J Orthod.* 2011 Oct;33(5):515-20.
16. Wang Q; Jia P; Anderson N; Wang L; Lin J. Changes of pharyngeal airway size and hyoid bone position following orthodontic treatment of Class I bimaxillary protrusion. *Angle Orthod.* 2012;82:115–21.
17. Durzo CA, Brodie AG. Growth behavior of the hyoid bone. *Angle Orthod.* 1962;32:193–204.
18. Alves PV, Zhao L, O'Gara M, Patel PK, Bolognese AM. Three-dimensional cephalometric study of upper airway space in skeletal class II and III healthy patients. *J Craniofac Surg.* 2008 Nov;19(6):1497-507.
19. de Freitas MR, Alcazar NM, Janson G, de Freitas KM, Henriques JF. Upper and lower pharyngeal airways in subjects with Class I and Class II malocclusions and different growth patterns. *Am J Orthod Dentofacial Orthop.* 2006 Dec;130(6):742-5.
20. Watson RM Jr, Warren D W, Fischer N D. Nasal resistance, skeletal classification, and mouth breathing in orthodontic patients. *American Journal of Orthodontics.* 1968;54:367-79.
21. Grauer D, Cevidanes L S, Styner M A, Ackerman J L, Proffit W R. Pharyngeal airway volume and shape from cone- beam computed tomography: relationship to facial morphology. *American Journal of Orthodontics and Dentofacial Orthopaedics.* 2009;136:805-14.
22. El H, Palomo JM. Airway volume for different dentofacial skeletal patterns. *Am J Orthod Dentofacial Orthop.* 2011 Jun;139(6):511-21.
23. Lenza MG, Lenza MM, Dalstra M, Melsen B, Cattaneo PM. An analysis of different approaches to the assessment of upper airway morphology: a CBCT study. *Orthodontic and craniofacial research.* 2010;13:96-105.