

Evaluation of morphology and position of glenoid fossa in Class I and Class II malocclusions- A cephalometric study

Nagaraj K.¹, Roopa Jatti², Sujala Ganapati Durgekar^{3,*}

¹Reader, ²Professor, Dept. of Orthodontics & Dentofacial Orthopaedic, KLE Vishwanath Katti Institute of Dental Science, Belgaum, ³Reader, KLE Society's Institute of Dental Science & Hospital

***Corresponding Author:**

Email: sujala2003@yahoo.com

Abstract

Aim: To analyse glenoid fossa position in Class I, II (div 1 and 2) malocclusions and to analyse variation in the shape of the glenoid fossa in different mandibular configurations. **Materials and Methods:** The cephalometric study was carried on lateral films of 45 subjects aged 12 - 18 years. They were divided into three groups based on the ANB angle (and anterior occlusal relation) and also based on the mandibular plane angle. Analysis comprised of linear and angular measurements for the assessment of the position of the glenoid fossa and the inclination of articulating surface of the glenoid fossa, which was also correlated with the mandibular configuration.

Results: A study group with Class I and II malocclusion div 1 and 2 showed statistically insignificant difference in vertical sella fossa distance whereas, Class II (div 1 and 2) malocclusions showed increased horizontal sella fossa distance than the Class I study group. Low angle subjects showed increased vertical sella fossa distance and ramus height than high angle subjects. Subjects with steep articular eminence inclination have acute gonial angles and subjects tending towards flat articular eminence have obtuse gonial angles. **Conclusion:** With proper mechanics, Class II cases can be corrected by anterior displacement of the glenoid fossa, high angle cases by an inferior displacement and the reverse for low angle cases.

Keywords: Glenoid Fossa Position, Lateral Cephalograms, Articular Inclination.

Introduction

Malocclusions are the result of various combinations of underlying dental and skeletal disharmonies that involve several components of the craniofacial region.⁽¹⁾ Balanced facial profiles are achieved only when a balance exists between the amount of horizontal and vertical growth of the craniofacial complex and the relationship of maxilla and mandible to cranium.⁽²⁾ Anteroposterior skeletal Class I, II, III malocclusions, can result from a discrepancy in the size of either the jaw bases or too far anterior / posterior positioning of glenoid fossa resulting in an abnormal position of the mandible relative to the maxilla. Similarly, the vertical facial dimensions are affected by various parameters, one of them being the position of the glenoid fossa relative to cranium.⁽²⁾ As the mandible articulates with the skull only at the glenoid fossa, the position of the mandible relative to the cranium is highly dependent upon the position of glenoid fossa. Some studies have shown that normal variation in the shape of the glenoid fossa is associated with the differences in configuration of the mandible.^(3,4)

Despite the recognized role of the glenoid fossa in the etiology of malocclusions, as well as during orthodontic treatment, the literature⁽²⁻⁹⁾ provides only limited data about the significance of the position of the temporomandibular joint within the human skull in orthodontic diagnosis. Hence, the purpose of this study was to analyse the position of the glenoid fossa in Class I normal occlusion and to compare it with Class II division 1 and 2 malocclusions and to analyse variation

in the shape of the glenoid fossa in relation to the configuration of the mandible.

Materials and Methods

A sample of 45 subjects aged 12 - 18 years in permanent dentition was selected from the files available in the span of one year from the department of Orthodontics K.L.E S's Institute of dental sciences, Belgaum. After obtaining ethical clearance from the selected patients, the cephalometric study was carried out on their lateral films before any orthodontic treatment. All cephalograms were taken by means of the same X-ray device and by a single technician.

Inclusion criteria:

1. An essential criterion for case selection was represented by well detectable contours of the glenoid fossa on the good quality lateral cephalograms.
2. Subjects with no history of traumatic injuries.
3. Subjects with no history of complex craniofacial deformities or syndromes.

These 45 subjects were divided into 3 groups (15 subjects each) based on ANB and anterior occlusal relationship.

- a) Class I normal occlusion.
- b) Class II division 1 malocclusion.
- c) Class II division 2 malocclusion.

Cephalometric analysis

The standard tracings of osseous, dental and soft tissues were done on an 8x10inch matte acetate paper of

0.003inch thickness using a 0.5 HB lead pencil by one investigator and checked by another investigator for all the landmark location. The cephalometric landmarks and planes used in the study are shown in Fig 1. The following linear and angular measurements were made to the nearest of 0.5 degrees and 0.5mm respectively.

I: Linear measurements (Fig 1):

1. Horizontal sella fossa distance(X): The horizontal distance from the glenoid fossa summit to a line perpendicular to sella nasion at sella.
2. Vertical sella fossa distance(Y): The perpendicular distance from the fossa summit to a sella nasion line.
3. Ramus height (RH): The linear distance from the fossa summit to gonion.

II: ANGULAR MEASUREMENTS (Fig 1):

- 1) SNA: sella nasion –Point A angle.
- 2) SNB: sella nasion –Point B angle.
- 3) ANB: Point A-nasion –Point B angle
- 4) SN-MP: Angle between sella nasion plane and gonion gnathion mandibular plane.
- 5) AE-SN (Angle 1): Angle between the articulating surface of the glenoid fossa and the sella nasion plane as shown in Fig 2.
- 6) AE-CP (Angle 2): Angle between the articulating surface of the glenoid fossa and the clival plane as shown in Fig 2.
- 7) Gonial angle (Angle 3): The angle between the posterior border of mandible and inferior border of the mandible.

These linear and angular cephalometric measurements were further distributed to evaluate the skeletal sagittal and vertical relationship as well as to evaluate the relationship between glenoid fossa and mandibular configuration.

I. sagittal parameters (Fig 1)

SNA, SNB, ANB and Horizontal sella fossa distance (X).

II. Vertical parameters (Fig 1)

SN-MP, Vertical sella fossa distance(Y), Ramus height (RH).

III. GLENOID FOSSA AND MANDIBULAR MORPHOLOGY: (Fig 2)

AE-SN (Angle 1), AE-CP (Angle 2), Gonial angle (Angle 3).

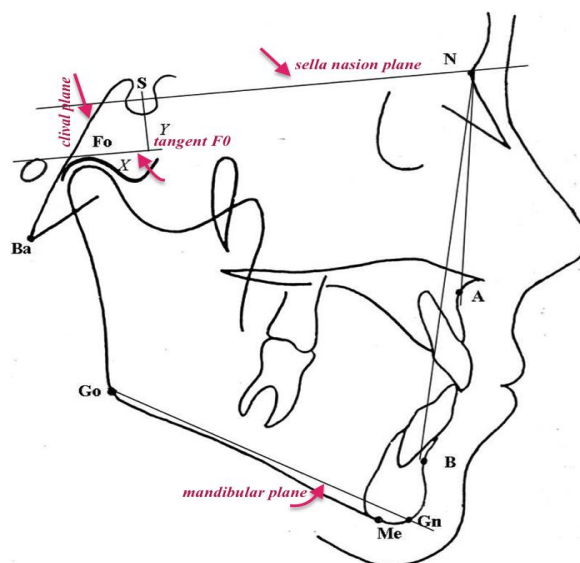


Fig. 1: Cephalometric points and planes used to measure horizontal and vertical position of glenoid fossa

Points used in the analysis:

- 1) Sella turcica(S): The midpoint of the Hypophyseal fossa.
- 2) Nasion (N): The most anterior point of the frontonasal suture in the medial pane.
- 3) Gonion (Go): A constructed point, the intersection of the lines tangent to the posterior border of ascending ramus and the mandibular base.
- 4) Menton (Me): The most caudal point in the outline of symphysis.
- 5) Subspinale (Point A): The deepest midline point in the curved bony outline from the base to the alveolar process of the maxilla.
- 6) Supramentale (Point B): The most posterior point in the outer contour of the mandibular alveolar process, in the median plane.
- 7) Fossa summit(Point Fo): The point on the superior margin of the glenoid fossa where a line parallel to the sella nasion plane lies tangent to the superior curvature

Planes used in the analysis:

- 1) Sella Nasion plane: The anteroposterior extent of the anterior cranial base.
- 2) Tangent Fo: A line passing through fossa summit parallel to sella nasion plane.
- 3) Gonion Menton mandibular plane: A line joining gonion and menton points.
- 4) Gonion gnathion mandibular plane: A line joining gonion and gnathion points.
- 5) Clival plane: A line drawn tangent to the clivus.

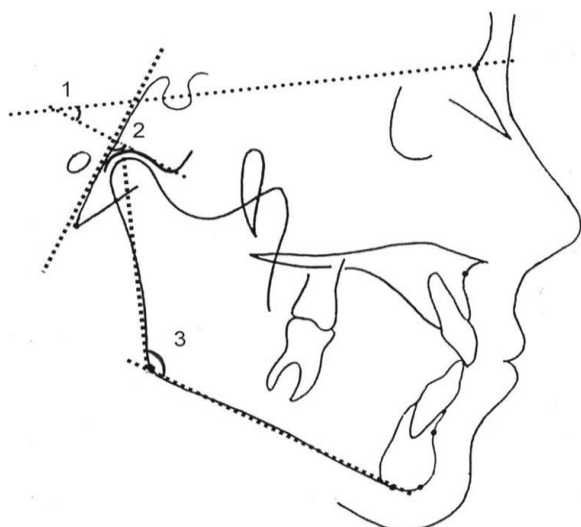


Fig. 2: Cephalometric planes used to measure articular eminence inclination and gonial angle

- 1) Angle between posterior slope of AE and S-N plane
- 2) Angle between posterior slope of AE and clivus.
- 3) Angle between mandibular plane and S-N plane.

Statistical analysis

Descriptive statistics were calculated for each cephalometric parameter in all 45 subjects. The comparisons between the Class I, Class II div 1 and Class II div 2 were performed by means of parametric test (student’s unpaired ‘t’ test). Correlation between the different cephalometric parameters was found by evaluating correlation coefficient(r).

All cephalometric measurements were repeated 5 weeks later by the same investigator. If there was a difference between the 2 measurements, a third reading was made, and the aberrant one was discarded. The mean of the 2 closest was used in the calculations. All the statistical analyses were performed with the SPSS software package (SPSS for windows 98, version 10.0, SPSS, Chicago, III).

Results

Sagittal and vertical position of glenoid fossa were analysed in the study groups (Class I occlusion, Class II div 1 and 2).

Sagittal position of the glenoid fossa: Class II div1 and Class II div2 malocclusions has increased horizontal sella fossa distance (X) than compared to normal Class I occlusion (Table 1). ANB has moderately high degree of significant positive correlation (Table 2) with X distance (r=0.6) whereas SNB has negative correlation with X distance (r=-0.5). The difference in X distance among Class II (div 1 and 2) malocclusion and Class I occlusion (Table 3) was statistically significant (p<0.01).

Vertical position of the glenoid fossa: Table 3 shows that the difference in the vertical sella fossa distance(Y) between Class II (div1 and div 2) malocclusion and Class I occlusion is statistically insignificant. There is very low degree of correlation of both ANB and SNB with Y distance (with r= -0.3 and r= 0.2 respectively) and it is statistically insignificant, with p>0.05 (Table 2).

As the relationship between the ANB (and anterior occlusion) and vertical position of glenoid fossa is statistically insignificant, all the study subjects were regrouped based on mandibular plane angle (Table 4) because the mandibular plane angle is a most reliable measurement in the assessment of skeletal vertical proportions.⁽²⁾ The vertical parameters (the vertical sella fossa distance and ramus height) were compared among average, high and low mandibular plane angle group. Criteria for categorization of group was mandibular plane angle (GoGn-SN). Subjects with 28-35 degrees of mandibular plane angle was grouped as average, 17-27 degrees as low angle and 36-48 degrees as high angle. The group with low mandibular plane angle showed increased vertical sella fossa distance and ramus height than compared to high mandibular plane angle group. There was high degree of negative correlation of both Y distance and ramus height with mandibular plane angle (with correlation coefficient r being -0.8 and -0.7 respectively) as shown in Table 5. This correlation is statistically significant with p value being <0.01 and < 0.05 respectively. This indicates that high angle cases have less Y distance.

Once the position of glenoid fossa (horizontal and vertical) were analysed, the morphology of glenoid fossa was compared with morphology of mandible based upon gonial angle.

Table 1: Values for X and Y when subjects grouped by ANB angles

Study group	ANB(°)		SNB(°)		X(MM)		Y(MM)	
	Mean	SD	Mean	SD	Mean	SD	Mean	SD
Class I	2.86	1.73	79.9	3.8	15.93	2.52	17.73	3.12
Class II DIV1	6.26	2.25	76	3.44	18.3	2.48	15.7	4.09
Class II DIV2	4.2	1.42	76.8	3.62	18.7	3.95	16.4	5.54

Table 2: Tabulation showing correlation of various cephalometric parameters

Cephalometric parameters	Correlation coefficient(r)	P Value
ANB vs X	0.6	<0.05**
SNB vs X	-0.5	<0.05**
ANB vs Y	-0.3	>0.05***
SNB vs Y	0.2	>0.05***
SN-MP vs Y	-0.79	<0.05**
SN-MP vs RH	-0.64	<0.01*
AE-CP vs Gonial angle	0.58	<0.01*
AE-SN vs Gonial angle	-0.59	<0.01*

* p <0.01 very significant, **p < 0.05 significant, ***p > 0.05 Not significant

Table 3: P value to evaluate the comparison of X and Y measurements among groups.

Study groups	Cephalometric parameters	Correlation coefficient (r)	P Value
Class I vs Class II Div 1	X (mm)	0.01	<0.05**
Class I vs Class II Div 2	X (mm)	0.03	<0.05**
Class II Div 1 vs Class II Div 2	X (mm)	0.1	>0.05***
Class I vs Class II Div 1	Y(mm)	0.13	>0.05***
Class I vs Class II Div 2	Y (mm)	0.4	>0.05***
Class II Div 1 vs Class II Div 2	Y (mm)	0.1	>0.05***

p < 0.05 significant, *p > 0.05 Not significant

Table 4: Values for Y and RH when subjects grouped by the mandibular plane angle

mandibular plane angle SN-MP(°) Mean SD		No. of subjects	Growth pattern	Y(MM) Mean SD		Ramus height(MM) Mean SD	
30	2.03	17	Average	15.85	3.63	59.52	6.4
20.57	3.06	19	Low	18	3.27	64.68	4.4
42.22	6.22	09	High	16.27	4.61	54.11	2.9

**Table 5: Values for angles AE-CP and AE-SN when subjects grouped by gonial angles
Define the categories for each group**

No. of subjects	Gonial angle (°) Angle 3	Inference	AE-CP (°) Angle 2	AE-SN (°) Angle 1
15	120-130	Average	67	57.7
15	<130	Obtuse	72.9	53.4
15	>120	Rectangular	58.4	65.66

Relation between morphology of glenoid fossa and mandible: In order to relate morphology of glenoid fossa and mandible, gonial angle was considered to regroup the available sample. Each group consisted of 15 sample size. Gonial angle ranging from 120-130 degrees were average mandibular morphology, more than 130 degrees were obtuse mandibular morphology, less than 120 degrees were rectangular mandibular morphology. Table 5 shows that as the gonial angle increases (obtuse-mandibular morphology), angle AE-CP increases and angle AE-SN decreases. Likewise, as the gonial angle decreases (rectangular-mandibular morphology), angle AE-CP decreases and angle AE-SN increases.

Table 5 also shows the correlation of gonial angle with AE-CP and AE-SN is very significant with $p < 0.01$ (correlation coefficient r being 0.58 and 0.59 respectively).

Discussion

One of the indispensable tools in orthodontics for assessing the profile of an individual is a detailed cephalometric analysis. In the assessment of orthodontic problems, the determining role of the glenoid fossa position must be recognized. The inclusion of the glenoid fossa position in the diagnostic assessment brings in as a major factor, an area of the craniofacial complex not normally taken into account in diagnosis of profile measurements. However, very little has been written⁽¹⁰⁻¹²⁾ concerning the direct measurement of the fossa position. Here we have used fossa summit point (F0) to assess the position of glenoid fossa.

The horizontal facial profile measurements depend on many factors one being, anteroposterior glenoid fossa position. Here, we found that Class II malocclusion has horizontal sella fossa distance (X) statistically more than compared to Class I normal occlusion. This indicates that glenoid fossa is located posteriorly in Class II

malocclusion than Class I normal occlusion. However, comparison between sagittal measurement of glenoid fossa between Class II division 1 and Class II division 2 malocclusions did not show significant difference ($p=0.1$). Also it was found that the horizontal sella fossa distance has a significant correlation with both the angles ANB and SNB (Table 2). SNB has negative correlation with X ($r=-0.5$) indicating that with decrease in SNB, X distance increases that is; cases with retrognathic mandible has increased horizontal sella fossa distance. These results are in agreement with those of Droel et al.⁽²⁾ and Baccetti T. et al,⁽³⁾ who found that horizontal glenoid fossa distance had a significant correlation with angle ANB and SNB.

In this study vertical sella fossa distance were compared among the groups; namely Class I normal occlusion, Class II division 1 and Class II division 2 malocclusions. There was no significant difference in vertical position of the glenoid fossa between the groups (Table 2), indicating that vertical sella fossa distance may not depend on sagittal relationships. Significant differences for vertical measurements of glenoid fossa were observed when compared between low and high mandibular plane angle groups (Table 4). The results showed that the vertical sella fossa distance is more in low mandibular plane angle than compared to high mandibular plane angle. This indicates that the individuals with low mandibular plane angle have glenoid fossa placed in relatively inferior positions; while individuals with high mandibular plane angle have fossa position more superiorly in the cranium. When ramus height were compared between low and high mandibular plane angle groups, the result showed that the group with low mandibular plane angle had increased ramus height than compared to high mandibular plane angle group (Table 4). Overall, a superiorly placed fossa gives the same net effect as a shortened ramus as seen in high mandibular plane angle. The above results are in accordance to Droel et al.⁽²⁾ and Baccetti T. et al.⁽³⁾ who found that vertical position of glenoid fossa and ramus height has a very significant correlation with mandibular plane angle.

Relation between morphology of the glenoid fossa and the mandible: Changes occurring in glenoid fossa morphology from infancy to childhood have been reported in previous studies.⁽¹³⁻¹⁵⁾ Experiments on rabbits^(5,6) revealed that condyles react differently for altered positions of glenoid fossa, indicating that shape of glenoid fossa affects the growth directions of condyle. Tanaka et al.⁽⁸⁾ have noted that the morphology of glenoid fossa has changed, particularly with respect to asymmetry, which has increased from ancient to modern periods probably attributing to food habits, environmental conditions etc.

In the present study, the results showed that there is no significant difference in the morphology of the glenoid fossa when compared between Class I normal

occlusion, Class II div1 and div2 malocclusions. However, when subjects were grouped based on their gonial angles (rectangular $<120^\circ$, average $126\pm 6^\circ$ and obtuse $>132^\circ$), a very significant correlation was found between articular eminence-clival plane and gonial angle as well as between sella nasion – articular eminence plane and gonial angle. It indicates that steep inclinations of the articulating surface of the glenoid fossa have rectangular shape of the mandible and flat configuration of the fossa was associated with obtuse shape of the mandible (Table 6). These results are similar to the study by Ingervall,⁽¹⁶⁾ wherein it was found that a marked height of articular tubercle was to be associated with rectangular form of the face with curved mandible and small height of the articular tubercle was found to be associated with triangular face having straight mandible. In an experimental study⁽⁷⁾ on rats it was found that the steep articular eminence inclination directed the growth of the condylar process more vertically. In a research study⁽⁴⁾ on humans it was found that steep inclination of the glenoid fossa is related to the reduced angle between the ramus and corpus whereas, flat fossa is analogously related to the obtuse mandibular angle.

Clinical implications: The goal of early Class II malocclusion (with retrognathic mandible) treatment is to correct developing skeletal imbalances by improving the maxillo- mandibular relationship before growth ceases with help of functional orthopaedic appliances.⁽¹⁸⁾ The desired treatment response in such cases is forward mandibular positioning by alteration in the amount and direction of growth at the condylar head. These appliances appear to stimulate the condylar growth and relocate the fossa position.⁽¹⁹⁻²⁴⁾ However; there are several reports⁽²⁵⁻²⁸⁾ indicating that there are no depictable contributions from glenoid fossa modifications for the correction of Class II malocclusions treated with functional orthopaedic appliances. If the direction of mandibular growth and the position of glenoid fossa can be modified, then with proper treatment mechanics it is possible to correct Class II cases by an anterior displacement of the fossa position and Class III cases by posterior displacement of the fossa. Mechanics aimed at superior –inferior fossa position changes likewise have limited success. If proper mechanics could be instituted it may be possible to correct high angle cases with open bite by an inferior displacement of the fossa position and low angle cases with deep bite by superior displacement of the fossa position. A final important consideration is that, cases in which fossa position deviates markedly, overcompensation will be necessary in another facial area to achieve a good orthodontic correction and will also ensure the stable treatment outcome.

Conclusions

1. Sagittally, Class II division1 and Class II division2 malocclusions show posteriorly positioned glenoid fossa.
2. Vertically, Class I normal occlusion, Class II division1 and Class II division2 malocclusions do not show significant difference in position of glenoid fossa.
3. Subjects with high mandibular plane angle have short ramus height and superiorly placed glenoid fossa whereas subjects with low mandibular plane angle have increased ramus height and inferiorly placed glenoid fossa.
4. Subjects with steep inclination of articulating surface of glenoid fossa has rectangular shape of the mandible whereas, a flat configuration of fossa has obtuse shape of the mandible.

References

1. Moyers R. handbook of orthodontics. 4th ed. Chicago-London-Boca Raton: Year Book medical publishers Inc; 1988:183-195.
2. Droel R and Isaacson R.J.: Some relationships between the glenoid fossa position and various skeletal discrepancies. *Am. J. Orthod* 1972;61,1:64-78.
3. Baccetti T, Antonini A, Franchi L, Tonti M and Isabella T: Glenoid fossa position in different facial types: a cephalometric study *Bri. J. Orthod* 1997;24:55-59.
4. Kantomaa T: The relation between mandibular configuration and the shape of the glenoid fossa in the human. *Eur. J. Orthod* 1989;11:77-81.
5. Kantomaa T: The effect of increased posterior displacement of the glenoid fossa on mandibular growth: A methodological study in the rabbit. *Eur. J. Orthod* 1984;6:15-24.
6. Kantomaa T: The effect of increased upward displacement of the glenoid fossa on mandibular growth. *Eur. J. Orthod* 1984;6:183-91.
7. Kantomaa T: The shape of the glenoid fossa affects the morphology of the mandible. *Eur. J. Orthod* 1988;10:249-254.
8. Tanaka. T, Morimoto. Y, Okabe. S, Kobayashi. S, Kito. S, Okumura. Y et al: Radiographic examination of the mandibular glenoid fossa in ancient and modern men. *Oral Dis.*2004 Nov;10(6):369-377.
9. Giuntini V, Toffol LD, Franchi L, Baccetti T. Glenoid fossa position in Class II malocclusion associated with mandibular retrusion. *Angle Orthod* 2008;78:808-12.
10. Bjork. A; Cranial base development. *Am. J. Orthod* 1955;41:198-225.
11. Agronin KJ and Kokich VG: Displacement of the glenoid fossa: A cephalometric evaluation of growth during treatment. *Am J Orthod Dentofac Orthop*1987;91:42-48.
12. Wylie WL: The assessment of anteroposterior dysplasia. *Angle Orthod* 1947;17:97-109.
13. Benjamin Moffett; "The morphogenesis of the temporomandibular joint." *Am J. Orthod* 1966;52,6:401-415.
14. Williams and Anderson; The morphology of the potential class III skeletal pattern in the growing child. *Am. J. Orthod* 1986;89,4:306-311.
15. Dibbets; Postnatal development of temporal part of the human temporomandibular joint: A quantitative study of skull. *Anat Anz* 1997;179,6:569-572.
16. Ingervall B: Relation between height of the tubercle of the temporomandibular joint and facial morphology. *Angle Orthod* 1974;44:15-24.
17. Cohlma, Ghosh J, Nanda RS, Sinha PK, Currier JF: Tomographic assessment of temporomandibular joints in patients with malocclusions. *Angle Orthod* 1996;66,1:27-36.
18. McNamara, Bookstein. F. and Shaughnessy.TG; Skeletal and dental changes following functional regulator therapy on classII patients. *Am J Orthod* 1985;88:91-110.
19. Pancherz H: Treatment of class II malocclusions by jumping the bite with the Herbst appliance: A cephalometric investigation. *Am. J. Orthod* 1979;76,4:423-442.
20. Wieslander: Intensive treatment of severe Class II malocclusions with a headgear-Herbst appliance in the early mixed dentition.*Am.J.Orthod*1984; 86,1:1-13.
21. Birkebaek L., Melson B. and Terp S.: A laminographic study of the alterations in the temporomandibular joint following activator treatment. *Eur. J. Orthod* 1984;6:257-266.
22. Woodside DG, Metaxas A and Altuna G: The influence of functional appliance therapy on glenoid fossa remodeling. *Am J Orthod Dentofac Orthop* 1987;92:181-198.
23. Baltromejus S: Effective temporomandibular joint growth and chin position changes: Activator versus Herbst treatment. A cephalometric study. *Eur. J. Orthod* 2002;24(6):627-637.
24. Pancherz H and Fischer S: Amount and direction of temporomandibular joint growth changes in Herbst treatment: A cephalometric long term investigation. *Angle Orthod* 2003;73:493-501.
25. Vardimon A.D, Stutzmann J.J, Graber T.M, Voss L.R and Petrovic A.G: Functional orthopedic magnetic appliance (FOMA) II – Modus operandi. *Am J Orthod Dentofac Orthop* 1989;95:371-387.
26. Popowich K: Effect of Herbst treatment on temporomandibular joint morphology: A systematic literature review. *Am J Orthod Dentofac Orthop* 2003;123(4):388-394.
27. Katsavrias EG: The effect of mandibular protrusive (Activator) appliances on articular eminence morphology. *Angle Orthod* 2003;73:647-653.
28. Katsavrias EG and Voudouris JC: The treatment effect of mandibular protrusive appliances on the glenoid fossa for classII correction. *Angle Orthod* 2004;74:79-85.