

Orthodontic management of impacted mandibular canine- A case report

Anadha N. Gujar^{1*}, MS Rani²

¹Senior Lecturer, KLES Institute of Dental Sciences, Bangalore, ²Professor, Dept. of Orthodontics, VS Dental College, Bangalore

*Corresponding Author:

Email: anandha@gmail.com

Abstract

The occurrence of impacted mandibular canine is very rare with several treatment options proposed for it. This case report describes the diagnosis and treatment of impacted mandibular canine by surgical exposure and orthodontic positioning of it.

Keywords: Boyd's modified window; Impaction; Lateral incisor extraction; Mandibular canine, surgical exposure.

Introduction

Impacted teeth are those that have not erupted during their normal time and remain in the jaws, surrounded completely or partially by hard or soft tissues. The incidence rate of 0.8 to 2.3% has been reported for impaction of maxillary permanent canines.¹ The occurrence of impaction and/or non-eruption of mandibular canines is unusual, with prevalence rates from 0.05 to 0.4%.²

The location of impacted mandibular canines are also more likely to be on the labial aspect of the dental arch than compared to maxillary canines,^{3,4} and the removal of impacted teeth routinely involves an intraoral surgical approach. There are several treatment options proposed for impacted mandibular canines including surgical removal, exposure and orthodontic alignment, transplantation and observation. Some authors believed that asymptomatic impacted teeth could be left in place, but in these patients a series of successive radiographs should be taken periodically.⁴

The purpose of this paper was to describe the diagnosis and treatment of impacted mandibular canine by surgical exposure and orthodontic positioning of it.

Diagnosis and etiology

A 17-year 4-month-old boy reported with a chief complaint of missing lower front tooth and wanted to get the treatment done for the same. He was physically healthy and had no history of medical or dental trauma. No signs or symptoms of temporomandibular joint dysfunction were noted at the initial examination.

The extraoral clinical examination (Fig. 1) showed a slight convex profile with acute nasolabial angle. There were no gross asymmetries. The intraoral examination (Fig. 1 and 2) showed an Angle's Class I malocclusion and Class I incisor relationship. The mandibular left canine was impacted. The maxillary arch showed mild space shortage of 2mm and the mandibular arch showed moderate crowding of 6 mm. There was increased overbite of 4mm and overjet of 4mm.

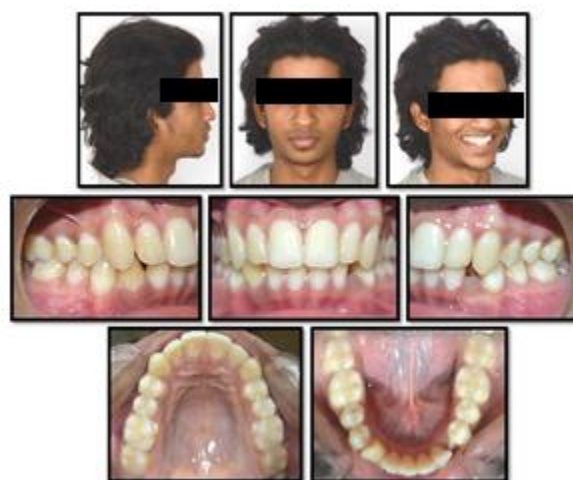

Fig. 1: Pretreatment extra-oral and intra-oral photographs

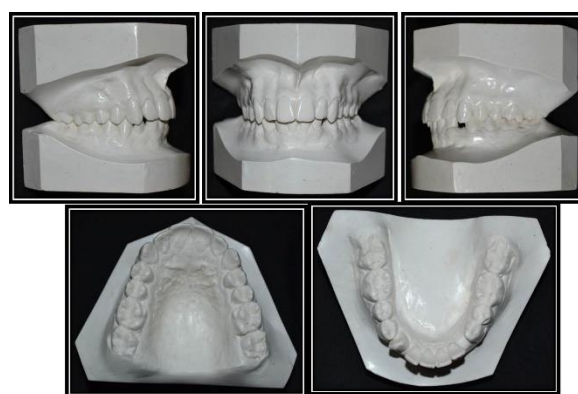

Fig. 2: Pretreatment models

Cephalometrically (Fig. 3), the patient had a Class I skeletal relationship (ANB angle: 4°) with mandibular retrognathism (SNA: 78°). A horizontal growth pattern was seen (SN.GoGn: 26°). Maxillary incisors were slightly proclined with the upper incisor at 6mm and 25° to NA. The lower incisors were proclined, with an IMPA of 106° and the lower incisor at 31° and 8mm

to NB, resulting in a reduced interincisal angle (Table 1). The panoramic radiograph showed all permanent teeth, including the maxillary and mandibular unerupted third molars. The mandibular left canine was impacted (Fig. 3). The labial position of the impacted mandibular canine was confirmed with the help of mandibular occlusal radiograph.

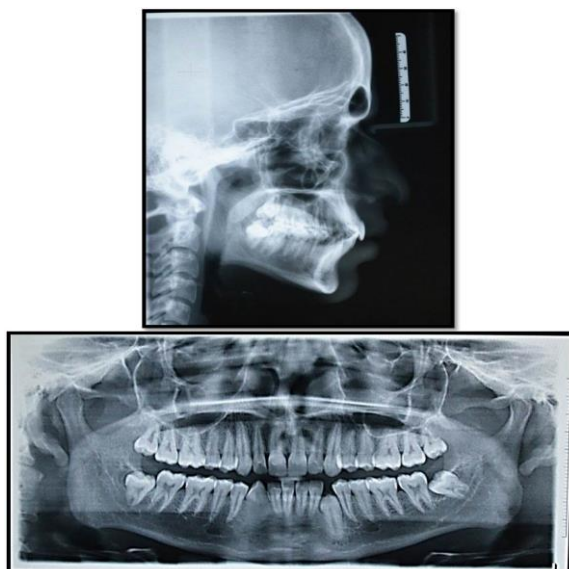


Fig. 3: Pretreatment lateral cephalogram and OPG

Table 1: Pre-and post-treatment cephalometric status

Measurement	Norm	Pre-treatment	Post-treatment
Maxillary components			
SNA(°)	82	82	82
A-Nperp (mm)	2	0	0
Mandibular components			
SNB (°)	80	78	79
Maxillomandibular relationship			
ANB (°)	2	4	3
Convexity (NAP) (°)	0	7	5
Facial growth pattern			
SN.GoGn (°)	32	26	26
Maxillary dentoalveolar components			
MxI.NA (°)	22	25	22
MxI-NA (mm)	4	6	4
Mandibular dentoalveolar components			
MdI.NB (°)	25	31	26
MdI-NB (mm)	4	8	6
IMPA (°)	90	106	101
Overjet (mm)	2.08	4	2

Overbite (mm)	2.87	4	2
Soft tissue components			
Nasolabial angle (°)	110	85	86
Upper exposure(mm)	1	2	2
Upper lip to E (mm)	-3±1	-1	-2
Lower lip to E (mm)	-2±1	0	1

Bayesian network analysis⁵ (Fig. 4 and Table 2) on orthopantomograph tracing was done to evaluate the possible relationships among the variables considered for diagnosis and treatment of impacted left mandibular canine. The favorability of the impacted canine to erupt into the arch was analysed and it was found to be good.

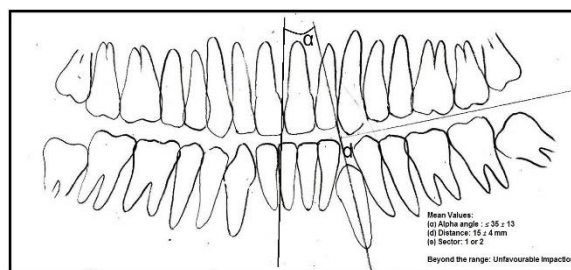


Fig. 4: Bayesian network analysis

Table 2: Bayesian network analysis

Parameters	Normal	Pretreatment
Alpha Angle	$\leq 35 \pm 15^\circ$	20°
Distance	$\leq 15 \pm 4$ mm	8mm
Sector	3	3

The treatment objectives

The initial treatment objective was to disimpact the mandibular left canine and bring it into alignment. The orthodontic procedure would align the maxillary and mandibular dental arches. Our treatment objective also included maintaining Class I skeletal and dental relationship with a pleasing profile and to improve the smile arc.

Treatment alternatives

Three alternatives were presented to the patient.

1. Extraction of mandibular first premolars. The two main advantages of this treatment option were the efficiency to bring the impacted mandibular left canine into alignment in the arch with space created by extraction of premolars. Nevertheless, mandibular first premolars extraction treatment would not resolve the arch length discrepancy but would end up in excess space. It also would not achieve ideal incisal relationship and might even worsen the profile, resulting in excess of overjet.
2. Extraction of the mandibular left first premolar. This would address the correction of canine

relationship on both the sides. The non-extraction treatment plan of maxillary arch, would help in good arch alignment by gaining space for it through arch widening. However, the facial and smile esthetics would not be optimized.

3. Extraction of mandibular left lateral incisor. This would create sufficient space to bring the impacted mandibular left canine into alignment and occlusion. The arch-length deficiency in mandibular arch would be resolved. This would enhance both the profile and the smile esthetics by achieving ideal incisal and canine relationship.

The third treatment option was adopted because it would optimize facial and smile esthetics. Co-operation and stability issues were discussed with the patient.

Treatment progress

Both the esthetic concerns and the patient's desires called for a challenging solution for an unusual impacted mandibular canine treatment to align into its ideal position in the arch. The preoperative orthodontic preparation was performed with conventional 0.022-in MBT appliances. The initial alignment and leveling was achieved with 0.016" NiTi archwires. The impacted mandibular canine was surgically exposed and bonded during the 0.018' AJ Wilcock archwire stage. The impacted mandibular canine was surgically exposed with Boyd's modified window approach labially, as it was less invasive than raising a full thickness flap.⁶ The mandibular left lateral incisor was extracted immediately after bonding the Begg bracket on the exposed tooth (Fig. 5). The ligature wire was tied from the bonded attachment on the canine. Surgical exposure was carried out under local anesthesia. The window approach closely simulated the closed eruption technique. The alignment and leveling was completed with 0.019 X 0.025-in NiTi and 0.019 X 0.025-in stainless steel rectangular archwires. Elastic traction was given from the ligature wire attached to the Begg bracket on the exposed crown of the impacted mandibular left mandibular canine to the 0.019 X 0.025 Stainless steel mandibular arch wire. In order to bring the mandibular left canine in the arch, a overlay ("Piggy Back") wire of 0.014 NiTi, over the 0.019 X 0.025 Stainless steel mandibular arch wire was engaged on the Begg bracket of the mandibular left canine. The overlay wire extended from second premolar on right side to the second premolar on the left. As the mandibular lower left canine started erupting, vertical elastics were given from it to the maxillary canine of the same side. After the mandibular left canine was brought into the arch, the Begg bracket on it was replaced with 0.022-inch MBT bracket (Fig. 6). Settling was done with 0.014" Stainless steel archwire. This entire orthodontic procedure took 18 months.

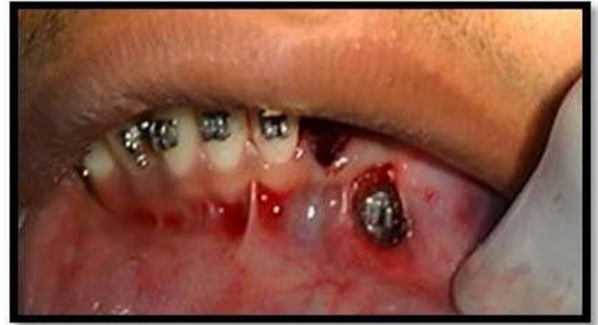

Fig. 5: Surgical exposure of impacted tooth and bonding of bracket

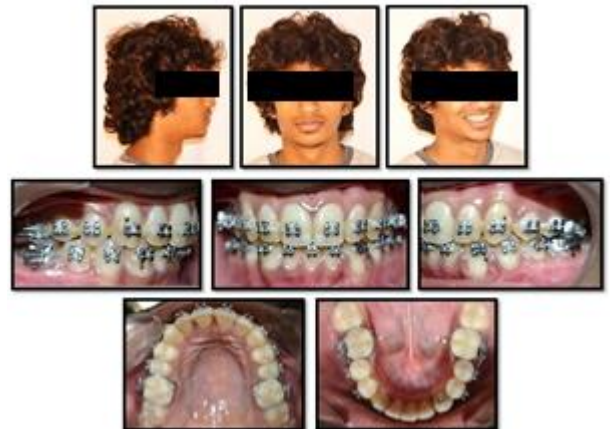

Fig. 6: Mid treatment extra-oral and intraoral photographs

Treatment results

The facial esthetic was improved with better lip support and improved nasolabial angle (Fig. 7). The smile was enhanced and the consonant smile arc was achieved. Intraorally, ideal overjet and overbite was achieved with Class I molar and canine relationship.

The post treatment panoramic radiograph (Fig. 8) showed good overall root parallelism and lack of root resorption. Post treatment lateral Cephalogram (Fig. 8) showed satisfactory improvement in ANB angle by 1° and improvement in mandibular position (SNB: 79°). The position of upper and lower incisors were improved, upper incisor at 22° and 4mm to NA and the lower incisor at 26° and 6mm to NB with an IMPA of 101°. A favorable profile change in facial profile contour angle was seen.

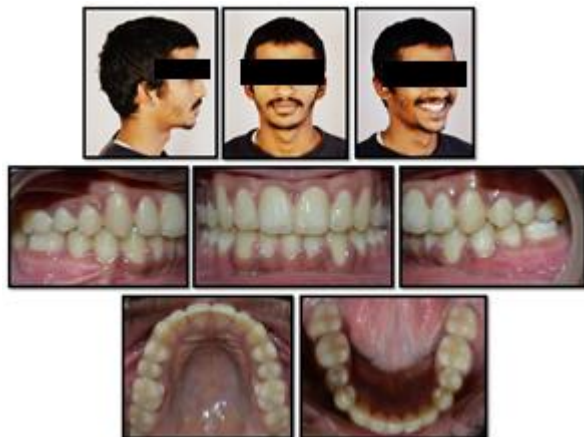

Fig. 7: Post treatment extra-oral and intra-oral photographs

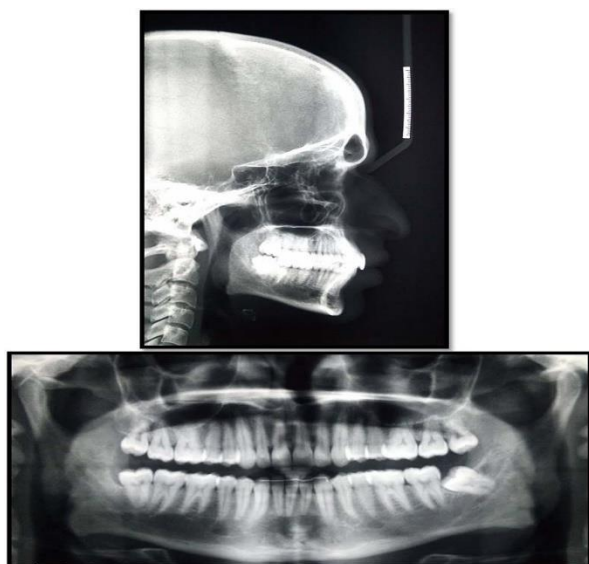


Fig. 8: Post treatment lateral cephalogram and OPG

Discussion

The most important step in the management of impacted teeth is the diagnosis and localization of impacted teeth. Failure of eruption of the mandibular canine is an unusual event.^{4,7} There are limited number of studies revealing the frequency of occurrence of mandibular canine impactions and is regarded as a much rarer phenomenon.⁴

Delayed tooth eruption can cause necrosis of the pulp, ankylosis and external apical root resorption. It is difficult to predict when resorption will start. Thus, all impacted teeth should be regarded as having a high risk of external apical root resorption or damage to the adjacent tooth. So, radiographic examinations should be used to monitor these risks. Commonly, orthopantomograph is used.^{8,9}

Surgical extraction appears to be the most favored treatment for impacted and migrated mandibular canines, rather than a heroic effort to bring the tooth back to its original place.¹⁰ In our case, the canine was

in favorable position, and since canines are considered important keystones in the dental arch, we decided to orthodontically bring it into its ideal position.

Hahn, first introduced the concept of removing the lower incisor for the purpose of relieving the crowding.^{11,12} In certain clinical situations, the therapeutic aids must be adjusted to individual patient needs, even when the achieved final occlusion is not ideal as the lower incisor extraction is not a standard approach to symmetrically treating most malocclusions.^{10,11} In our case, we extracted the mandibular left lateral incisor. This helped in creating sufficient space to bring the impacted mandibular left canine into alignment and occlusion. The remaining excess space was utilized in improving the IMPA by 5°. The arch-length deficiency in mandibular arch was resolved. The maxillary teeth were retracted by 2mm and slight arch widening took place. This helped in maintaining ideal overjet. A study done was done to evaluate the post-retention stability of mandibular incisors where they have reported that it is logical alternative to remove one or more mandibular incisor in patients with severely crowded mandibular arches, which may allow for increased stability of the mandibular anteriors without continued retention.^{12,13}

All the advantages and disadvantages of surgical and orthodontic repositioning as well as the risks (including that of being unable to achieve the desired goals) and the need for good cooperation were discussed, and these were understood and accepted by the patient.

Conclusion

Our results showed a satisfactory improvement in ANB angle and a pleasing external soft tissue profile was achieved. Ideal skeletal and dental relationships were obtained. The combined effect of surgical exposure of impacted mandibular canine and orthodontically correcting its positing was instrumental in reestablishing the major components of a balanced smile for this patient, whose main concern was his unpleasant smile.

References

1. Thilander B, Myrberg N. The prevalence of malocclusion in Swedish schoolchildren. *Scan J Dent Res* 1973;81:12-20.
2. Ellis E, McNamara JA. Components of adult Class III malocclusion. *J Oral Maxillofac Surg*.1984;42:295-305.
3. Brown LH, Berrkman S, Cohen D, Kaplan AL, Rosenberg MA. A radiological study of the frequency and distribution of impacted teeth. *J Dent Assoc S Afr*. 1982;37:627-30.
4. Fonseca JR. *Oral and Maxillofacial Surgery*. Philadelphia: W.B. Saunders, 2002;1:342-71.
5. Monika R, Mahesh G, Nikhi M. Bilateral Mandibular Canine Impaction: A Rare Case Report. *Journal of Oral Health and Community dentistry*. 2009;3(2):38-41.
6. Michele N, Aldo C, Roberto R, Tiziano B, Pierpaola C, Giovan PP. Factors affecting the clinical approach to impacted maxillary canines: A Bayesian network

- analysis. *Am J Orthod Dentofacial Orthop.* 2010;137(6):755-762.
6. Boyd RL. Clinical assessment of injuries in orthodontic movement of impacted teeth. II. Surgical recommendations. *Am J Orthod* 1984;86:407-18.
 7. Camilleri S, Scerri E. Transmigration of mandibular canines – A review of the literature and a report of five cases. *Angle Orthod* 2003;73:753-62.
 8. Kavadia-Tsatala S, Tsalikis L, Kaklamanos EG, Sidiropoulou S, Antoniadis K. Orthodontic and periodontal considerations in managing teeth exhibiting significant delay in eruption. *World J Orthod.* 2004;5:224-229.
 9. Peck S. On the phenomenon of intraosseous migration of nonerupting teeth. *Am J Orthod Dentofacial Orthop.* 1998;113:515-517.
 10. Nagaraj T, Umashree N. Transmigration of mandibular canine. *e-Journal of Dentistry.* 2011;1(3):72-74.
 11. Canut JA. Mandibular incisor extraction: Indications and long term evaluation. *Eur J Orthod* 1996;18:485-9.
 12. Vignesh T, Senthil Kumar K. P, Senthil Kumar T. Mandibular incisor extraction in orthodontics: A systematic review. *Journal of Indian Academy of Dental Specialist Researchers.* 2014;1(1);1-5.
 13. Riedel RA, Little RM, Bui TD. Mandibular incisor extraction-postretention evaluation of stability and relapse. *Angle Orthod* 1992;62:103-16.