

Content available at: <https://www.ipinnovative.com/open-access-journals>

IP Indian Journal of Orthodontics and Dentofacial Research

Journal homepage: <https://www.ijodr.com/>

## Short Communication

# Natural head positioner (NHP) – A guiding device for diagnosis and treatment planning in orthodontics

Pravinkumar S Marure<sup>1</sup>, Trupti Nakhate<sup>1\*</sup>, Nikhil Mukhedkar<sup>1</sup>

<sup>1</sup>Dept. of Orthodontics and Dentofacial Orthopedics, Maharashtra Institute of Dental Sciences & Research (Dental College), Latur, Maharashtra, India



### ARTICLE INFO

#### Article history:

Received 02-05-2024

Accepted 17-05-2024

Available online 21-06-2024

#### Keywords:

orthodontics  
fluid level device  
and natural head posture

### ABSTRACT

**Introduction:** The Natural head position in orthodontics is a highly precise, reliable, and reproducible external reference position that is used in clinical diagnosis and research.

**Materials and Methods:** The physics concept that states that the fluid levels of a liquid's surface is horizontal in a non-accelerating fluid system (hydrostatic). The fluid surface has a tendency to align with gravity at an angle of 90 degrees. The two locations in a fluid level where the fluid, glass, and air converge will naturally aim for the same level similar to gravity. This device was designed to capture the head posture of the patient in its natural state before clinical extra-oral photography and head film exposure.

**Conclusion:** A simplified fluid-level device in conjunction with a standardized procedure and cephalometric radiography yielded a consistently determined and recorded value. A simple technique for accurately recording NHP and recreating it.

This is an Open Access (OA) journal, and articles are distributed under the terms of the [Creative Commons Attribution-NonCommercial-ShareAlike 4.0 License](https://creativecommons.org/licenses/by-nc-sa/4.0/), which allows others to remix, tweak, and build upon the work non-commercially, as long as appropriate credit is given and the new creations are licensed under the identical terms.

For reprints contact: [reprint@ipinnovative.com](mailto:reprint@ipinnovative.com)

## 1. Introduction

According to Broca (as described in Solow and Tallgren in 1971), "when a man is standing and his visual axis is horizontal, his position of the head is oriented in natural position.<sup>1</sup> Downs was the first to introduce natural head position into Orthodontics in 1956, followed by Moore's in 1958.<sup>2,3</sup> Every person has a tendency to orient their head in space so that, when they look at an object on the horizon that is infinitely far away, it returns to a repeatable position.<sup>4</sup> In the past, anthropologists, artists, and anatomists all have studied the human face using NHP.

Solow and Tallgren in 1971 introduced a technique for the registration of NHP by asking the patients to stand straight in an erect position "orthoposition" by looking into a mirror kept at the distance away from the patients.<sup>5</sup> This helps patients to stand straight to NHP by establishing the

visual axis of the patient. NHP can be established by using photography techniques, fluid level devices, inclinometers or cephalometry.<sup>6-9</sup>

This device helps to maintain proper position of the head, face and occlusal plane which is necessary for the accurate diagnosis and treatment planning. NHP becomes a popular reference due to its inter and intra-observer reliability.

## 2. Device

The physics concept that governs fluid levels states that a liquid's surface is horizontal in a non-accelerating fluid system (hydrostatic system) (Figure 1). The fluid surface tends to coincide with gravity at an angle of 90 degrees. Both areas in the fluid level where the liquid, glass, and air converge will naturally reach for the same level of gravity. A round protractor with an adjustment screw is fastened to a horizontal scale to measure head angulation and enable for variable angulation (Figure 3). The liquid level (Figure 2)

\* Corresponding author.

E-mail address: [nakhate.trupti30@gmail.com](mailto:nakhate.trupti30@gmail.com) (T. Nakhate).

is fastened to the horizontal scale's center. As a reference for the proper placement of the bubble between them, two vertical black lines are drawn on the tube (Figure 2). The proper natural head position is shown by the center of position of the bubble.

The horizontal scale is where the earpiece component is attached (Figure 4). This aids in fixing the device to the patient's ear. The apparatus is designed to capture the patient's normal head position before clinical extraoral photography and head film exposure. With the use of an earpiece attachment, the device was attached to the subject's ear and the standard cephalometric process was conducted with minimal technical modifications.

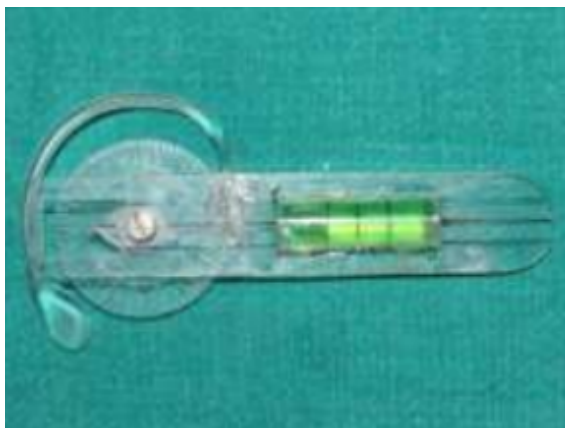

Figure 1: Modified NHP device



Figure 2: Fluid level

### 3. Procedure for using NHP

The following procedures are involved in taking an NHP radiograph: Step 1: An earpiece attachment is used to secure the gadget to the patient's ear. Step 2: The patient is given instructions to stand upright, place his or her arms by their sides, and gaze off into the distance. This step of the process is an attempt to regulate the overall body alignment and visual target. Step 3: It involves positioning the patient in the cephalometric head holder, inserting the NHP device on

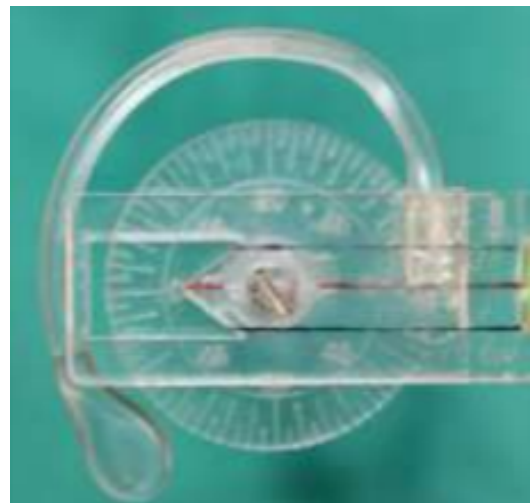

Figure 3: Round protractor with adjustment screw for angulations.

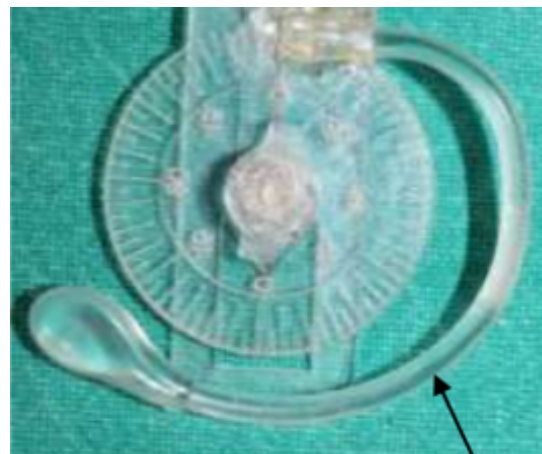

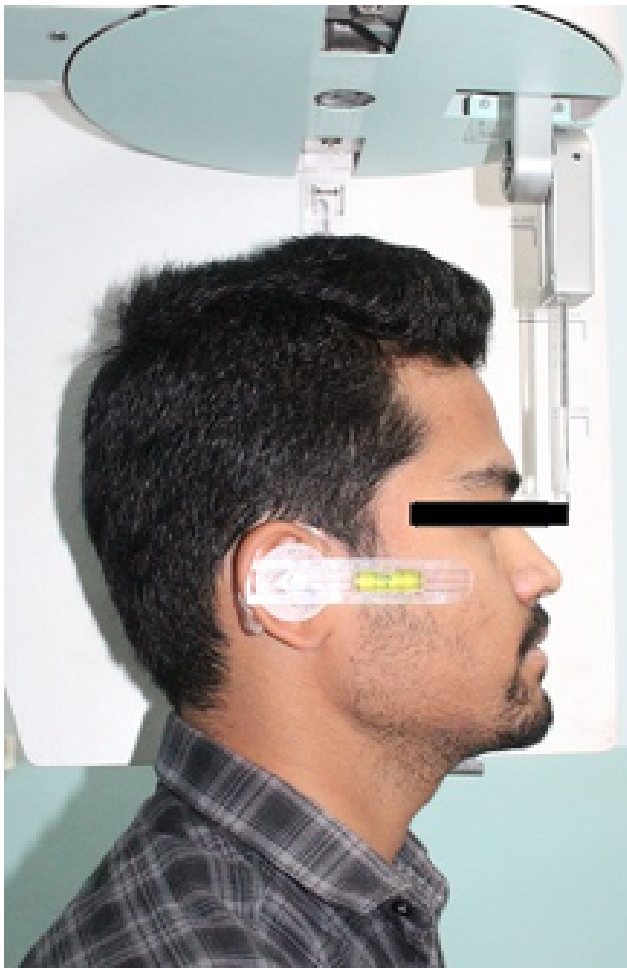
Figure 4: Earpiece attachment

one side of the patient's ear and the one side ear rod into the patient's ear. (Figure 5)

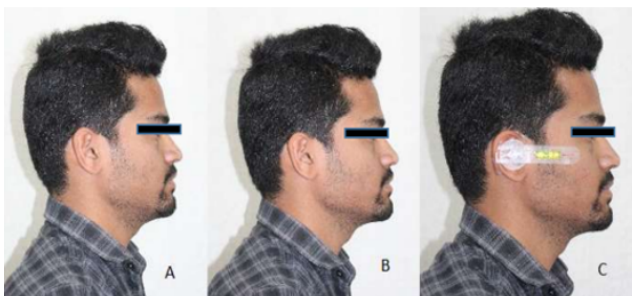Step 4: Adjust the angulation to 0 degrees after rotating the fluid level on the pivot until the bubble is in line with the FH plane in the middle of the rod (Figure 5). Step 5: An assessment of NHP's reliability is conducted. The patient is prepared for radiography if close observation demonstrates that head-position recording using this technique consistently brings the bubble back to its center of alignment with the rod. (A, B, and C in Figure 6)

### 4. Advantages of NHP device

1. Easy to use, requires minimal instructions, and can be easily trained to personnel or to patients.
2. Orienting patients to NHP takes time and is especially challenging for young patients; it is needed for specialized radiography setups and trained personnel.



**Figure 5:** Patient with head holder, one ear rod and NHP device



**Figure 6:** A,B:Photographs without NHP with different head position; C: With NHP device achieved stable head position

3. Using this method does not impede the regular practice of cephalometric radiography in any way.
4. Once the patient is in the cephalometric head holder, a technique for recording and reproducing NHP has been developed.
5. It is proposed that meaningful data regarding correlations between NHP as assessed by
  - (a) Skeletodental morphology.
  - (b) Growth alterations.
  - (c) Treatment outcomes, and
  - (d) Stability or prognosis following orthognathic or orthodontic surgery.
    - i. Beneficial for extraoral photography research studies with various head angulations.
    - ii. Helpful in obtaining an upright head position in extraoral photography without placing the device on one side of the face without any inference. (6C).
    - iii. Helpful in extraoral radiography where various head angulations are required, such as transcranial, trans pharyngeal, and transorbital radiography.

## 5. Discussion

Neuromuscular mechanisms that regulate cranial position seem to be affected by regular processes like breathing and eating. Research has recently focused primarily on the potential impact of extrinsic factors that may influence cranial position in a way that may be connected to features of particular malocclusions. The function of head position in the development of the facial skeletal system was investigated by Solow and Tallgren.<sup>5,10,11</sup> A soft-tissue stretching theory proposed by Solow and Kreiborg suggested a potential causal link between head position and craniofacial morphology.<sup>12</sup> According to Ferrario et al., the difference between the Frankfort horizontal and the real horizontal in men was 5° when seated and 13° when standing.

This indicates that when people stand, they hold their heads more upright. Furthermore, Preston et al. showed that, in comparison to their average ortho head position, 23 out of 30 males maintained an extended head posture of 2.01° when walking.<sup>13</sup> The dilemma of what position to consider as an ideal head position arises from these variations in the head position in different body situations. Orhan recommended selecting the posture that is most frequently employed among the limited options surrounding the stationary natural head position.<sup>14</sup> Using a cinefluorographic approach, Cleall et al. showed how the head briefly extends when swallowing.<sup>15</sup> Due to the high radiation levels, this technique guarantee in routine head position assessments was limited.

Thus, it is ideal to have a dynamic, non-invasive way of assessing head posture. An inclinometer was used by Murphy et al. to construct this device, which measures the natural head position dynamically.<sup>16</sup> They demonstrated that this equipment was suitable for dynamic assessment of head posture, as did Preston et al. But the instrument's cranial section, which weighed 110 g, could only detect the head's sagittal tilt. Therefore, one goal of this work was to build a lightweight device that measures the head's lateral and sagittal tilt. To prevent altering the natural head position, we made every effort to keep the instrument's head section as small and light as possible.

The Murphy et al. device's cranial component had no discernible impact on the natural head posture.<sup>16</sup> Just 21.6 g, or less than a quarter of the total weight of the prior system, made up the cranial part of the device employed in this investigation. We therefore concluded that there was little to no change in the head posture. In addition, we made an effort to position the wires and inclinometers beyond the subject's line of sight. The cables were aimed from behind the neck so as not to cause any discomfort, and the inclinometers were positioned on the arms of the spectacles without making contact with the temple. Murphy et al. also evaluated whether the glasses could be consistently set in the same spot on different occasions and showed that the inclinometer could be positioned rather precisely.

As such, this variable was not investigated in this study; rather, the results of Murphy et al. were applied. In addition to establishing the natural head position using self-balance and mirror positions, the study aimed to evaluate the determining the same position in the cephalostat using lateral cephalograms, as well as the clinical usefulness of this instrument and its ability to transfer this position to the cephalostat. Murphy et al. assessed how well the inclinometer assessed natural head position dynamically and suggested that it could be used to obtain cephalograms showing natural head position. However, this was not evaluated in their study. One of its differences was the axis that could be measured by the existing equipment.

While the prior devices only assessed changes in the sagittal plane, the one utilized in this study was able to determine both the roll and pitch of the head. Therefore, typical posteroanterior cephalograms might also be taken with the current technique. The head position is recorded outside of the radiograph room, avoiding psychological effects that could affect head position. Secondly, the high level of sensitivity of the inclinometer allowed for a highly precise transfer of the recorded head position to the cephalostat. These two benefits come from using an inclinometer for transferring the recorded head position. The hyoid bone is the attachment point for two major muscle groups: the suprahyoid and infrahyoid.

During deglutition, the digastric muscles enlarge the oropharynx's anteroposterior dimension, while the stylohyoid muscle and the digastric belly work in tandem

to stop the regurgitation of food after swallowing.<sup>17</sup> The suprahyoid muscles actively contribute to the maintenance of cranial balance in addition to depressing the mandible by pressing onto a fixed hyoid bones platform. The larynx, pharynx, tongue, and hyoid bone are all suspended by the suprahyoid muscles in turn. Given that these muscles attach at or close to the mandibular symphysis, all soft tissue structures may migrate to impinge on the oropharyngeal airway if the hyoid bone passively follows the motions of the chin.

The stylohyoid ligament and the fibrous mylohyoid raphe function as "rigging lines," limiting the range of motion that the hyoid bone can make. It is challenging to measure the hyoid bone precisely using cephalometric techniques, but with some restrictions, conclusions about the typical hyoid location can be drawn.<sup>18,19</sup> The hyoid bone glides forwards during cranial flexion and backward during cranial extension, although it primarily remains level during mandibular opening and only moves slightly rearward.<sup>20</sup> The apparatus designed to capture the patient's normal head position before clinical extra oral photography and head film exposure. With the use of an earpiece attachment, the device was affixed to the subject's ear and the standard cephalometric process was conducted with minimal technical modifications.

## 6. Conclusions

This method is reliable, comfortable and standardized with a basic fluid-level instrument helps to maintain NHP of the patient thus establish proper diagnosis and treatment planning. This technique is also useful for extra oral photography of the patients undergoing orthodontic treatment.

## 7. Source of Funding

None.

## 8. Conflict of Interest

None.


## References


1. Broca M. Sur les projections de la tête, etsur un nouveau rocède de cephalometric. Bull de la Societe D Anthropologie de Paris. *Angle Orthod.* 1862;3:514–44.
2. Downs WB. Analysis of the dentofacial profile. *Angle Orthod.* 1956;26(4):191–212.
3. Moorrees C, Kean R. Natural head position, a basic consideration for the analysis of cephalometric radiographs. *Am J Phys Anthropol.* 1958;16:213–34.
4. Graber LW, Vanarsdall RL, Vig KW. Orthodontics: Current principles and techniques. 5th Edn.. vol. 31. Elsevier publications;.
5. Solow B, Tallgren A. Natural head position in standing subjects. *Acta Odontol Scand.* 1971;29(5):591–607.
6. Claman L, Patton D, Rashid R. Standardized portrait photography for dental patients. *Am J Orthod Dentofacial Orthop.* 1990;98(3):197–

- 205.
7. Lundstrom A, Lundstrom F, Le Bret LM, Moorrees CF. Natural head position and natural head orientation: basic considerations in cephalometric analysis and research. *Eur J Orthod.* 1995;17(2):111–20.
  8. Showfety KJ, Vig PS, Matteson S. A simple method for taking natural head position cephalograms. *Am J Orthod.* 1983;83(6):495–500.
  9. Usumez S, Orhan M. Inclinator method for recording and transferring natural head position in cephalometrics. *Am J Orthod Dentofacial Orthop.* 2001;120(6):664–70.
  10. Solow B, Tallgren A. Dentoalveolar morphology in relation to craniocervical posture. *Angle Orthod.* 1977;47(3):157–64.
  11. Solow B, Tallgren A. Head posture and craniofacial morphology. *Am J Phys Anthropol.* 1976;44(3):417–35.
  12. Solow B, Kreiborg S. Soft tissue stretching: A possible control factor in craniofacial morphogenesis. *Scand J Dent Res.* 1977;85(6):505–7.
  13. Preston CB, Evans WG, Todres JI. The relationship between ortho head posture and head posture measured during walking. *Am J Orthod Dentofacial Orthop.* 1997;111(3):283–7.
  14. Orhan M, Goyenc YB. Determination of natural head position with “target on the mirror” technique. Konya, Turkey: Selçuk University Health Sciences Institute; 1996.
  15. Cleall JF, Alexander WJ, McIntyre HM. Head posture and its relationship to deglutition. *Angle Orthod.* 1966;36(4):335–50.
  16. Murphy KE, Preston CB, Evans WG. The development of an instrumentation for the dynamic measurement of changing head posture. *Am J Orthod Dentofacial Orthop.* 1991;99(6):520–6.
  17. Goss C. Anatomy of the Human Body. 28th edn. Philadelphia: Lea and Febiger; 1967.
  18. Graber LW. Hyoid changes following orthopedic treatment of mandibular prognathism. *Angle Orthod.* 1978;48(1):33–8.
  19. Stepovich ML. A cephalometric positional study of the hyoid bone. *Am J Orthod.* 1965;51(12):882–900.
  20. Ingervall B, Carlsson GE, Helkimo M. Change in location of hyoid bone with mandibular positions. *Acta Odontol Scand.* 1970;28(3):61–61.

### Author biography

**Pravinkumar S Marure**, Professor  <https://orcid.org/0000-0001-5498-5405>

**Trupti Nakhate**, Post Graduate Student  <https://orcid.org/0009-0000-1964-8745>

**Nikhil Mukhedkar**, Post Graduate Student  <https://orcid.org/0009-0001-7216-8406>

**Cite this article:** Marure PS, Nakhate T, Mukhedkar N. Natural head positioner (NHP) – A guiding device for diagnosis and treatment planning in orthodontics. *IP Indian J Orthod Dentofacial Res* 2024;10(2):138-142.