



Case Report

Rapid maxillary expansion appliance in correction of unilateral skeletal crossbite in an adult female patient: A case review

Sanjay Kumar^{1*}, Neal Bharat Kedia²

¹Dept. of Dentistry (Orthodontics), Indira Gandhi Institute of Medical Sciences, Patna, Bihar, India

²Dept. of Orthodontics, Buddha Institute of Dental Sciences & Hospital, Patna, Bihar, India



ARTICLE INFO

Article history:

Received 05-05-2024

Accepted 23-05-2024

Available online 21-06-2024

Keywords:

Rapid maxillary expansion appliance (RME)
bonded RME
adult patient
pregnancy
ENT problems

ABSTRACT

The case was treated with bonded rapid palatal appliance successfully in adult female from Nepal. The occlusion and her smile have improved satisfactorily. The other associated sign and symptoms such as recurrent rhinitis and breathing problem also improves after this treatment. Few clinical problems that arose during the treatment were successfully addressed as well. At the end of the treatment, patient was very happy and satisfied. Though her age was not in favour of application of RME treatment, but careful examination of diagnostic aids helped us in arriving at correct treatment planning and her treatment with RME.

This is an Open Access (OA) journal, and articles are distributed under the terms of the [Creative Commons Attribution-NonCommercial-ShareAlike 4.0 License](https://creativecommons.org/licenses/by-nc-sa/4.0/), which allows others to remix, tweak, and build upon the work non-commercially, as long as appropriate credit is given and the new creations are licensed under the identical terms.

For reprints contact: reprint@ipinnovative.com

1. Introduction

Rapid maxillary expansion (RME) is an orthodontic - orthopaedic appliance that involves the separation of the mid-palatal suture and movement of the maxillary shelves away from each other. This is the best example of true orthopaedic expansion appliance. Mid-palatal suture opening during orthodontic treatment with rapid maxillary expansion (RME) amounted to 12-52.5 % of the total screw expansion.¹ After the treatment with RME, the midpalatal suture seemed to be recalcifies, so the expansion of the mid-palatal suture remains stable, usually mid-palatal suture opens more of triangular than parallel.^{2,3} The effect on the nasal cavity dimensions after RME seems to be apparent and indicates an enlargement between 17% and 33% of the total screw expansion. The complex sutures of the maxillo-facial regions are also affected upon expansion with lesser effects.³ RME seems to be associated with an increase in the nasal cavity volume in the short and in

the long-term study done by author by means of using recent methods of acoustic rhinometry, three-dimensional radiography and digital photogrammetry shows the similar findings.⁴ Prevalence of maxillary transverse deficiency is most common in deciduous and mixed dentition (8-23%), compared to adult (<10%) patients.⁵ Many studies have shown that maxillary transverse constriction mainly may play a role in the etiology of more severe breathing disorders such as obstructive sleep apnea (OSA) in growing subjects.^{4,6,7} Hence early diagnosis and Orthodontic treatment with RME is able to reduce the symptoms of OSA and also improve polysomnographic variables.⁸

2. Case History

A female patient aged 18 yrs, old referred from the Department of ENT, IGIMS, Patna, Bihar, to the Department of Dentistry, unit of Orthodontics for consultation in the month of December 2018. She complained of deviated face, crooked teeth and difficulty in chewing, TMJ pain & clicking etc. Past medical and dental

* Corresponding author.

E-mail address: devasthanam786@yahoo.co.in (S. Kumar).

history: She went for treatment of chronic cough and cold with nasal blockage for that she was taking medicine from many years but there was no improvement in the conditions hence, she came to Dept. of ENT, IGIMS, Patna, Bihar for consultation. She visited to the local dental surgeon for malocclusion correction, but they declined to treat her problems and advised to visit the higher centre for the same. On extra oral finding: the right side of the face was depressed with dull facial expression. Intra -oral finding: The right quadrant of the teeth was in complete crossbite. There was wear facets on the upper teeth due to improper occlusion.

2.1. Diagnostic aids recommended

The plaster model for the upper and lower arch was prepared. The extra oral facial and intra oral photographs were taken. The x-rays taken were lateral cephalometry, OPG-pan and maxillary occlusal view for diagnosis. Findings of the X-rays: OPG-pan: shows deviated nasal septum and missing lower left third molar. The lateral cephalogram tracing for transverse /width of the face shows reduced width on the right side of the face in comparison to left side of the face point and X-ray maxillary occlusal view shows: mid-palatal suture was not fused with hypocalcified section parasagittal. On model analysis reduced palatal width on the right side in comparison to left side was found while measuring from mid-palatine raphe.

2.2. Objective of the treatment

The correction of malocclusion and facial asymmetry including, TMJ clicking etc besides to alleviate her problem of recurrent cough and cold and nasal blockage and difficulty in breathing.

1. As per investigations we have planned for rapid maxillary expansion appliance with fixed orthodontic appliance if required for detailing occlusion. The other options discussed with patients and her parent were as follows.
2. Modified Lefort -1 surgery with palatal expansion followed by orthodontic treatment.
3. ENT surgery for DNS correction and maxillary expansion as per orthodontist plan.

The signed written consent form for treatment was taken from patient & parents.

Her parent was explained of pros and cons of treatment like relapse after treatment, appliance might not give desired results, long duration treatment time (minimum of two years) and needs patient's compliance. The consent paper was signed. The good thing about patient and her guardian that they were very co-operative and determined for treatment we proposed.

2.3. Treatment plan

1. Fabrication of RME appliance and activation of appliance. General guideline is during active expansion it is useful to know how much of the screw thread is still available & when the limit is near, so that it is not completely exhausted, the halves of the appliance must not be allowed to disengage, that would lead to collapse. At the cessation of active expansion, the patient enters the fixed retention phase & is required to attend only for check-ups once each month. During this phase, it should be unnecessary to ligate (or) apply cold curing acrylic to lock the screw as the angular thrust creates sufficient friction to hold it. the fixed appliance (RME) is removed after 3months & replaced with a removable retainer.
2. If required after removal of RME, fixed straight wire appliance was given followed by retention.

2.3.1. Fabrication of RME appliance

Appliance was fabricated in Department of Dentistry (Orthodontics), IGIMS, Patna, Bihar. Occlusal wire frame was made on the working cast. The expansion screw struts were adapted on the occlusal wire frame works and stabilized as shown in the (Figure 1 a,b&c). Soldering was done. Bonded plate was made with self-cure acrylic. The acrylic design was polished and made ready for insertion in the oral cavity. The bonded RME appliance was fixed with the help of glass-ionomer cements as shown in the (Figure 2a,b).




Figure 1: a: Manipulation of RME with occlusal wire frame work; b: Expansion screw struts moulded for adaptation with wire frame work; c: RME in positioned in model for soldering

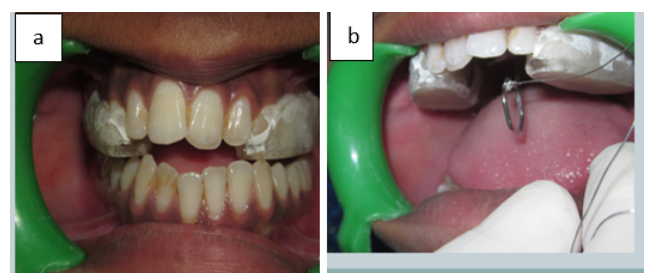


Figure 2: a: Bonded type RME appliance fixed on the upper teeth (post- expansion condition); b: RME Appliance ready for activation

2.3.2. Appliance activation was planned as per requirement

Patient was called after one day after bonding the RME appliance for activation for explaining for her/parent how to do activation. Day one: one rotation was given. She stated complain of pain after one hour. Initial plan was that they will be explained for self -activation and will be sent to native place, but it was cancelled as per my advice. Day two: Screw was given two turns; she didn't complain of pain much. Day fourth: two turn was given, she was comfortable. Day 06: two turn was given; it was observed that right side of the maxillary was separating very fast.

08 days: two turn was given the desired expansion was achieved the right-side teeth were out off occlusion.

Days 10: two turn was given for over expansion.

Days 12: one turn given and the appliance was locked. Patient was called after three months.

Follow-up and treatment outcomes: patients came after four months with smiling face and gave history that no recurrent cough and cold, nasal blockage and have marked Improvement in the breathing pattern. There was no TMJ clicking sound as well. But at the same visit she told that got married and gave history of pregnancy (first trimester) when came for follow-up after 4 months. We advised her for Gynaecologist consultation whether to remove or any other instructions. Her Gynaecologist said that, if possible, you may leave the appliance in place and remove it after birth of baby. So, she was sent with the same appliance as retainer with all necessary instructions and modifications in the appliance. Upon third recall approx. 08 months after she reported with approx. two months old baby. RME bonded appliance was removed occlusion of the right side was de-arranged so straight wire (Roth prescription with 0.022-inch slot) was used for treatment (Figure 5a-d). during fourth follow-up approx. 04 months after occlusion was settled as shown in the above figures so, the appliance was deboned and scaling and polishing was done. The first removable retention plate is made with patient waiting & delivered same day. Immediately Hawley's retainer was given for 01 yrs. and asked to follow-up after one year if required. Patient occlusion was stable after one-year follow-up.

2.4. Diagnostic aids

1. Pre-treatment photographs (Extra oral and Intra oral):
2. Pre-treatment diagnostic X-rays as follows:(Figure 4a,b&c) OPG-Pan, lateral cephalogram and Maxillary occlusal:

Discussion: There are two types of maxillary expansion appliance, the rapid maxillary expansion appliance and slow expansion appliance. The use of rapid maxillary expansion appliance was decided as per evidence-based findings, as usually mid palatal suture fuses in 16 yrs. of age in girls, but in this case, it was not fused as shown

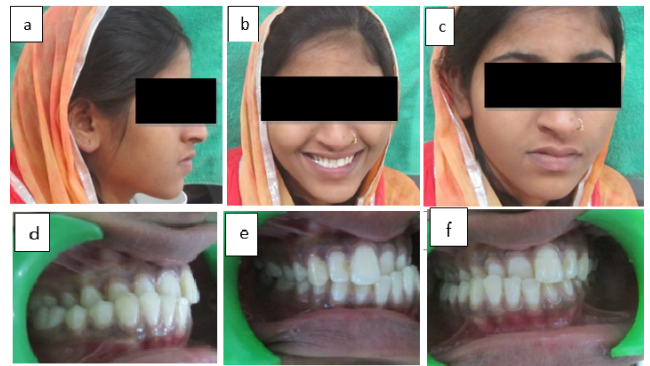

Figure 3: a: Profile view; b: Frontal smiling; c: Frontal view; d: Intra Oral Occlusion (Right View); e: Intra Oral Occlusion (Frontal View); f: Intra Oral Occlusion (Left View)

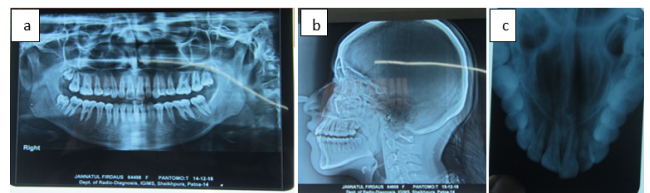


Figure 4: a: OPG Pan= DNS & Missing Lower Left Third Molar etc; b: Lateral Cephalogram; c: Maxillary Occlusal Showing Parasagittal, Hypocalcified Zone

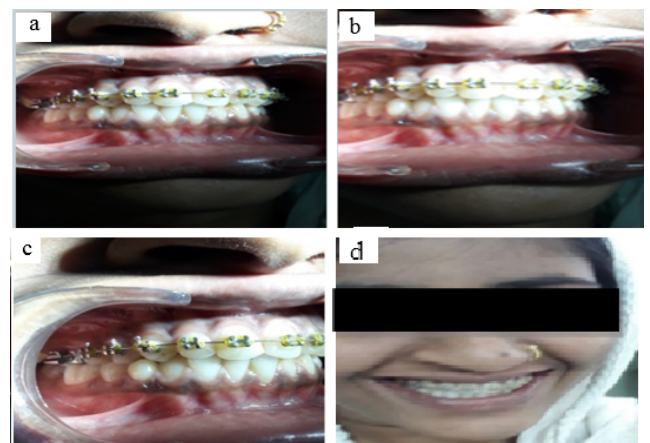


Figure 5: Treatment in progress fixed appliance (Figure 5a,b,c&d): This was the occlusion status at time of debonding (slightly overcorrected occlusion). This may be considered as the occlusion at the finished /debonded case (as post treatment photographs is missing).

Table 1: Comparison between pre-treatment and post-treatment results based on plaster model cast after de-bonding patients

Maxillary arch dimensions	Pre-treatment	Post-treatment
Inter canine width(mm)	35mm	41mm
Inter molar width(mm)	53	56mm

in the X-ray of maxillary occlusal view. The radiologically visible parasagittal hypocalcified zone with poorly calcified mid-palatal suture are seen in maxillary occlusal view. By adolescence, the oro-nasal course of the suture may become so inter-digitated that mechanical inter-locking is as in a jig-saw puzzle and islets of bone are formed. Melsen reports that transverse growth of midpalatal suture continued up to 16 yrs. in girls and 18 yrs. in boys in cadaver's study. That is why this case was chosen for RME treatment and have rare incidence.⁹ Most of the sutural attachments of the maxilla to the adjoining bones are at its posterior and superior aspects fuses by adolescent age leaving the anterior and inferior aspects free, which makes it vulnerable for lateral displacement.^{2,3,9} RME should be initiated prior to the ossification of mid-palatal suture. The bonded expander produces changes in transverse as well as vertical and A-P. The acrylic occlusal coverage opens the bite posteriorly facilitating correction of anterior cross bite opening, this was the reason why bonded RME was chosen and fabricated in this case (Table 1). There is marked transverse expansion in anterior region than posterior where lower intercanine width showed 1-2 mm of expansion too (explained on the basis of counterpart principles of Enlows growth hypothesis 1,10 finding are in concordance with literature. The maxillary posterior teeth are used as anchors during RME. These teeth show buccal tipping & are also believed to extrude little extent. Effect on the mandible show downward and backward rotation with slight increase in FMA angle. Mandibular rotation is due to extrusion & buccal tipping of maxillary molars. The evidence of increased inter-hamular width indicates some widening of choanae. The maxillary air passages are widened throughout their entire lengths from piriform aperture to choanae. This would account for the improved respiratory changes in this case finding are in concordance with literature.^{1,4,8} This increase in nasal cavity width is maximum in the inferior region & decreased towards the superior aspect. Similar gradient is found in A.P direction with the greatest increase in anterior region than posteriors. (Table 1). Dental indications of RME are as follows posterior cross bite (unilateral/bilateral), elimination of inter arch transverse discrepancies prior to orthopaedic intervention in class II malocclusions, Activation of the circummaxillary sutural system in treatment protocols for Class III skeletal cases, cleft palate patients with collapsed maxillary arch, in cases requiring face mask therapy. The medical indications of RME as follows are poor nasal airway, septal deformity, recurrent ear, nasal (or) sinus infections. The contra -indications are single tooth cross bites, in patients who are uncooperative, skeletal asymmetry of maxilla & mandible & adult cases with severe antero-posterior skeletal discrepancies, vertical growers with steep mandibular plane angle, asthma patients, anterior open bite, patent mid-palatal suture, normal buccal occlusion.

The mode of action of RME appliance upon activation compresses the periodontal ligament and bends the alveolar process buccally and slowly opens the mid-palatal suture. Opening of mid-palatal suture is triangular and or parallel with maximum opening at the incisor region and gradually diminishing towards the posterior part of palate. In superior-inferior direction the maximum opening is towards oral cavity with progressively less opening towards the nasal aspects. The amount of expansion achieved as per literature an increase in maxillary width up to 10mm can be achieved by RME. The rate of expansion is about 0.2 - 0.5 mm per day. Every millimetre of posterior expansion produces 0.7 mm of additional arch perimeter. The alveolar bone in the area adjacent to the anchor teeth bends slightly due to the resilient nature of bone. The maxillary anterior teeth there will be midline diastema. Includes most patients receiving RME and 180° daily rotation can be met with turn of 90° both morning & evening. The easiest way to rotate the screw is to have to long handle keys to work extra-orally. One key is straight and other has a bend of 45° near the end so that 90° is achieved with successive turns of 45° from each of keys. While the person responsible for turning the screw is being instructed, the clinician must demonstrate the action precisely & then the person is invited to do it as shown, having first returned the screw to 0. Only when the clinician is sure that the instructions of fully understood, patient to be send and called after one week. The adult patients between age 15 to 20 years, increasing resistance for maxillary separation may cause a force build-up& pain to patients in this age group with turns of 90°. It is possible to maintain an overall daily rotation of 180° if the total is broken down into 4 turns of 45°. Ideally, the divisions should follow 4 equal time lapses but here one may run into difficulties of organization, However, the tension disperses fairly quickly & only a comparatively short break may be needed between turns. Such patients are also asked to return after one week. Above 25 yrs. RME must not be recommended as the mid palatal suture often is opened surgically. Here it may not be necessary to reduce the overall rate of expansion in these patients. The differences between slow expansion and fast expansion of RME, as in slow expansion of RME the bio-mechanical Orthodontic effect is produced with use of light force applied below 400-gms). The results will be more of dental and stable and the duration of treatment will be of 2-4 months. In heavy force of RME activation force applied is above 500gms, the effect will be skeletal mainly than dental effects and relapse tendency will be more in initial months. The effect of orthopaedic changes also brings out favourable changes in the soft tissues structures egs; the measurements of upper lip length, lower lip-chin length, upper face width, lower face width, upper lip vermilion and lower lip vermilion demonstrated changes during treatment but showed no significant change from initial values after 1 year of retention. The overall face height, intercanthal

distance, average eye width, and nose length did not change over time. The soft tissue nasal width increased 2.0 mm during treatment. In this case though the facial smile and other facial structures parameters have improved. The turning of the screw by 90° (i.e., one turn) brings about a linear movement of 0.18 mm. The pattern of threading on either side is of opposite direction. Thus, turning the screw withdraws it from both sides simultaneously. Activation schedule: Schedule by Timms: For patients of up to 15 years of age, 90° rotation in the morning and evening. In patients over 15 years, Timms recommends 45° activation 4 times a day. Schedule by Zimring and Isaacson: In young growing patient, they recommended two turns each day for 4-5 days and later one turn each day till the desired expansion is achieved. In case of non-growing adult patients, they recommend two turns each day for first two days, one turn per day for next 5-7 days and one turn every alternate day till the desired expansion is achieved. In this case the principle of expansion followed but the activation was given as per requirements and the tolerance of the patients. The objective of retention is to hold the expansion while all those forces generated by expansion have decayed away. First 2.6 years after expansion to be critical & it is essential that in the first 3 months the fixed expansion appliance acts as a retention appliance, where in this case RME appliance was left over Approximately for 08 months in this case. The fixed straight wire appliance was given for detailing occlusion after RME removable. After fixed SWA debonding, Hawley's retention appliance was given for one year.¹⁰

3. Conclusion

Careful selection of patient and accurate diagnosis helped us for use of RME appliance in treatment of adult female, usually we ignore for RME. The patient has not only achieved optimum occlusion but also recovers from ENT problems, that also improves her breathing problem. In this case few interesting clinical experiences we came across, was too addressed effectively. There were some limitations as long-term follow-ups record for stability of the occlusion not available and post-treatment photographs because patient treatment overlapped during covid pandemic (2019-2022). The end of the story is that she was very happy with treatment outcome which improves her smile, occlusion,

improvement in breathing and self-confidence.

4. Source of Funding

None.

5. Conflict of Interest

None.

References

1. Expansion appliances /certified fixed Orthodontic courses by Indian dental academy; 2013. Available from: [27/05/2021].
2. Liu S, Xu TM, Zou W. Effects of rapid maxillary expansion on the midpalatal suture: A systematic review. *EUR J Orthod.* 2015;37(6):651–5.
3. Bazargani F, Feldmann I, Bondemark L. Three-dimensional analysis of effects of rapid maxillary expansion on facial sutures and bones. *Angle Orthod.* 2013;83(6):1074–82.
4. Buck LM, Dalci O, Darendeliler MA, Papageorgiou SN, Papadopoulou AK. Volumetric upper airway changes after rapid maxillary expansion: A systematic review and meta-analysis. *Euro J Orthod.* 2017;39(5):463–73.
5. Rajesh M. Rapid palatal expansion of maxilla. *J Clin Dentistry Oral Health.* 2020;4(2):1–2.
6. Camacho M, Change E. Rapid maxillary expansion for pediatric obstructive sleep apnea: A systematic review and meta-analysis. *Laryngoscope.* 2007;127(7):1712–9.
7. Timms D. A study of basal movements with rapid maxillary expansion appliance. *Am J Orthod.* 1980;77(5):500–7.
8. McNamara-Jr J, Lione R, Franchi L, Angelieri F, Cevidanes LHS, Darendeliler MA, et al. The role of rapid maxillary expansion in the promotion of oral and general health. *Prog Orthod.* 2015;16:33. doi:10.1186/s40510-015-0105-x.
9. Melsen B. Palatal growth studied on human autopsy material. A histologic microradiographic study. *Am J Orthod.* 1975;68(1):42–54.
10. Enlow DH, Hans MG. Text of book of essentials of facial growth. Philadelphia: Saunders; 1996.

Author biography

Sanjay Kumar, Professor

Neal Bharat Kedia, Professor

Cite this article: Kumar S, Kedia NB. Rapid maxillary expansion appliance in correction of unilateral skeletal crossbite in an adult female patient: A case review. *IP Indian J Orthod Dentofacial Res* 2024;10(2):119-123.