

Content available at: <https://www.ipinnovative.com/open-access-journals>

IP Indian Journal of Orthodontics and Dentofacial Research

Journal homepage: <https://www.ijodr.com/>

Case Report

Management of enamel demineralization- An iatrogenic effect of orthodontic treatment: A case report

Gaurav Gupta^{1*}, D K Gupta², Neelja Gupta², Kuldeep Singh Rana³, Neeraj Chandra⁴, Richa Gupta⁵

¹Dept. of Pedodontics and Preventive Dentistry, Jaipur Dental College, Private Practice at Wisdom Dental Clinics, Jaipur, Rajasthan, India

²Wisdom Dental Clinics, Jaipur, Rajasthan, India

³Dept. of Conservative Dentistry and Endodontics, Government College of Dentistry, Madhya Pradesh, India

⁴Dept. of Periodontics and Implantology, Institute of Dental Sciences, Bareilly, Uttar Pradesh, India

⁵The Tooth Clinic, Bareilly, Uttar Pradesh, India



ARTICLE INFO

Article history:

Received 13-01-2024

Accepted 10-02-2024

Available online 04-04-2024

Keywords:

Demineralization

Orthodontic

Veneers

Esthetics

ABSTRACT

Areas of demineralised enamel, usually referred to as white spot lesions (WSLs), constitute to a clinical problem in Orthodontics following treatment with fixed appliances. They result due to an imbalance between de- and remineralisation of enamel, caused by the inter-relationship of several factors. This manuscript is intended to elucidate the presentation of a clinical case treated with orthodontic braces with 10-year follow up, and management of demineralization with veneers that occurred due to long term fixed orthodontic treatment. The goal of treatment has been achieved according to patient's desire and satisfactory digital veneer placement. No further relapse has been seen in the follow up. The treatment resulted in an aesthetic, functional, and stable occlusion, along with improved facial profile.

This is an Open Access (OA) journal, and articles are distributed under the terms of the [Creative Commons Attribution-NonCommercial-ShareAlike 4.0 License](https://creativecommons.org/licenses/by-nc-sa/4.0/), which allows others to remix, tweak, and build upon the work non-commercially, as long as appropriate credit is given and the new creations are licensed under the identical terms.

For reprints contact: reprint@ipinnovative.com

1. Introduction

Demineralization is an inevitable side-effect that is often associated with fixed orthodontic treatment, mostly when associated with poor oral hygiene.¹ The acidic by-products of the bacteria in plaque are responsible factors for the subsequent enamel demineralization and formation of white spot lesions (WSL). These cause caries thereby leading to poor aesthetics and patient dissatisfaction.¹⁻³ The formation of WSL after completion of orthodontic therapy is discouraging, where goal is to improve aesthetics in the dento-facial region.

WSL develop associated with brackets, bands, arch wires, ligatures and other orthodontic appliances that

complicate conventional oral hygiene measures, leading to prolonged plaque and bacterial accumulation. This raises concern for the need of assessing the saliva, oral hygiene status and caries rate before beginning of treatment and initiating preventive measures.

The overall incidence varies greatly between 2% and 96%,⁴ with the prevalence of WSLs on at least one tooth found to be as high as 49.6% in Orthodontically-treated patients, compared with 24% in a control group of untreated patients.⁵

The appliance itself creates plaque stagnation areas, result in an increased bacterial and plaque accumulation thereby promoting demineralisation. However, salivary flow rate (and thus salivary pH and buffering capacity) also increases during orthodontic treatment.^{6,7}

* Corresponding author.

E-mail address: dr.gauravgupta99@gmail.com (G. Gupta).

Various fluoride and casein phosphor peptide-amorphous calcium phosphate (CPP-ACP) derivatives like varnish, high fluoride mouth rinse, gel or topical cream can be used for better re-mineralization purposes.⁸

The aggressive approach is composite restorations or veneers. But here a large amount of tooth structure must be removed and so local anaesthetic is required. These treatment modalities also cost more, as compared with to less invasive approaches. For these reasons, such an approach should be reserved for the lesions which cannot be managed by other approaches.⁹

Here a clinical 10 year follow up case is presented with side effect of orthodontic treatment and its successful management with digital veneers.

2. Case Report

A 23- year old male who received orthodontic treatment within the clinic complained for white and black spots in the upper front teeth after completing the braces treatment. Patients receiving orthodontic treatments are always encouraged to maintain proper oral hygiene and to use fluoride-containing toothpaste and mouthwash during their treatment and after the debonding, but many in many cases patients do not follow the instructions properly and many co- factors contribute for the WSLs.

First looking at the previous record of the patient, a 13- year- old boy came to the clinic with chief complaint of forwardly placed upper and lower teeth and main concern of parents was aesthetics and correction of teeth alignment. Treatment was begun after parent’s consent and explanation of pros and cons of the treatment. Upon intra oral examination maxillary central incisors were flared with mal-aligned lower dentition and anterior deep bite. Radiograph was taken before treatment.(Figure 1 a,b,c,d)

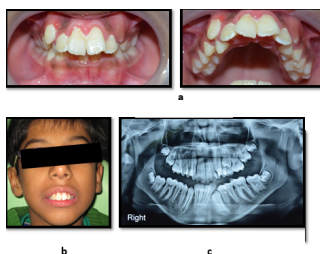


Figure 1: a, b, c Pre-treatment intraoral and extra oral images

Braces treatment was done with more than 13 follow-ups for 2 years to achieve the final results. (Figure 2 a,b,c,d,e)

Successful results were achieved with functional aesthetics and to prevent relapse retainers was provided. Patient was given instructions to maintain proper oral hygiene after treatment and was under follow-up for 10 years.

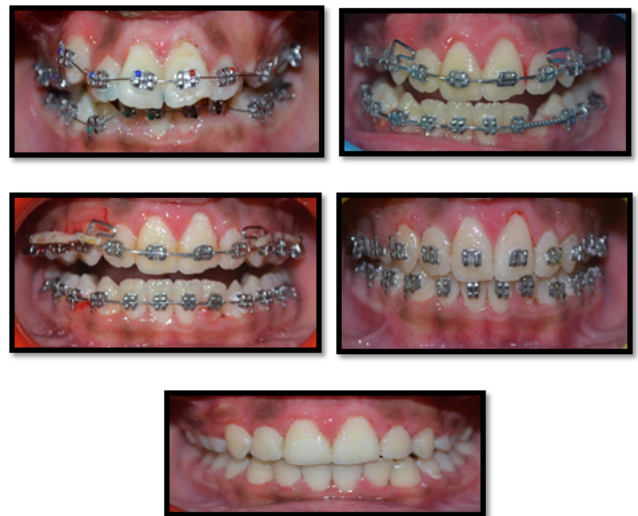

Figure 2: a, b, c, d Treatment images

Looking for the present complaint of patient was diagnosed with cavitated and non- cavitated WSLs in maxillary anterior, as the patient wasn’t regular on follow - ups and did not maintain proper hygiene he developed WSL’s so cavitated lesions were restored with composite and patient was advised for aesthetic veneers to cover up the affected demineralized areas. Teeth were prepared for digital chair side ceramic veneers. Veneers were made with CEREC (Chairside Economical Restoration of Esthetic Ceramic. (Figure 3a,b,c,d,e)

3. Discussion

High patient satisfaction with treatment outcomes for masking non-cavitated WSLs on anterior maxillary teeth after braces treatment was reported by presented case. WSLs are considered to be the major side effects of orthodontic treatment,^{10,11} specially in maxillary anterior.¹²

The aesthetic effect in managing post-orthodontic WSLs was reported to be stable 2,¹³ 6,¹⁴ and 12 months after the treatment.^{15,16} In the presented case, patient’s satisfaction with the treatment outcomes was done after the treatment and long term follow-up.

While the prevalence in male and female Orthodontic patients is the same, the severity of WSLs is greater in males, attributed to a lower standard of oral hygiene.^{17,18} In the present case too male patient was found to be affected.

Orthodontic appliances / braces create retention sites that lead to an increased proliferation of bacteria Streptococcus mutans and Lactobacilli. The number of Orthodontic attachments, the length of treatment and the level of oral hygiene are factors influencing the problem.¹⁹

The formation of WSLs or caries around fixed orthodontic attachments is a common side effect during fixed orthodontic treatment, which mars the result of a

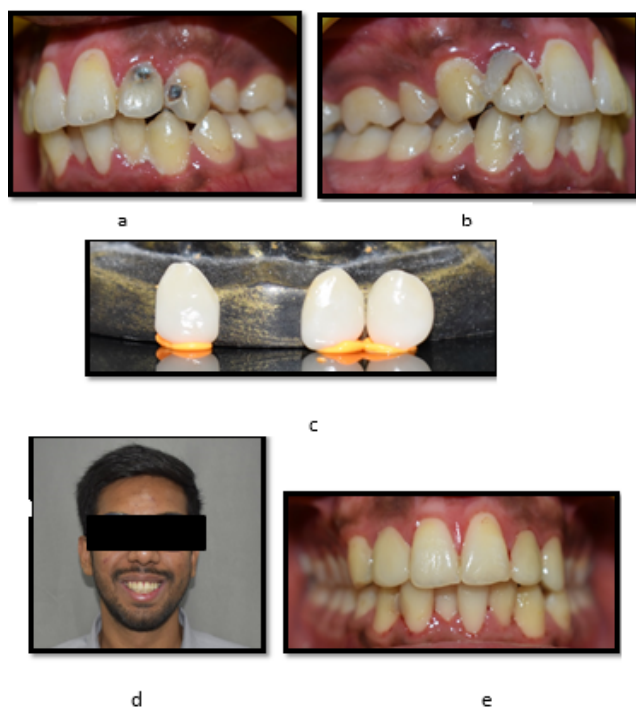


Figure 3: a, b: White spot lesions, c: Veneer, d, e: Final out come

successfully completed case. This article focuses on risk factors, preventive methods and fate of these orthodontics side effects. The importance of excellent oral hygiene practice during fixed orthodontic treatment must be explained. Preventive programs must be included to all orthodontic patients.

4. Conclusion

Demineralised WSLs are an iatrogenic effect of Orthodontic treatment. Their prevalence in Orthodontic patients is particularly high, and since they affect teeth in the aesthetic zone of dentition, they prove to be a concern to both patient and clinician. While prevention is ideal, high risk patients may still present with these lesions and their management become increasingly important. While there are many different treatment modalities to manage these lesions, prevention is optimal and should constitute the first line of defence.

5. Source of Funding

None.

6. Conflict of Interest

None.

References

1. Zachrisson BU, Brobakken BO. Clinical comparison of direct versus indirect bonding with different bracket types and adhesives. *Am J*

- Orthod.* 1978;74:62–78.
2. Ogaard B, Rolla G, Arends J. Orthodontic appliances and enamel demineralization. Part 1. Lesion development. *Am J Orthod Dentofac Orthop.* 1988;94(1):68–73.
3. Sangamesh B, Kallury A. Iatrogenic effects of orthodontic treatment - Review on white spot lesions. *Int J Sci Eng Res.* 2011;2:1–16.
4. Mitchell L. Decalcification during orthodontic treatment with fixed appliances - An overview. *Brit J.* 1992;19(3):199–205.
5. Gorelick L, Geiger AM, Gwinnett AJ. Incidence of white spot formation after bonding and banding. *Am J Orthod.* 1982;81(2):93–101.
6. Andersson R, Arvidsson E, Crossner C, Holm A, Mansson B. The flow rate, pH and buffer effect of mixed saliva in children. *J Int Assoc Dent.* 1974;5(1):1–5.
7. Forsberg CM, Oliveby A, Lagerl F. Salivary clearance of sugar before and after insertion of fixed orthodontic appliances. *Am J Orthod Dentofac.* 1992;102(6):527–57.
8. Armstrong SG, Chalmers J, Warren JJ. White spot lesions: Prevention and treatment. *Am J Orthod Dentofac Orthop.* 2010;138:690–6.
9. Bishara SE, Ostby AW. White spot lesions: formation, prevention, and treatment. *Semin Orthod.* 2008;14(3):174–82.
10. Paris S, Lueckel HM, Colfen H, Kielbassa AM. Resin infiltration of artificial enamel caries lesions with experimental light curing resins. *Dent Mater.* 2007;26(4):582–8.
11. Neuhaus KW, Graf M, Lussi A, Katsaros C. Late infiltration of post-orthodontic white spot lesions. *J Orofac Orthop.* 2010;71(6):442–7.
12. Tufekci E, Dixon JS, Gunsolley JC, Lindauer SJ. Prevalence of white spot lesions during orthodontic treatment with fixed appliances. *Angle Orthod.* 2011;81(2):206–10.
13. Senestraro SV, Crowe JJ, Wang M. Minimally invasive resin infiltration of arrested white-spot lesions: a randomized clinical trial. *J Am Dent Assoc.* 2013;144(9):997–1005.
14. Knösel M, Eckstein A, Helms HJ. Durability of esthetic improvement following icon resin infiltration of multibracket-induced white spot lesions compared with no therapy over 6 months: a single-center, split-mouth, randomized clinical trial. *Am J Orthod Dentofac Orthop.* 2013;144(1):86–96.
15. Eckstein A, Helms HJ, Knösel M. Camouflage effects following resin infiltration of postorthodontic white-spot lesions in vivo: one-year follow-up. *Angle Orthod.* 2015;85(3):374–80.
16. Feng CH, Chu XY. Efficacy of one year treatment of icon infiltration resin on post-orthodontic white spots. *Beijing Da Xue Xue Bao Yi Xue Ban.* 2013;45(1):40–3.
17. Mizrahi E. Enamel demineralization following orthodontic treatment. *Am J Orthod.* 1982;82(1):62–9.
18. Zachrisson BU, Zachrisson S. Caries incidence and orthodontic treatment with fixed appliances. *Eur J Oral Sci.* 1971;79(2):183–92.
19. Scheie A, Arneberg P, Krogstad O. Effect of orthodontic treatment on prevalence of *Streptococcus mutans* in plaque and saliva. *Eur J Oral Sci.* 1984;92(3):211–8.

Author biography

Gaurav Gupta, Professor

D K Gupta, Senior Consultant

Neelja Gupta, Senior Consultant

Kuldeep Singh Rana, Assistant Professor

Neeraj Chandra, Associate Professor

Richa Gupta, Consultant Dentist

Cite this article: Gupta G, Gupta DK, Gupta N, Rana KS, Chandra N, Gupta R. Management of enamel demineralization- An iatrogenic effect of orthodontic treatment: A case report. *IP Indian J Orthod Dentofacial Res* 2024;10(1):64-67.