

Content available at: <https://www.ipinnovative.com/open-access-journals>

IP Indian Journal of Orthodontics and Dentofacial Research

Journal homepage: <https://www.ijodr.com/>

## Review Article

# Bone-anchored maxillary protraction: A review

Nausheer Ahmed<sup>1</sup>, Ravi Kesari<sup>1</sup>, Abrar Younus A<sup>1\*</sup>, Deeksha YN<sup>1</sup>, Eduru Niharika<sup>1</sup>

<sup>1</sup>Government Dental College and Research Institute, Bangalore, Karnataka, India



### ARTICLE INFO

#### Article history:

Received 04-12-2023

Accepted 03-01-2024

Available online 04-04-2024

#### Keywords:

Bone Anchored Maxillary Protraction (BAMP)

Class III malocclusion

Infrazygomatic crest miniplates

Orthopedic forces

### ABSTRACT

Facemasks are worn during protraction therapy for maxillary deficiency, which is used to treat skeletal class III malocclusion. The maxillary dentition has historically been linked to facemask therapy, which accounts for some of the counterproductive effects such as the chin's rotation backward and downward, the elevation of the lower anterior facial height, the proclination of the maxillary incisors, the retroclination of the mandibular incisors and the mesialization of the maxillary molars with extrusion and reduction of the overbite.

This is an Open Access (OA) journal, and articles are distributed under the terms of the [Creative Commons Attribution-NonCommercial-ShareAlike 4.0 License](https://creativecommons.org/licenses/by-nc-sa/4.0/), which allows others to remix, tweak, and build upon the work non-commercially, as long as appropriate credit is given and the new creations are licensed under the identical terms.

For reprints contact: [reprint@ipinnovative.com](mailto:reprint@ipinnovative.com)

## 1. Introduction

Edward H Angle in 1899 described class III malocclusion as a abnormal relation of jaw. Patients with class III malocclusion frequently have maxillary hypoplasia. Class III skeletal malocclusion resulting from either mandibular protrusion, maxillary retrusion, or a combination of the two. According to recent research, class III is made up of either pure maxillary retrusion (19.5% to 37.5%), pure mandibular protrusion (19.1% to 45.2%), or a combination of the two (1.5% to 30%).

Patients in Class III who have a protruding lower face and a retrusive nasomaxillary area, and a concave facial profile frequently worry more about their profiles than their dental occlusion. Class III malocclusion is one of the most difficult task an orthodontist faces because it can be challenging to achieve a harmonious soft tissue profile.<sup>1-3</sup>

In traditional treatments, the maxilla is advanced by wearing a protraction facemask. Nevertheless, these devices frequently cause unfavorable side effects, such as clockwise mandibular rotation and maxillary incisor proclination. Alternatively, they have been used in conjunction with

skeletally anchored miniplates to directly apply forces to the maxillo-facial complex (type 1 BAMP) in order to counteract these effects observed with conventionally used facemasks.

A novel intraoral treatment protocol and technique were developed by De Clerk et al. to correct skeletal class III malocclusion. Using intraoral class III elastics (type 2 BAMP) from the maxillary infra zygomatic miniplates to the mandibular symphysis miniplates, this technique is performed 24 hours a day.<sup>2,3</sup>

### 1.1. Rationale

Effective maxillary advancement has been observed when treatment is performed in an early age at 10-14 years (late deciduous or early mixed dentition), the time of greatest responsiveness of the circummaxillary sutures.<sup>4</sup>

### 1.2. Types of BAMP therapy

1. Type 1: A facemask is used for protraction, and two miniplates are installed at the infrazygomatic crest.
2. Type 2: This entails using Class III intermaxillary elastics for protraction along with the implantation of

\* Corresponding author.

E-mail address: [abraryounus94@gmail.com](mailto:abraryounus94@gmail.com) (A. Younus A).

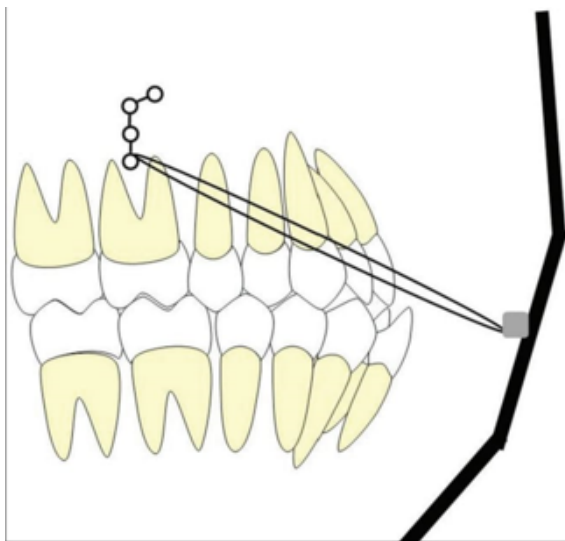
two miniplates at the mandibular symphysis and the infrazygomatic crest.

### 1.3. Procedure of placement

#### 1.3.1. Type 1 BAMP therapy

Skeletal anchoring devices in BAMP are titanium miniplates (such as Multipurpose Implant; Tasarimmed, Istanbul, Turkey). Between the lateral incisor and canine, mucosal incisions are made in the labial sulcus on both sides. Incisions should be made in the muscles and periosteum to reveal the lateral nasal wall and piriformis aperture. On the lateral nasal wall, curved miniplates are positioned, and their extension into the oral cavity is bent into a hook for securing elastics. The miniplates need to be stabilized with three screws. Orthopedic forces are used when the soft tissue has healed for about 7 to 10 days.<sup>1,5</sup>

An alternative technique involves the use of a facemask and the bilateral implantation of two miniplates at the infrazygomatic crest. Under local anesthesia, the incision is made in the buccal vestibule beneath the zygomatic buttress area. The cortical bone's surface is visible and a mucoperiosteal flap is raised. Using a bird beak orthodontic plier, surgical miniplates are free-hand bent in a curvilinear pattern that matches the shape of the zygomatic buttress area, all in accordance with the anatomy of the buttress. Three self-tapping bone screws (2 mm in diameter and 6 mm in length) are used to secure them. To stop gingival irritation and manage the vector of elastic traction, the incisions are then sutured, exposing the end of the miniplates over the keratinized attached gingiva close to the canine. To make a hook for elastics, the miniplates' end holes are cut.<sup>6</sup>

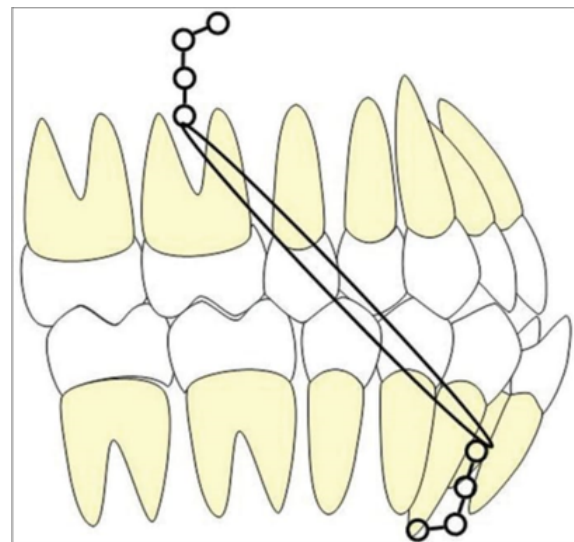


**Figure 1:** Type 1 MAMP therapy

#### 1.4. Type 2 BAMP therapy

Four miniplates are inserted during type 2 BAMP therapy, two are placed in the maxilla and two in the mandible. Two surgical miniplates are placed in the right and left zygomatic buttress areas of the patients. Under local or general anesthesia, a cut is made in the buccal vestibule beneath the zygomatic buttress. The cortical bone's underside is visible due to the elevation of the mucoperiosteal flap. Fixing the miniplates to the bone comes after pre drilling with a 1.6 mm bur.

Surgical miniplates are customized and free-hand bent with a bird-beak orthodontic plier in accordance with the zygomatic buttress's anatomy and geometry. Three self-tapping bone screws (2.3 mm in diameter and 5 mm in length) are used on each side to secure them. To stop gingival irritation and manage the vector of elastic traction, the incisions are sutured, exposing the end of the miniplates over the keratinized attached gingiva close to the canine.<sup>7</sup>



**Figure 2:** Type 2 BAMP therapy

#### 1.5. Force level in type 1 and type 2 BAMP therapy

In BAMP type 1 Following three weeks of allowing soft tissue to heal, 14–16 hours a day, 400–500g of heavy orthopedic forces are applied. Patients are instructed to wear the elastics for 14–16 hours a day, changing them once a day. To remove occlusal interferences in the incisor region until the anterior crossbite is corrected, a removable maxillary biteplate covering the posterior occlusal surfaces is positioned.<sup>1,8</sup>

With type 2 BAMP The miniplates were loaded three weeks post-surgery. Between the upper and lower miniplates, class III elastics were affixed with an initial force of 100–150 g on each side. After a month of traction, the force was increased to 200 g, and after three months, to 250

g. The patients were instructed to wear the elastics 24 hours per day and to change them at least once a day. A removable biteplate was inserted into the maxillary arch following two to three months of intermaxillary traction in order to remove occlusal interference in the incisor region until the anterior crossbite was corrected.<sup>1,9</sup>

### 1.6. The effects of BAMP therapy on orofacial structures

## 2. Skeletal effects

### On maxilla

In Type 1 BAMP, the maxilla was significantly forwardly placed than in Type 2, measuring 4.87 mm and 5.81 mm, respectively. For types 1 and 2, the protraction rates were 0.61 and 0.65 mm per month, respectively.<sup>9</sup>

Point A, the zygoma, and the orbit are all moved forward more with type 2 BAMP than with other maxillary protraction techniques like RME with Facemask (RME/FM). Maxilla forward movement of approximately 3.7 mm was observed in type 2 BAMP, while maxillary protraction of only 2.6 mm was observed in the RME/FM group.<sup>10</sup>

De Clerck et al. documented clockwise rotation of the maxilla, 2 mm of forward movement of the orbitale, 3 mm of forward movement of point PTM, and 4 mm of forward movement of point A.

Furthermore, research indicates that while bone-anchored maxillary protraction results in more skeletal changes and opens circummaxillary sutures, facemask and rapid maxillary expansion therapies primarily affect the teeth rather than the skeleton.

### 2.1. On mandible

BAMP therapy, both type 1 and type 2 has an impact on the mandible's forward growth. In type 2 BAMP there is a restraining effect on point B and Pogonion with a mandibular advancement of 2 mm and a counterclockwise movement of the mandible. Type 2 BAMP has a lower mandibular plane angle and a larger mandibular backward displacement when compared to type 1 BAMP.

Due to the action of class III elastics, which seat the condyle into the retro-discal tissues, type 2 BAMP can lead to a temporary or permanent dysfunction of the temporomandibular joint. Heymann et al. have documented the condyle's resorptive remodelling as a result of BAMP therapy.<sup>11</sup>

### 2.2. Sutures

BAMP therapy maxillary protraction is achieved mainly by distraction of circum maxillary sutures. The maturation of circum maxillary sutures involves 5 stages (according to Angelieri et al.) but greater maxillary protraction occurs

in stage A and stage B of zygomaticomaxillary suture calcification either by BAMP or facemask and RME combination.<sup>6</sup>

### 2.3. FOSSA

The condyles are seated posteriorly within the glenoid fossa as a result of BAMP therapy. After type 2 BAMP, apposition at the anterior eminence of the glenoid fossa is observed, which correlates with a posterior displacement of the anterior surface of the condyle. Additionally the posterior displacement of the posterior surface of the condyle coincides with the resorption of the posterior wall of the TMJ's articular eminence. And there was a 2.7 mm displacement in the ramus's posteriorly.<sup>1,12</sup>

## 3. Dento Alveolar Effect

The underlying skeletal discrepancy is also corrected as a result of the dentoalveolar alterations brought on by BAMP therapy. De Clerk and Coworkers observed a 3.8 mm increase in overjet, molar relation by 4.8 mm, 1.5 mm of bite deepening, and mandibular incisor proclination of 1.7 degree with type 2 BAMP. In type 1 BAMP lower incisors are retroclined and Incisor Mandibular Plane Angle is decreased. Where as in type 2 BAMP slight proclination of lower incisors and incisor Mandibular Plane Angle is increased.<sup>3,13</sup>

However, no significant changes occurred in the intermolar width of the maxilla and mandible or maxillary arch width in either type 1 or type 2 BAMP therapy.

### 3.1. Soft tissue

Soft-tissue displacements showed a wide range of variation. The soft tissue profile is greatly improved by both type 1 and type 2 BAMP approaches of therapy, which ultimately improves the concave profile. Comparing to untreated controls in BAMP therapy the upper lip, cheeks, and midface show a considerable positive sagittal displacement. The soft-tissue upper lip advanced by 3.98 mm, and the nose translated forward by 3.82 mm.

De Clerk and coworkers showed a 4 mm improvement in maxillary soft tissue variable and 1.7–2.6 mm improvement in mandibular soft tissue variable in type 2 BAMP when compared with untreated cases.<sup>9</sup>

### 3.2. Airway

After maxillary protraction therapy, the upper airway is positively altered by the maxilla moving forward and the jaw rotating in a clockwise direction as a result the airway volume increased by 1499.64 mm<sup>3</sup> in type 2 BAMP therapy when compared to untreated class III controls. according to the study when compared to the control group the constricted portion of airway was increased by 15.44

mm<sup>3</sup>.<sup>14</sup>

Compared to controls, 2D data demonstrate that BAMP lengthens the region separating the nasopharynx from the oropharynx. Additionally by enlarging the nasopharyngeal airway, it may help patients with maxillary retrusion's obstructive sleep apnea. However, redirection of mandibular growth did not reveal any appreciable alterations in the hypopharyngeal airway area.<sup>14</sup>

### 3.3. Success rate

It has been determined that skeletally anchored maxillary protraction is more effective than dentally anchored maxillary protraction. Additionally, because of improved patient compliance, intraoral skeletally anchored maxillary protraction (type 2 BAMP) was found to be more successful than extraoral skeletally anchored protraction (type 1 BAMP).

Patients appear to tolerate pre-operative counseling better when it is combined with sedation or brief general anesthesia. In terms of the miniplate's stability, 97% of the attempts were successful. The thickness and density of the external cortical bone determine the mechanical means of initial osteosynthesis screw retention, which is lowered in developing children compared to adults. Use of these plates is not advised for individuals under the age of eleven due to the higher risk of low-quality bone. Compared to the lower jaw, the upper jaw is where failures are most frequently observed.<sup>4,15</sup>

In conclusion, the following variables may have an impact on the success rate:

1. Patient counseling prior to surgery.
2. Surgery that is minimally invasive, with lower patient morbidity and sufficient instructions for recovery.
3. An excellent orthodontic follow-up schedule.

### 3.4. Complication with failures

The majority of miniplate failures occur in patients under younger patients. Van Hevele's study revealed that miniplates had a 93.6% success rate. More frequently in younger boys but not in girls, failure of the miniplates is six times higher in the maxilla. Giving a post-operative antibiotic and inserting the miniplate's neck into the associated gingiva reduce the likelihood of failure.<sup>10</sup>

## 4. Conclusion

Over time, BAMP has changed in technique and shown to be a helpful therapeutic approach when a more significant skeletal change is required. In Class III growing patients, the evaluation of the therapeutic effects of the bone-anchored maxillary protraction protocol demonstrated significant maxillary and zygomatic protraction with minimal changes in skeletal rotation or maxillary incisor dental

compensation. Additionally noteworthy and comparable were the alterations to the soft tissues and airway.<sup>1,10</sup>

## 5. Source of Funding

None.

## 6. Conflict of Interest

None.


## References

1. Kamath A, Sudhakar SS, Kannan G, Rai K, Sb A. Bone-anchored maxillary protraction (BAMP): A review. *J Orthod Sci.* 2022;11(8). doi:10.4103/jos.jos\_153\_21.
2. Hino CT, Cevidanes LH, Nguyen TT, Clerck D, Franchi HJ, Mcnamara L, et al. Three-dimensional analysis of maxillary changes associated with facemask and rapid maxillary expansion compared with bone anchored maxillary protraction. *Am J Orthod Dentofac Orthop.* 2013;144(5):705–19.
3. De Clerck H, Cevidanes L, Baccetti T. Dentofacial effects of bone-anchored maxillary protraction: a controlled study on consecutively treated Class III patients. *Am J Orthod Dentofac Orthop.* 2010;138:577–81.
4. Seowg H. Comparison of the effects on the pharyngeal airway space of maxillary protraction appliances according to the methods of anchorage. *Maxillofac Plast Reconstr Surg.* 2017;39(1):1–3.
5. Nguyent C, Koerichl D. Use of shape correspondence analysis to quantify skeletal changes associated with bone-anchored Class III correction. *Angle Orthod.* 2014;84(2):329–36.
6. Angelieri F, Ruellas AC, Yatabe MS, Cevidanes L, Franchi L, Toyama, et al. Zygomaticomaxillary suture maturation: Part II—The influence of sutural maturation on the response to maxillary protraction. *Orthod Craniofac Res.* 2017;20(3):152–63.
7. De Clerck H, Cornelis MA, Cevidanes LH, Heymann GC, Tulloch CJ. Orthopedic traction of the maxilla with miniplates: A new perspective for treatment of midface deficiency. *J Oral Maxillofac Surg.* 2009;67(10):2123–9.
8. Heymann GC, Cevidanes L, Cornelis M, Clerck D, Tulloch HJ. Three dimensional analysis of maxillary protraction with intermaxillary elastics to miniplates. *Am J Orthod Dentofac Orthop.* 2010;137(2):274–84.
9. Elnagar MH, Elshourbagy E, Ghobashy S, Khedr M, Kusnoto B, Evans CA. Three-dimensional assessment of soft tissue changes associated with bone-anchored maxillary protraction protocols. *Am J Orthod Dentofac Orthop.* 2017;152(3):336–47.
10. Hevele JV, Nout E, Claeys T, Meyns J, Scheerlinck J, Politis C. Bone anchored maxillary protraction to correct a class III skeletal relationship: A multicenter retrospective analysis of 218 patients. *J Craniomaxillofac Surg.* 2018;46(10):1800–6.
11. Nguyen T. Dentofacial orthopedics for class III corrections with bone-anchored maxillary protraction. In: Park J, editor. *Temporary Anchorage Devices in Clinical Orthodontics.* John Wiley and Sons Inc.; p. 90.
12. Hiyama S, Suda N, Ogawa M, Suzuki M, Tsuiki S. Effects of maxillary protraction on craniofacial structures and upper airway dimension. *Angle Orthod.* 2002;72:43.
13. Quos L. Maxillary protraction to treat pediatric obstructive sleep apnea and maxillary retrusion: A preliminary report. *Sleep Med.* 2019;60:60.
14. Del SM, Abbas BA, Marzouk WW, Zaher AR. Airway dimensional changes following bone anchored maxillary protraction: a systematic review. *BMC Oral Health.* 2023;23(1):37138306.
15. Swennen GDC. Success rate of miniplate anchorage for bone anchored maxillary protraction. *Angle Orthod.* 2011;81(6):1010–3.

**Author biography**

**Nausheer Ahmed**, Professor and Head

**Ravi Kesari**, PG Student

**Abrar Younus A**, Assistant Professor  <https://orcid.org/0000-0002-5720-9185>

**Deeksha YN**, PG Student

**Eduru Niharika**, PG Student

**Cite this article:** Ahmed N, Kesari R, Younus A A, Deeksha YN, Niharika E. Bone-anchored maxillary protraction: A review. *IP Indian J Orthod Dentofacial Res* 2024;10(1):24-28.