

## Supernumerary lateral incisors: Orthodontic management

Akhil Agarwal<sup>1,\*</sup>, Amit Nagar<sup>2</sup>, Vijay P. Sharma<sup>3</sup>

<sup>1</sup>Reader, B.B.D. College of Dental Sciences, Lucknow, <sup>2</sup>Professor, <sup>3</sup>Ex-Professor & Head, Dept. of Orthodontics & Dentofacial Orthopaedics, King George's Medical University, Lucknow

**\*Corresponding Author**

Email: akhilkgmc@rediffmail.com

---

### Abstract

A supernumerary tooth is one that is addition to the normal series and can be found in almost any region of the dental arch. The most common supplemental tooth is the permanent maxillary lateral incisor. In the present case report we have described the treatment planning of supernumerary lateral incisor teeth. We have also discussed the problems arising due to presence of two supplemental lateral incisors in maxillary anterior segment and its correction by fixed orthodontic treatment. Extraction of supernumerary maxillary lateral incisors with all first premolars gives the patient a beautiful smile and esthetics.

**Keywords:** Supernumerary teeth, Protrusion, Orthodontic treatment, Extraction, Retraction.

---

### Introduction

Supernumerary teeth are those that are in excess of normal complement, and mimic the normal shape<sup>1</sup> and size. Various problems associated with supernumerary teeth are failure of eruption, displacement of a permanent tooth, crowding, and dentigerous cyst formation occasionally. Sometimes supernumerary teeth are not associated with any adverse effects and are detected by chance during radiographic examination.<sup>(1,6)</sup> The treatment depends on the type and position of the supernumerary tooth and its effect over adjacent teeth/structures.

In this present case report problem caused by presence of supernumerary maxillary lateral incisors was blocked out maxillary permanent canines and proclination of anterior teeth.

### History

A 16-year-old male reported at the department of Orthodontics, Dental faculty of K.G. Medical University, Lucknow with chief complains of forwardly placed upper front teeth and irregular placement of other teeth. The patient's past medical and dental history was uneventful.

### Examination

On clinical examination, extraorally patient showed incompetent lips with convex profile and unaesthetic smile. On intraoral examination there was 7mm of overjet and first molars were in class II (half cusp) occlusion. The most noticeable feature was presence of two supernumerary maxillary lateral incisors. In maxillary arch both canines were completely blocked out

buccally. In mandibular arch there was mild crowding in anterior region.

### Radiographic evaluation

Panoramic radiographic evaluation show supernumerary lateral incisors and presence of all permanent teeth except left maxillary third molar. Lateral cephalometric evaluation show proclined maxillary and mandibular anterior teeth.

### Treatment objectives

The treatment objectives were to correct the patient's esthetics, reduce over jet, and achieving functional occlusion by bringing the maxillary canines into alignment and occlusion.

### Treatment plan

The treatment plan included the extraction of all first premolars and supernumerary maxillary lateral incisors for correction of blocked out maxillary canines. An. 022" slot edgewise appliance was placed, alignment of the maxillary and mandibular arches was done. A transpalatal arch in maxillary arch was placed to stabilize the molars.

Then K-SIR wire was ligated in maxillary arch to intrude and retract the maxillary incisors.<sup>7</sup> Retraction in mandibular arch was planned with moderate anchorage by closed coil spring for simultaneous molar correction.

The case was completed within three years and 5 months and the final result are shown in Figs.1-5

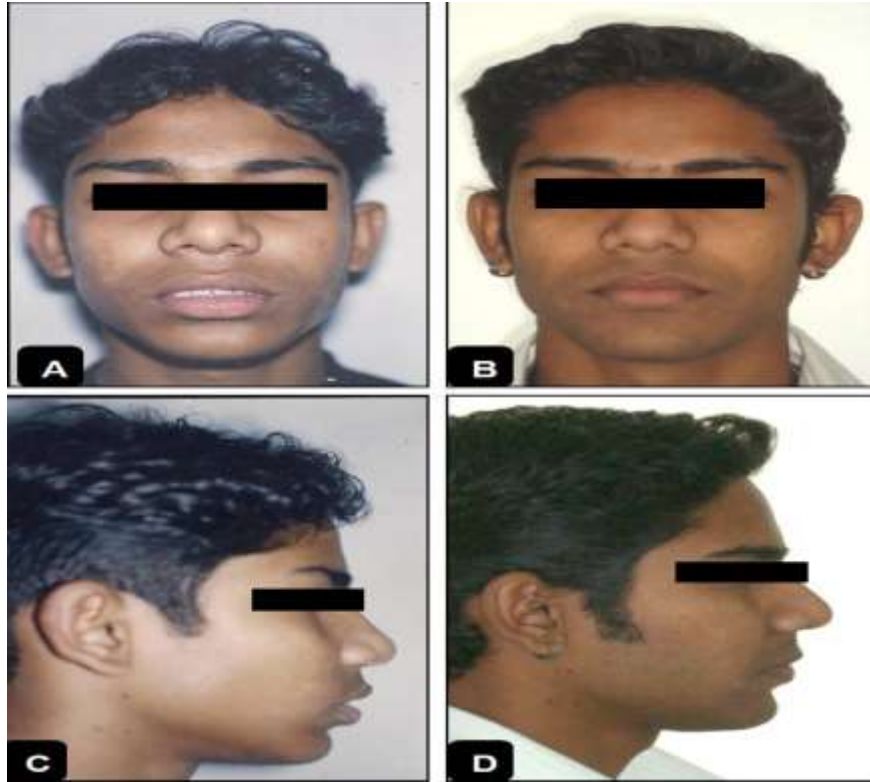


Fig. 1:

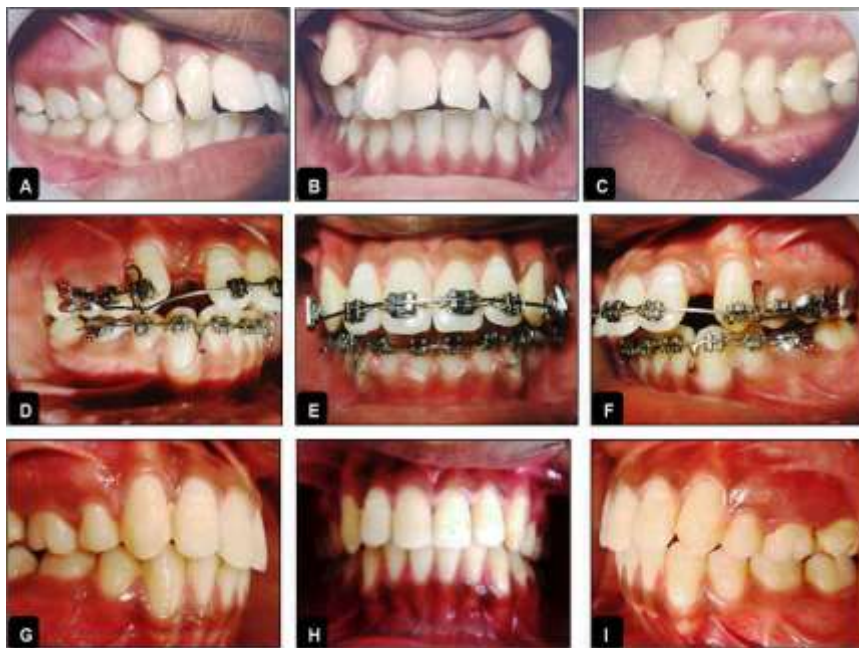

Fig. 2:

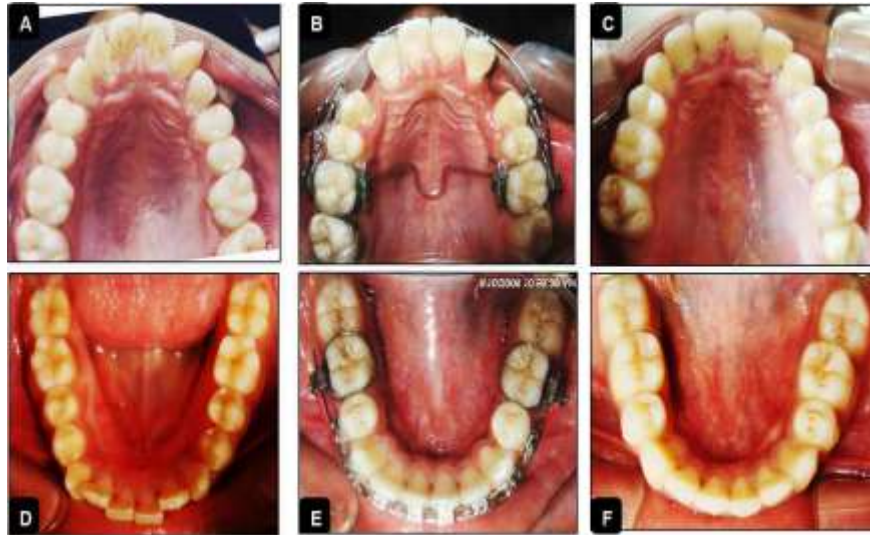


Fig. 3:

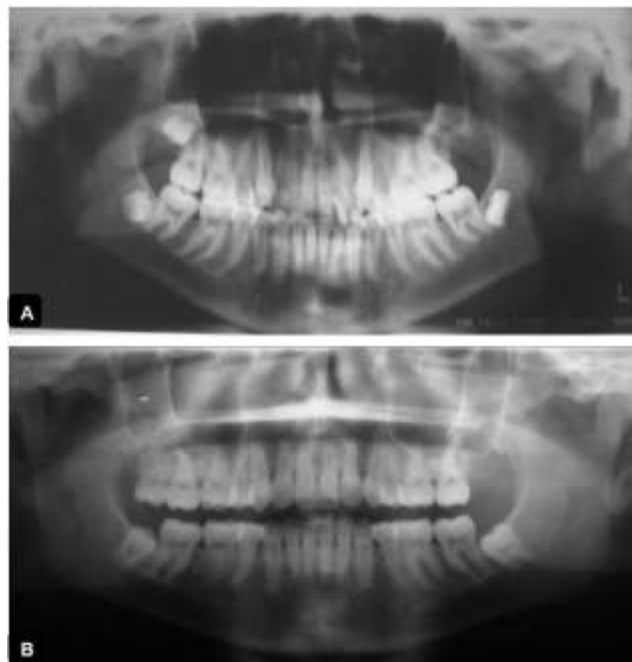

Fig. 4:

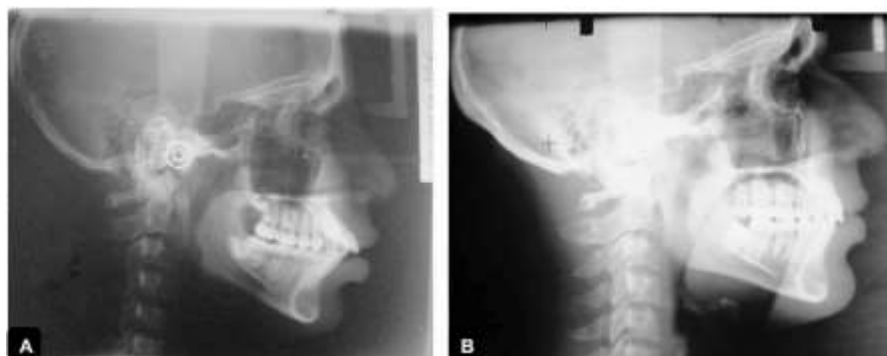

Fig. 5:

**Cephalometric evaluation**

S/N	Angle	Pre	Post
1	FMA	25	23
2	SNA	85	79
3	SNB	81	79
4	ANB	4	0

**Results**

Cephalometric evaluation as per Tweed's Analysis improved dramatically (See Table).

Convexity of profile improved in a significant amount, accompanied with competent lips.

**Summary**

The response of the treatment in this case was quite acceptable. Patient has increased self-esteem due to enhanced smile and lip competency.

**References**

1. Bhaskar SN. Synopsis of Oral Pathology. St. Louis: C.V. Mosby 1961. p. 17.
2. Garvey MT, Barry HJ, Blake M. Supernumerary Teeth - An Overview of Classification, Diagnosis and Management. *J Can Dent Assoc* 1999;65:612-6.
3. Levine N. The clinical management of supernumerary teeth. *J Can Dent Assoc* 1961;28:297-303.
4. Scheiner MA, Sampson WJ. Supernumerary teeth: a review of the literature and four case reports. *Aust Dent J* 1997;42:160-5.
5. Foster TD, Taylor GS. Characteristics of supernumerary teeth in the upper central incisor region. *Dent Pract Dent Rec* 1969;20:8-12.
6. Shafer WG, Hine MK, Levy BM. A Textbook of *Oral Pathology*. 4th ed. Philadelphia: W.B. Saunders; 1983. p. 308-11.
7. Kalra V, Simultaneous Intrusion and Retraction of the Anterior Teeth. *JCO*: 1998, Volume- 32,09,535-540.