

Soft tissue cephalometric norms for central India population: a lateral cephalometric study

Rohit Yadav¹, Jyoti Singh Gaharwar^{2*}

¹Private Practice, ²Assistant Professor, LN Medical College & Research Centre, Bhopal

*Corresponding Author

Email: jyotisingh@yahoo.com

Abstract

Background: To optimize facial attractiveness 'norms are used to define what acceptable facial traits are and to establish a range of values within which lies acceptability. Norms of measurements serve as guidelines in calculating the change required to make a face more esthetic. However' facial traits show considerable variations among different populations 'as also the concept of beauty. **Material and Methods:** The sample size was fifty young adults (25 males, 25 females) in the age group of 15-25 years, were included in the study. All subjects demonstrated good facial profile, with good occlusion and pleasing profile. Using this sample, standard.

Results: The results of the study pointed that soft tissue profile differentiate significantly between central India population and caucasians, this may be attributed to varying soft tissue thickness between different areas of the face.

Conclusion: Comparison of our sample with other ethnic groups reaffirmed the need to develop separate standards for different populations. Therefore, it is legitimate and important for those undertaking orthodontic treatment of Central India population.

Keywords: Lateral Cephalometric Radiographs, Facial Profile, Central India Population, Facial Traits.

Introduction

The primary goal for orthodontic treatment are threefold, which are commonly referred to as the 'Jacobson's Triad'. Function predominates the end results of dentofacial correction. Equally important is the individual's appearance. Appearance is one of the primary factors for which most individual seeks orthodontic treatment.

Individuals often report with chief complaint related to dentofacial deformities. Management of such deformities require a concerted and co-ordinate effort by both the orthodontist and the maxillofacial surgeon.

It is important that with judicious utilization of diagnostic aids, a sound diagnosis is arrived at in individuals seeking correction of dentofacial deformities. Assessment of patient's soft tissue profile is vital for individuals who are to undergo Orthognathic Surgery procedures, as it lends a valuable insight in the treatment planning phase.

Categorizing a patient and planning the extent of treatment is largely dependent on the normal values of the ethnic group to which the patient belongs. The analysis most commonly employed for assessment of the soft tissue profile is Burstone & Legan's Cephalometric Analysis for Orthognathic Surgery¹. The normative values employed in this analysis are based on Caucasian population. Although specialized soft tissue cephalometric norms exist for Brazilian², Greek³, Thai⁴, Iraqi⁵, Yemini⁶, Japanese⁷, Iranian⁸, Korean⁹ population no such norms are established for population (Central India)

Materials and Methods

Fifty subjects (25 males, 25 females) in the age group of 15-25 years, were included in the study. All subjects demonstrated good facial profile, balanced smile and pleasing appearance. The inclusion criteria consisted of Class I molar and canine relationship on both sides, absence of gross facial asymmetry, minimal crowding, and no history of previous Orthodontic treatment. The subjects were appropriately shielded from radiation while obtaining lateral cephalograms.

The lateral cephalometric radiographs were obtained using Kodak 8000C Digital Panoramic System (Carestream Health Inc., Rochester, NY, USA) by asking the subjects to look straight ahead such that the visual axis was parallel to the floor. The orientation of the patients head was done in Natural Head position (NHP). The cephalometric tracing were done manually on 0.03 inch acetate matte tracing papers using sharp 4H pencils. All the tracings are subjected to Soft Tissue Cephalometric analysis for Orthognathic Surgery for as described by Legan & Burstone¹. (Diagram 1, Table 1)

Results

Statistical analysis: The measurements were statistically analyzed by calculating their means and standard deviations. Then the mean values of Central India population were compared with mean values of Caucasian population with the help of Student's unpaired 't' test and 'P' value of ≤ 0.05 was considered statistically significant. (Table 2)

Table 1: Soft tissue Parameters according to Burstone & Legan’s. Soft Tissue Cephalometric Analysis for Orthognathic Surgery

S. No.	Parameter	Inference
1.	G-Sn-Pg’	Positive angle increases, Class II Profile.
2.	G-Sn(II Hp)	Describes the amount of maxillary excess or deficiency.
3.	G-Pg’(II Hp)	Indicates mandibular prognathism or retrognathism.
4.	G-Sn / Sn-Me’ (HP)	A ratio of less than One to One would suggest disproportionately larger lower third of face therefore vertical maxillary excess.
5.	Sn-Gn’-C	An obtuse angle suggest chin prominence should not be reduced.
6.	Sn-Gn’ / C-Gn’	If ratio is larger than 1, anterior projection of chin should not to be reduced.
7.	Cm-Sn-Ls	An acute angle suggests, surgical retract maxilla or retract the maxillary incisors, Obtuse angle suggest maxillary advancement.
8.	Ls to (Sn-Pg’)	If greater or less than Mean Value (3+1) suggests retracting or protracting the incisors surgically or orthodontically.
9.	Li to (Sn-Pg’)	If greater or less than Mean Value (4+1) suggests retracting or protracting the incisors surgically or orthodontically.
10.	Si to (Li-Pg’)	If greater or less than Mean Value (4+2)Suggest advancement genioplasty will help deepen the sulcus and reduction genioplasty will aid in reducing excessive sulcular depth.
11.	Sn-Stms / Stmi-Me’ (HP)	When the ratio becomes smaller than one half, often a reduction genioplasty should be considered.
12.	Stms-I	Helps in determining the vertical position of maxilla.
13.	Stms-Stmi (HP)	With increase interlabial gap, there is increase in vertical maxillary excess, with no interlabial gap have maxillary deficiency.

Table 2: Soft Tissue COGS: Comparison of Caucasian and Mahakaushal population values

Measurement [†]	Caucasian (n=40)		Indian (n=50)		Unpaired T-Value	P-Value	Significance
	Mean	SD	Mean	SD			
Facial Form							
G-Sn-Pg’ ^{II}	12	4	13.66	3.572057	-2.17	< 0.05	*
G-Sn (II HP)	6.0	3	8.36	3.555737	-2.66	< 0.01	**
G-Pg’ (II HP)	0	4	1.22	5.080133	-1.34	> 0.05	NS
G-Sn/Sn-Me’	1.0	1	1.0066	0.075986	0.01	> 0.05	NS
Sn-Gn’-C ^{II}	100	7	106.06	5.76198	-5.09	< 0.001	***
Sn-Gn’/C-Gn’	1	2	1.2184	0.134063	-6.12	< 0.001	***
Lip Position and Form							
Cm-Sn-Ls ^{II}	102	8.0	103.24	8.908973	-0.8989	> 0.05	NS
Ls to (Sn-Pg’)	3.0	1.0	3.44	1.928942	-1.615	> 0.05	NS
Li to (Sn-Pg’)	2.0	1.0	3.14	1.829576	-2.51	< 0.001	***
Si to (Li-Pg’)	4.0	2.0	6.5	1.693324	-6.37	< 0.001	***
Sn-Stms / Stmi – Me’	0.5	0.0	0.4538	0.055028	0.002	-	-
Stms- I	2.0	2.0	2.46	1.343313	1.874	> 0.05	NS
Stms-Stmi	2.0	2.0	0.36	0.484873	4.46	< 0.01	***

Key: II Angular measurements in degrees; + all other measurements are linear in millimeters.

*P<0.05 – Significant; **P<0.01 – Highly Significant; ***P<0.001 – Very significant.

NS - Non Significant.

Discussion

One of the most important components of orthodontic diagnosis and treatment planning is the evaluation of patient’s soft tissue profile. The primary goal of orthodontic treatment is to attain and preserve optimal facial attractiveness. A scientific and

quantitative study of the craniofacial morphology is essential for orthodontic diagnosis. To this end, a lateral cephalometric radiograph is probably the most valuable diagnostic tool available.

Investigators have developed numerous cephalometric analyses to interpret the diagnostic

information the lateral cephalogram provides. In orthodontic practice a diagnosis is determined, in part, comparing patient's cephalometric measurements to standard values. Lateral cephalometric norms, are specific to an ethnic group and cannot always be applied to other ethnic types. In spite of possible ethnic differences, most classical cephalometric standards are based on sample populations belonging to Caucasian ethnicity.

Cephalometrics for Orthognathic Surgery (COGS), introduced by Burstone and Legan⁽¹⁾, is a widely accepted cephalometric analysis for assessing both hard and soft tissues. The norms put forth by Burstone & Legan are specific to Caucasian population. For this reason, attempts have been made to investigate the differences in the human face among various ethnic groups including Brazilians⁽²⁾, Greek⁽³⁾, Thai⁽⁴⁾, Iraqi⁽⁵⁾, Yemini⁽⁶⁾, Japanese⁽⁷⁾, Iranian⁽⁸⁾, Koreans⁽⁹⁾. In most of these comparative population studies greater ethnic differences in soft tissue relationships were seen in skeletal and dental relationships types. Hence, the present study was undertaken to establish soft tissue cephalometric norms for Central India population using the parameters of COGS analysis and compare the derived standards to earlier established Caucasian norms.

It was found that soft tissue profile differed significantly between Central India population sample and the Caucasian sample. This might be because of varying soft tissue thickness over different areas of the face. The Central India group exhibited greater convex profiles with increased maxillary prognathism, as

indicated by the increased facial convexity angle (GSn-Pg'), and more anterior position of subnasale in relation to glabella perpendicular (G-Sn). There was no statistically significant difference between Central India & Caucasian population in relation to the position of the soft tissue pogonion.

The vertical height ratio between middle and lower face height (G-Sn/Sn-Me') was similar to that of Caucasians. However Central India ethnic population demonstrated a more obtuse lower face – throat angle (Sn-Gn'-C), with a significantly increased lower vertical height to depth ratio (Sn-Gn'/C-Gn').

The nasolabial angle (Cm-Sn-Ls) was almost the same in both the groups. The lower lip was more protrusive in relation to lower facial plane (Li to Sn-Pg') in Central India population. Probably this contributed to the greater depth of the mentolabial sulcus (Si to Li-Pg') in Central India population than in Caucasians. The lower lip length (Stmi-Me') was greater in Central India population as indicated by the decreased ratio of upper to lower lip length (Sn-Stms/Stmi-Me'). Central India population showed more of their maxillary incisors below the upper lip line (Stms) at rest. The mean Fig for the interlabial gap was greater in Central India population due of a high incidence of lip incompetence in the sample studied.

This study conclusively demonstrated that norms applicable to Caucasian population cannot be applied to Central Indian population as there are significant differences in several parameters.

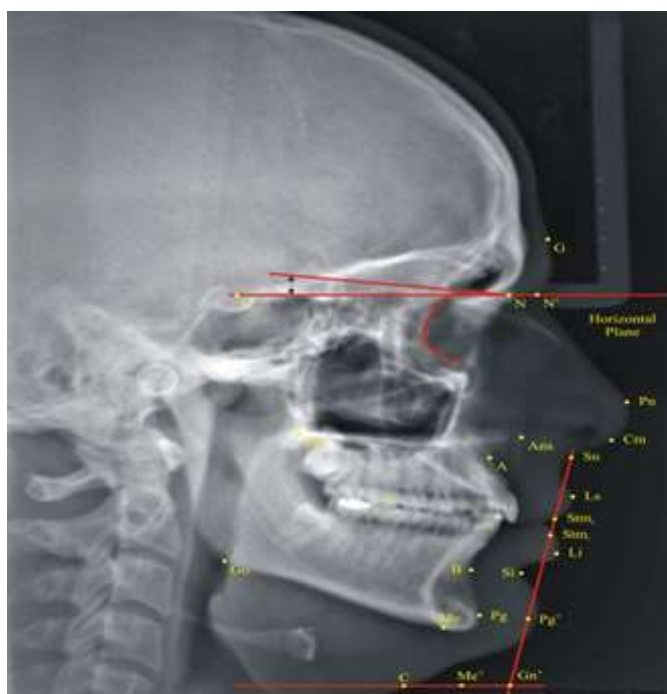


Diagram 1: Hard and Soft Tissue Cephalometric Landmarks employed in Burstone & Legan's Cephalometric analysis for Orthognathic Surgery. Hard & soft Tissue Land Marks

1. N- Nasion
2. S- Sella
3. Go- Gonion
4. Me- Menton
5. Gn- gnathion
6. Pg- Pogonion
7. B- Point B
8. A- Point A
9. ANS- Anterior nasal spin
10. PNS- Posterior nasal Spine
11. G- Glabella
12. N'-Soft tissue nasion
13. Pn- Pronasale
14. Cm- Columella
15. Sn- Subnasale
16. Ls- Labrale Superius
17. Stms- Stomion Superius
18. Stmi- Stomion inferius
19. Li- Labrale inferius
20. Si- Mentolabial sulcus
21. Gn'- Soft tissue gnathion
22. Me'- Soft tissue menton
23. C- Cervical point

9. Hwang HS, Kim WS, McNamara JA. Jr. Ethnic Difference in the soft tissue profile of Korean & European American adults with normal occlusion & well balanced faces. *Angle Orthod*; 2002;72:72-80.

Conclusion

As is evident in this study ethnic differences in soft tissue architecture are present between Central India & Caucasian populations. The soft tissue Cephalometric values put forth by us will aid in diagnosis & treatment planning in individuals belonging to Central India population in Madhya Pradesh who are planned for orthognathic surgery.

References

1. Burstone CJ, Legan HL. Soft tissue cephalometric analysis for orthognathic surgery. *J Oral Surg*; 1980;38:744-755.
2. Magnani MB, Nower DF, Nower PR, PJS, Garbui IU, Boeck EM. Assessment of the nasolabial angle in Young Brazilian black subjects with normal occlusion. *Pesqui Odontol Bras*; 2004;18(3):233-237.
3. Argyropoulos E, Sassouni V. Comparison of the dentofacial patterns for native Greek and American-Caucasian adolescents. *Am J Orthod Dentofac Orthop*; 1989;18:43-49.
4. Satravaha S, Schlegel KD. The significance of the integumentary profile. *Am J Orthod Dentofac Orthop*; 1987;92:422-426.
5. Kadhom ZM, Janabi MF. Soft tissue cephalometric norms for a sample of Iraqi adults with Class I normal occlusion in natural head position. *J Bag College of Dentistry*; 2011;23(3):160-166.
6. Gunaid T Al, Yamada K, Yamaki M, Saito I. Soft-tissue cephalometric norms in Yemeni men. *Am J Orthod Dentofac Orthop*; 2007;132(5):7-14.
7. Miyajima K, McNamara JA, Kimura T, Murata S, Lizuka T. Craniofacial structure of Japanese and European-American adults with normal occlusion and well-balanced faces. *Am J Orthod Dentofac Orthop*; 1996; 110: 431-438.
8. Davoddy PR, Sassouni V. Dentofacial pattern differences between Iranians and American Caucasians. *Am J Orthod*; 1978;73:677-675.