

Content available at: <https://www.ipinnovative.com/open-access-journals>

IP Indian Journal of Orthodontics and Dentofacial Research

Journal homepage: <https://www.ijodr.com/>

## Short Communication

# UnBand- Perioprotect palatal connector

Sandra Susan Saji<sup>1</sup>, Dilip Kumar N<sup>1</sup>, Shruthi M S<sup>1\*</sup>, Aparna P<sup>1</sup>,  
Bhavya M Jain<sup>1</sup>, Kiran M Kumar P<sup>1</sup>

<sup>1</sup>Dept. of Orthodontics, College of Dental Sciences, Davangere, Karnataka, India



### ARTICLE INFO

#### Article history:

Received 14-11-2023

Accepted 29-12-2023

Available online 19-01-2024

#### Keywords:

Bonding

Transpalatal arch

### ABSTRACT

The field of orthodontics demands versatility in appliances for faster and efficient treatment process. One such versatile auxiliary used is the Transpalatal arch for anchorage and for active tooth movements such as for correcting molar rotation and up righting, stabilization of posterior transverse dimensions during treatment, and maintenance of leeway spaces during the transition of the dentition.

The process of insertion of the Transpalatal arch is cumbersome. To address these limitations, alternative methods for using the Transpalatal arch has been innovated where design experimented does not demand laborious procedures and can be done inhouse and is cost effective.

There are three methods custom made Custom made Transpalatal arch is fabricated. Lingual/ Palatal surface of the molar is etched and bonding agent applied and cured. The stub of the TPA is then adapted to the tooth surface and flowable resin is applied and then cured. Preformed mesh is cut and welded onto the lingual sheath thereby converting a weldable lingual sheath into a bondable sheath. Mesh is then adapted onto the prepared tooth surface and then cured with composite. The mesh provides mechanical retention which is helpful for bonding. The custom made Transpalatal arch is now inserted. Vertical and horizontal grooves are made on the posterior side of the lingual sheath using bur. The sheath is then sandblasted to create a rough surface which provides a micromechanical retention area. This sheath is then bonded directly onto the tooth surface and Transpalatal arch inserted.

The results suggest that orthodontic appliances without bands are preferable. Bonded TPA's are less invasive and also requires less chairside time.

Bonded TPA's can overcome these issues and assist both the clinician and the patient in achieving faster orthodontic treatment and reducing discomfort. Therefore, through these innovations, a clinician can judiciously choose based on requirements and employ it effectively in orthodontic treatment.

This is an Open Access (OA) journal, and articles are distributed under the terms of the [Creative Commons Attribution-NonCommercial-ShareAlike 4.0 License](https://creativecommons.org/licenses/by-nc-sa/4.0/), which allows others to remix, tweak, and build upon the work non-commercially, as long as appropriate credit is given and the new creations are licensed under the identical terms.

For reprints contact: [reprint@ipinnovative.com](mailto:reprint@ipinnovative.com)

## 1. Introduction

The field of orthodontics demands versatility in appliances for faster and efficient treatment process. One such versatile auxiliary used is the Transpalatal arch for anchorage and for active tooth movements such as for correcting molar rotation and uprighting, stabilization of posterior transverse dimensions during treatment, and maintenance of leeway

spaces during the transition of the dentition. Transpalatal arch, introduced in 1972, by Robert A Goshgarian has a very simple and modest design and is fabricated from 0.036 inch stainless steel wire which spans the palate and connects bands on both maxillary first permanent molars.<sup>1</sup> The auxiliary can either be inserted into the lingual sheath or soldered onto the molar bands.

The process of insertion of the Transpalatal arch is cumbersome. This requires the molars to be banded and demands multiple appointments for the same. Prior to

\* Corresponding author.

E-mail address: [drshruthi06@gmail.com](mailto:drshruthi06@gmail.com) (Shruthi M S).

banding, creation of interdental gap using separators also causes discomfort and inconvenience for the patient and is time consuming. Enamel demineralization is a recognized iatrogenic risk factor associated with fixed appliance orthodontic treatment. The iatrogenically created defective band-tooth interface areas pose particular problems, because the ingress of food particles and bacterial plaque make these areas prone to demineralization such as decalcification and white spot lesions.<sup>2</sup> Periodontal compromised patients with weak gingival attachment can further worsen by using molar bands. The cervical margin of a band is adjacent to the gum or subgingival margin, it may cause poor oral hygiene on the cervical area, and may result in gingivitis and periodontitis. The plaque index and bleeding scores are significantly increased for banded teeth as compared with control sites.<sup>3</sup>

To address these limitations, alternative methods for using the Transpalatal arch has been innovated by the authors. The technique utilizes composite resin material for bonding the TPA onto the molars. A similar design was reported with customized bonding base by Fujisawa et al in 2011 which involved the patients records sent to the laboratory for fabrication of the bonding base.<sup>4</sup>

The following design experimented does not demand laborious procedures and can be done inhouse and is cost effective.

## 2. Armamentarium

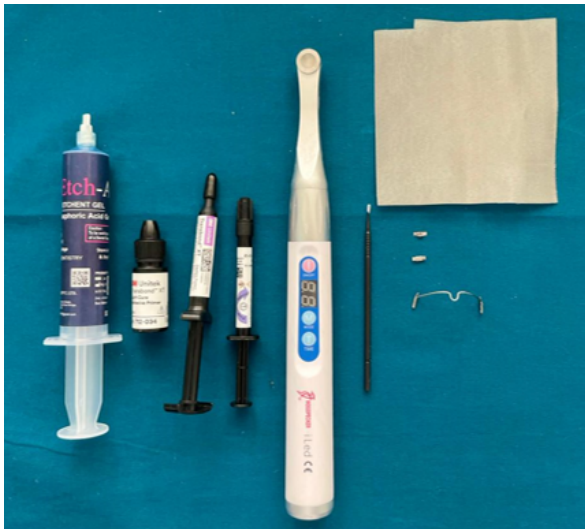

Figure 1: Armamentarium

## 3. Appliance Design

### 3.1. Direct bonded

#### 3.1.1. Procedure

Custom made Transpalatal arch is fabricated. Lingual/Palatal surface of the molar is etched and bonding agent applied and cured. The stub of the TPA is then adapted to the tooth surface and flowable resin is applied and then cured.

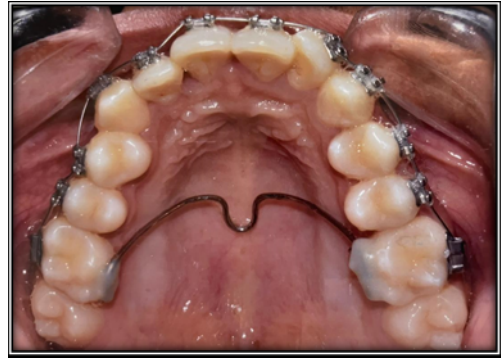

Figure 2: TPA stub bonded directly onto tooth surface

### 3.2. Mesh bonded TPA

#### 3.2.1. Procedure

Preformed mesh is cut and welded onto the lingual sheath thereby converting a weldable lingual sheath into a bondable sheath. Mesh is then adapted onto the prepared tooth surface and then cured with composite. The mesh provides mechanical retention which is helpful for bonding. The custom made Transpalatal arch is now inserted.

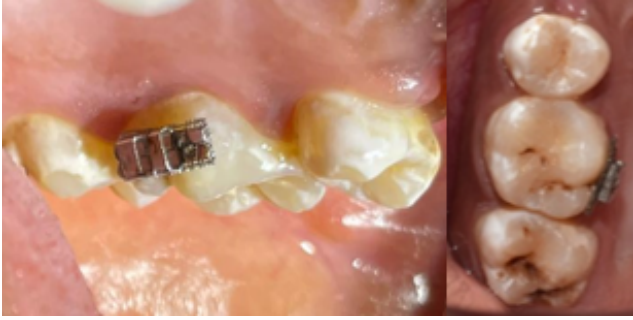


Figure 3: Preformed mesh welded onto the sheath

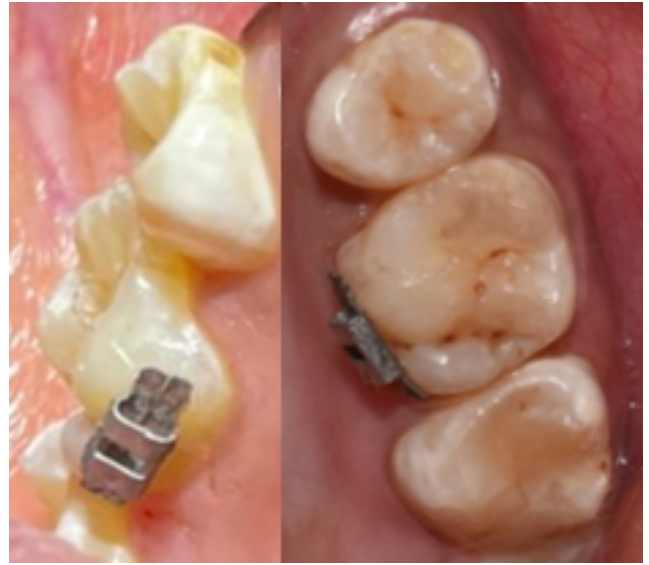### 3.3. Lingual sheath with grooves

#### 3.3.1. Procedure

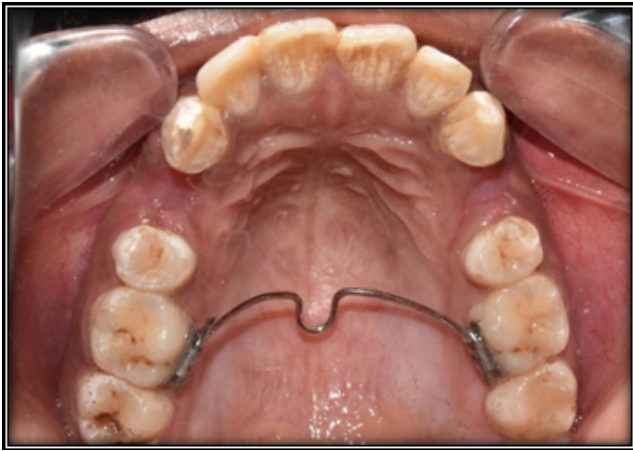Vertical and horizontal grooves are made on the posterior side of the lingual sheath using bur. The sheath is then sandblasted to create a rough surface which provides a micromechanical retention area. This sheath is then bonded directly onto the tooth surface and Transpalatal arch inserted.



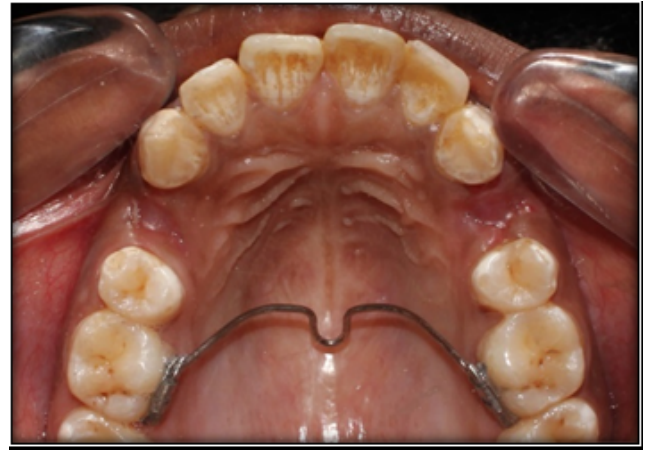**Figure 4:** Palatal and occlusal view of mesh bonded TPA



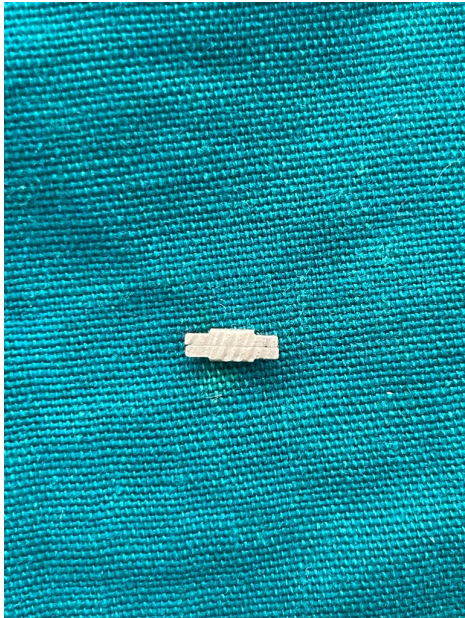**Figure 7:** Palatal and Occlusal view of bonded sheath



**Figure 5:** Mesh bonded lingual sheath and TPA inserted



**Figure 8:** Lingual sheath with grooves bonded onto the tooth surface and TPA inserted



**Figure 6:** Lingual sheath with grooves for micromechanical retention

#### 4. Clinical Procedure

1. The tooth surface is cleaned, etched and primed for bonding.
2. For Direct bonded Transpalatal arch, the stub is directly bonded onto tooth surface using flowable composite.
3. For Mesh bonded Transpalatal arch, the mesh is adapted onto the sheath and welded. This is then bonded onto the tooth surface and TPA inserted.
4. The lingual sheath with grooves entails the formation of grooves on the posterior surface of the sheath using a bur, followed by sandblasting to generate a rough surface. This rough texture facilitates micromechanical retention for effective bonding.



## 5. Discussion

The cornerstone of orthodontics lies in anchorage and Transpalatal arch is a widely used auxiliary. However, due to the usage of multiple bands, this appliance requires laboratory procedures. A microbiologic evaluation of the venous blood samples of 40 healthy orthodontic patients with good oral hygiene after orthodontic banding revealed a postoperative bacteraemia incidence of 7.5%.<sup>3</sup> These results suggest that orthodontic appliances without bands are preferable.

Bonded TPA's are less invasive and also requires less chairside time. In case of bond failure, adjustments can be done easily without disturbing the labial side appliances. Bonding also reduces the risk for iatrogenic effects such as decalcification and white spot lesions. A study by Boyd et al showed that banded molars showed gingival inflammation and plaque accumulation and greater loss of attachment.<sup>5,6</sup>

Bonded TPA's can overcome these issues and assist both the clinician and the patient in achieving faster orthodontic treatment and reducing discomfort. Therefore, through these innovations, a clinician can judiciously choose based on requirements and employ it effectively in orthodontic treatment.

## 6. Source of Funding

None.

## 7. Conflict of Interest

None.


## References

1. Kharche A, Durkar S, Kawale P, Yerawadekar S, Jethi S. Transpalatal arch: an overview of literature. *J Adv Med Dent Sci Res*. 2019;7(2):26–

32.


2. Liebenberg WH. Extended fissure sealants: an adjunctive aid in the prevention of demineralization around orthodontic bands. *Quintessence Int*. 1994;25(5):303–12.
3. Huser MC, Baehni PC, Lang R. Effects of orthodontic bands on microbiologic and clinical parameters. *Am J Orthod Dentofacial Orthop*. 1990;97(3):213–8.
4. Fujisawa M, Komori A. A modified transpalatal arch with customized bonding base. *Orthodontic Waves*. 2011;70(1):39–42.
5. Boyd RL, Baumrind S. Periodontal considerations in the use of bonds or bands on molars in adolescents and adults. *Angle Orthod*. 1992;62(2):117–26.
6. Erverdi N, Kadir T, Ozkan H, Acar A. Investigation of bacteraemia after orthodontic banding. *Am J Orthod Dentofacial Orthop*. 1999;116(6):687–90.

## Author biography


**Sandra Susan Saji**, Post Graduate Student  <https://orcid.org/0009-0008-8970-1490>

**Dilip Kumar N**, Professor  <https://orcid.org/0009-0007-7497-2987>

**Shruthi M S**, Assistant Professor  <https://orcid.org/0000-0002-7893-4319>

**Aparna P**, Professor  <https://orcid.org/0000-0002-3504-4885>

**Bhavya M Jain**, Assistant Professor  <https://orcid.org/0009-0001-0300-6702>

**Kiran M Kumar P**, Assistant Professor  <https://orcid.org/0000-0002-7209-8807>

**Cite this article:** Saji SS, Dilip Kumar N, Shruthi M S, Aparna P, Jain BM, Kiran M Kumar P. UnBand- Perioprotect palatal connector. *IP Indian J Orthod Dentofacial Res* 2023;9(4):296-299.