

Content available at: <https://www.ipinnovative.com/open-access-journals>

IP Indian Journal of Orthodontics and Dentofacial Research

Journal homepage: <https://www.ijodr.com/>

## Case Report

# An innovative approach for treatment of anterior open bite in Class II division 1 patient with zygomatic implant and spur assisted appliance - A case report

Fazal-ur-Raheman Chowdary<sup>1</sup>, Vishwanath S Patil<sup>2</sup>, Basanagouda C Patil<sup>2</sup>,  
Muhammed Faseehuddin<sup>1,\*</sup>, Akash Kencha<sup>3</sup>, Abrar Younus A<sup>1b,4</sup>

<sup>1</sup>Dept. of Orthodontics and Dentofacial Orthopedics, Al-Badar Rural Dental College & Hospital, Kalaburagi, Karnataka, India

<sup>2</sup>Dept. of Orthodontics and Dentofacial Orthopaedics, HKE's S Nijalingappa Institute of Dental Science & Research, Kalaburgi, Karnataka, India

<sup>3</sup>Dept. of Orthodontics and Dentofacial Orthopedics, S. B. Patil Institute Dental College & Hospital, Bidar, Karnataka, India

<sup>4</sup>Dept. of Orthodontics, Consultant Orthodontist, Bangalore, Karnataka, India



## ARTICLE INFO

### Article history:

Received 04-05-2023

Accepted 20-07-2023

Available online 08-09-2023

### Keywords:

Zygomatic Implant

Molar Intrusion

Open Bite

## ABSTRACT

Controlling anchorage is one of the foremost necessary aspects of treatment. Moderate anchorage is comparatively simple to manage with the use of some intraoral appliances and biomechanical procedures. On the opposite hand, cases that need the most anchorage need extraoral support to strengthen the anchorage. In some instances, 100 percent anchorage has got to be maintained, such an anchorage may be termed as absolute anchorage. It's tough and not possible to get absolute anchorage by using typical ways like extraoral force application. In this case report, we describe the treatment of Open bite by using the support of Zygomatic plates and Spurs anteriorly placed with the combination of posterior bite blocks. A 20-year-old female reported to our department of orthodontics with the chief complaint of anteriorly placed upper front teeth. There was no relevant medical history; she was having tongue thrusting habit, acute nasolabial angle and incompetent lips. Overjet of 12mm and anterior skeletal open bite from canine to canine of 5mm was present associated with anterior tongue thrusting habit, and constricted upper arch. The molar relation was end-on on the right side and class II on left side. Canine relation is end-on, on both the side. Growth pattern is vertical. Upper arch is well aligned with constriction in premolar region; lower arch has crowding of 6 mm. The treatment plan was selected as alignment of the teeth with fixed mechanotherapy and impaction of the maxillary posteriors using zygomatic anchorage with posterior bite block and spurs soldered to the anterior part of the appliance. The sutures were removed after 7 days, the appliance was into the patient's mouth and secured with a power chain to the hooks of the appliance and the hook of zygomatic implant, 400gms of force was applied on both the sides.

This is an Open Access (OA) journal, and articles are distributed under the terms of the [Creative Commons Attribution-NonCommercial-ShareAlike 4.0 License](https://creativecommons.org/licenses/by-nc-sa/4.0/), which allows others to remix, tweak, and build upon the work non-commercially, as long as appropriate credit is given and the new creations are licensed under the identical terms.

For reprints contact: [reprint@ipinnovative.com](mailto:reprint@ipinnovative.com)

## 1. Introduction

Treating and retaining anterior open bite is a challenge for the Orthodontist. Even though the prevalence of open bite is low (3.5% in patients between the age of 8 to 17 years), the problems related to function, health, stability, and patients' psychology are common with anterior open bite.<sup>1</sup>

An anterior open bite is caused due to multiple factors including Skeletal, Dental, and soft tissue factors.<sup>2</sup> Morphologically, there is an increase in the vertical dimensions and the development of the maxillary posterior dentoalveolar structure.<sup>3</sup> This malocclusion causes aesthetic problems to the patient, impairs mastication, and causes problems in speech.<sup>4</sup>

\* Corresponding author.

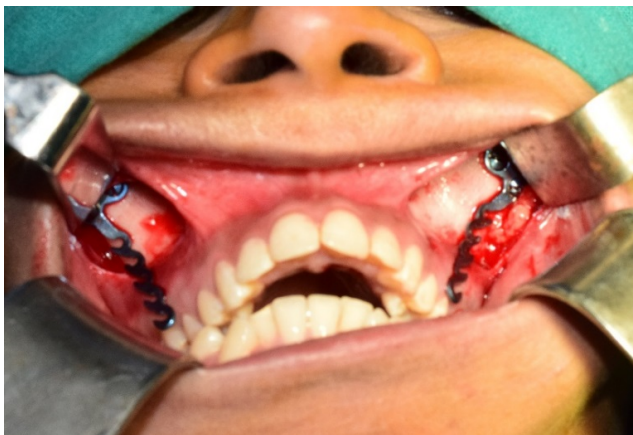E-mail address: [abraryounus94@gmail.com](mailto:abraryounus94@gmail.com) (M. Faseehuddin).

Controlling anchorage is one of the foremost necessary aspects of treatment. Moderate anchorage is comparatively simple to manage with the use of some intraoral appliances and biomechanical procedures. On the opposite hand, cases that need the most anchorage need extraoral support to strengthen the anchorage. In some instances, 100 percent anchorage has got to be maintained, such an anchorage may be termed as absolute anchorage. It's tough and not possible to get absolute anchorage by using typical ways like extraoral force application.<sup>5</sup>

In this case report, we describe the treatment of Open bite by using the support of Zygomatic plates and Spurs anteriorly placed with the combination of posterior bite blocks.

## 2. Zygomatic Implant Surgery

Zygomatic implant (Figure 1) surgery was conducted using local infiltration anaesthesia bilaterally. Incision was taken to reach the zygomatic buttress area. The 'L' shaped implant from 'BK Surgical' was contoured according to bone morphology and attached using three bone screws.



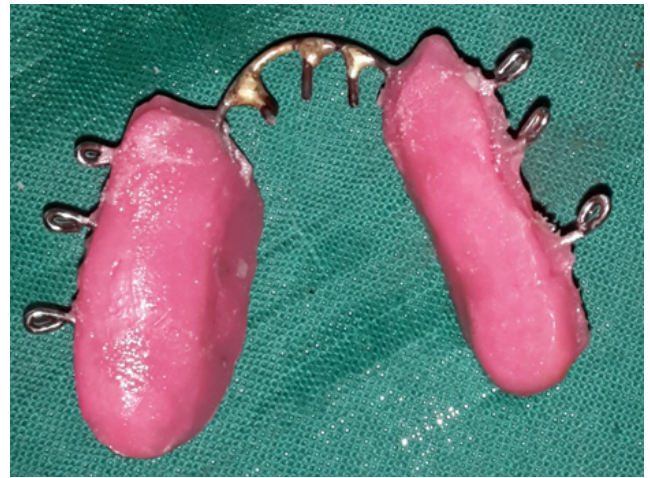**Fig. 1:** Zygomatic implant surgery under Local Anaesthesia

### 2.1. Appliance design and fabrication

On the basis of design described by Roberto Justus<sup>1</sup> in his study, we modified the design (Figure 2) according to our clinical need. It contains 0.9mm stainless steel round wire stretched covering the entire arch, with bite blocks attached to the pre-molars and molars of both the side for intrusion of molars and three horizontal hooks on both the buccal side to attach elastomeric chain to hook of Zygomatic implant and four spurs soldered anteriorly on palatal side to comprehend the tongue thrusting habit.

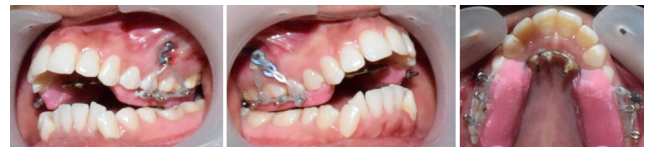### 2.2. Appliance insertion and force application

The sutures were removed after 7 days, the appliance was inserted (Figure 3) into the patient's mouth and secured with



**Fig. 2:** The modified appliance used for maxillary posterior intrusion

a power chain to the hooks of the appliance and the hook of zygomatic implant, 400gms of force was applied on both the sides.

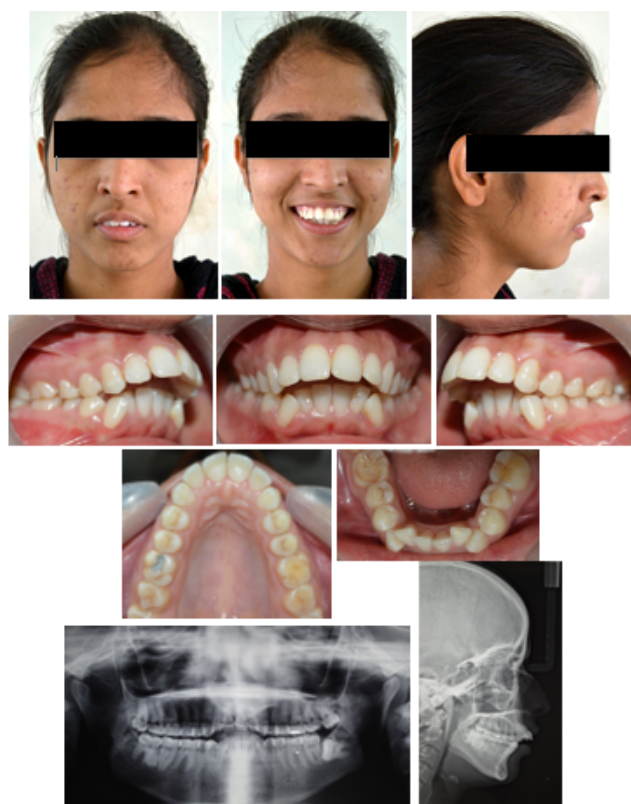

**Fig. 3:** The modified appliance placed in the patient's mouth.

## 3. Case Report

### 3.1. Diagnosis

A 20-year-old female had reported to our department of orthodontics with the chief complaint of anteriorly placed upper front teeth (Figure 4). There was no relevant medical history; she was having tongue thrusting habit, acute nasolabial angle and incompetent lips. Overjet of 12mm and anterior skeletal open bite from canine to canine of 5mm was present associated with anterior tongue thrusting habit and constricted upper arch. The molar relation was end-on on the right side and class II on left side. Canine relation was end-on, on both the side. Growth pattern was vertical. Upper arch was well aligned with constriction in premolar region; lower arch had a crowding of 6 mm. The treatment plan was selected as alignment of the teeth with fixed mechanotherapy and impaction of the maxillary posteriors using zygomatic anchorage with posterior bite block and spurs soldered to the anterior part of the appliance.



**Fig. 4:** Pre-treatment intra oral Photographs and radiographs.

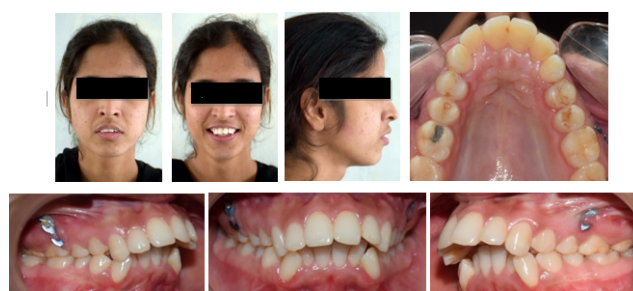### 3.2. Treatment objectives

The objectives included the closure of open bite by impaction of maxillary posteriors and correction of molar and canine relationship by retraction of the anterior teeth and auto rotation of mandible. All these to be achieved by zygomatic anchorage and alignment of the arches with fixed mechanotherapy.

### 3.3. Treatment progress

After placing the implant surgically and removal of sutures after 7<sup>th</sup> day the appliance is inserted, and force is applied through elastomeric chain from horizontal hooks to the hook of Zygomatic implant as in (Figure 3). The patient was observed on monthly intervals, and progress was noticed. The fixed appliance was not placed until the posterior intrusion and bite closure happened in 7 months. After the completion of intrusion (Figure 5), fixed mechanotherapy was started, and the intrusion was retained with the ligature wire tied to the appliance and to the hooks of intrusion plate replacing the elastomeric chain. Later on, after 7 months we bonded the teeth with M.B.T appliance 0.22 slot, Dento Smile of Dentos India pvt. Ltd., ORJ made in China.

Extraction of maxillary first premolars and mandibular single incisor was done. An initial 0.016-inch round nickel titanium arch wire was used for the levelling and the



**Fig. 5:** Improvement achieved after maxillary posterior intrusion for 7 months.

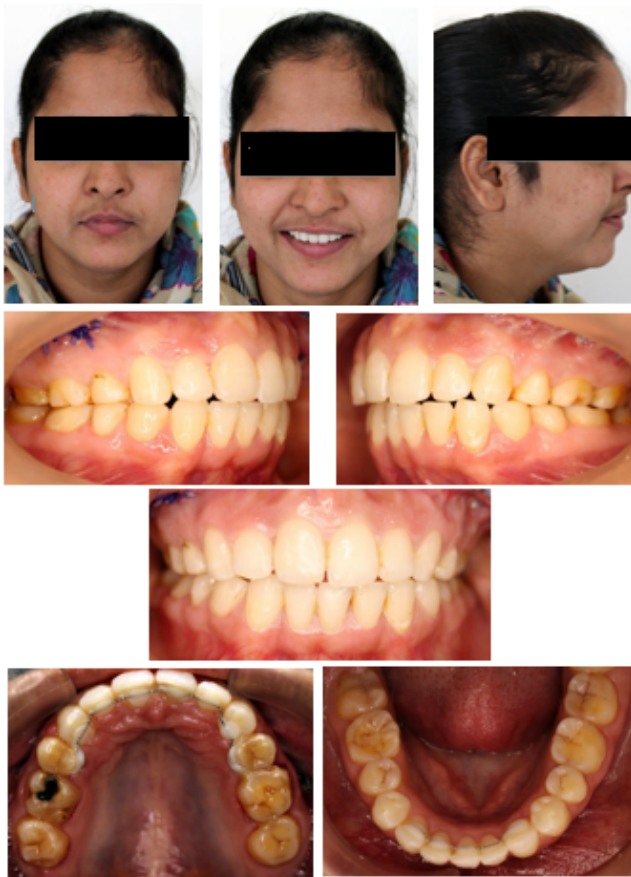alignment of both the arches. The upper and lower 0.016 x 0.022-inch NiTi were placed, which was later followed by the placement of 0.017 x 0.025-inch nickel titanium wires at 12 weeks. At the end of 16 weeks, enough levelling and aligning had occurred to place the upper and lower 0.019 x 0.025-inch SS wires. At the 20th week, en-mass retractions of the six anterior teeth were carried out by using active tiebacks. At the same time, utmost care was taken to prevent an undesirable mesial drift of the maxillary molars. As the camouflage treatment with two premolar extractions requires anchorage conservation and in order to reinforce our anchorage, we used an upper second molar banding and anchorage was further reinforced by using the zygomatic plates. After the closure of the 1st premolar extraction space, the extraction site was stabilized with a figure of eight ligation between the molars. A 0.016 nickel titanium arch wire was placed to level the arch, final settling of occlusion was done with proper interdigtation, inclination, angulation, ideal overjet and overbite. The case was debonded and retention was given by upper & lower fixed lingual retainers. Patient was advised to follow up in retention period.

### 3.4. Improvement achieved

With the intrusion of maxillary molars because of posterior bite blocks correction of anterior open bite was achieved (Figure 5) and tremendous improvement in tongue thrusting and anterior rest position of tongue because of spurs soldered to anterior part was achieved.

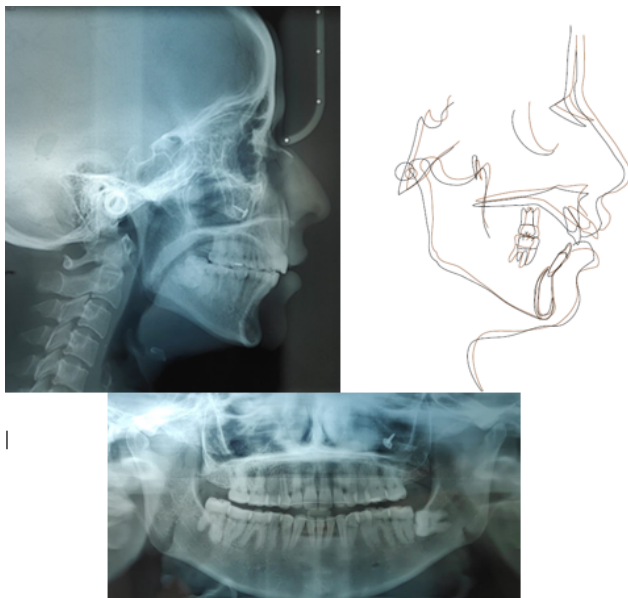
### 3.5. Post treatment assessment

Marked improvement in patient's smile and appearance, lip competence and a straight profile were achieved, improving the patient's facial appearance (Figure 6). Additionally, the dark vestibular spaces/ Buccal Corridor spaces and incisor visibility were reduced suggesting of expansion and Intrusion of the maxilla and dentoalveolar segment achieved in upper arch due to 0.9mm wire of VF appliance. A functional occlusion with normal overjet and overbite; Class II molar and Class I canine relationship (Figure 7) and better



**Fig. 6:** Post-Treatment Photographs.

cephalometric values (Table 1) was achieved. The entire duration of the treatment lasted for 48 months.



**Fig. 7:** Post Treatment Radiographs and superimpositions.

#### 4. Discussion

In this case the, the intrusion for anterior open bite could have been achieved with conventional method using zygomatic anchorage but the etiologic factor of tongue thrusting would have remained unaddressed. In this case we tried to focus on two issues by altering the appliance and adding the Spurs at the anterior part of it. It is well known that anterior open bite is difficult to treat and retain because it tends to relapse.<sup>1</sup> Crib acts just like a reminding appliance while spurs act as a reminding plus restraining appliance. In the case of Crib, continuous pressure of tongue may cause mesialization of maxillary first molar when it is soldered to maxillary first molar, worsening the Class II situation, while spurs work as reminding plus refraining appliance.

Some authors have feared about apical root resorption of molars due to intruding forces but it has been concluded as insignificant.<sup>6</sup> In three years follow up study by Haryett et al<sup>7</sup> they found a 91% success rate in arresting thumb-sucking habits when a cemented intraoral spur appliance was worn for 10 months compared to 64% success when used for only three months. Taking into account these results Justus<sup>1</sup> suggested that the spur appliance be nonremovable and remain in the mouth for at least 6 months after the Open bite has closed. But our appliance was not cemented though it is fixed to hook of Zygomatic implant through ligature wire.

We encountered the fear of impingement of spurs by the patient and her parents but as time passed, she adapted to the appliance. When cementing the Spur appliance, the patient and family should be informed that there is going to be initial discomfort to the patient in speaking, eating and swallowing and these problems are going to be resolved within 2 to 3 weeks.

#### 5. Conclusions

With all the work done on our patient it was found that our appliance has served two purposes –a) eliminating the tongue thrusting habit and anterior tongue rest posture through anterior spurs and b) intrusion of molars through posterior bite blocks.

Huang et al<sup>8</sup> demonstrated that anterior open bite malocclusions corrected with spurs have long term post retention stability. The advantage of our appliance after closure of anterior open bite is, we bonded the teeth with appliance inside the mouth.

With the initial apprehension of patient and her parents regarding Spurs we had smooth flow of treatment of the case.

We would like to conclude that with the peculiar design two objectives are achieved with one appliance, one is intrusion posterior teeth and the other one is containment of digit and tongue thrusting. The treatment of open bite is achieved rapidly within seven months.

**Table 1:** Cephalometric Records of the patient.

Parameter	Norms	Pre-treatment	Post-treatment
<b>Skeletal</b>			
SNA	82°	84°	78°
SNB	80°	74°	71°
ANB	2°	10°	7°
Wits	-1mm	4mm	3mm
GoMe-FH	28°	34°	32°
Tangent-FH	25°	39°	35°
Y-Axis	59.4°	66°	61°
Articulare Angle	145°	157°	152°
LAFH	68.6mm	63mm	61mm
<b>Dental</b>			
U1 – NA	4mm /22°	7mm/39°	2.5mm/18°
L1 – NB	4mm /25°	7mm/30°	7mm/29°
IMPA	90°	95°	94°
U6-NF	23.1mm	20mm	17mm
M6-MP	32.1mm	28mm	30mm
<b>Soft Tissue</b>			
S Line-U/L	0	0.5mm	-0.2mm
S line - L/L	0	-1.9mm	-2.8mm
Nasolabial Angle	104°	86°	107°

## 6. Source of Funding

None.

## 7. Conflict of Interest

None.

## References

- Justus R. Correction of anterior open bite with spurs: long-term stability. *World J Orthod.* 2001;2(3):219–31.
- Umali D, Wasundhara B. Implant-Supported Bite Blocks for Open Bite Correction in Adults. *J Indian Orthod Soc.* 2012;46(2):86–92. doi:10.5005/jip-journals-10021-1066.
- Erverdi N, Usumez S, Solak A. New generation open-bite treatment with zygomatic anchorage. *Angle Orthod.* 2006;76(3):519–26.
- Marzouk E, Abdallah E, El-Kenany W, Fata M. Zygomatic anchorage for molar intrusion in adult open-bite patients. *Egypt Orthod J.* 2012;41(6):1–21. doi:10.21608/eos.2012.78828.
- Erverdi N, Acar A. Zygomatic anchorage for en masse retraction in the treatment of severe Class II division 1. *Angle Orthod.* 2005;75(3):483–90. doi:10.1043/0003-3219(2005)75[483:ZAFEMR]2.0.CO;2.
- Ari-Demirkaya A, Masry MA, Erverdi N. Apical root resorption of maxillary first molars after intrusion with zygomatic skeletal anchorage. *Angle Orthod.* 2005;75(5):761–7. doi:10.1043/0003-3219(2005)75[761:ARROMF]2.0.CO;2.
- Haryett RD, Hansen FC, Davidson PO. Chronic thumb-sucking. A second report on treatment and its psychological effects. *Am J Orthod.* 1970;57(2):164–78.

- Huang GJ, Justus R, Kennedy DB, Kokich VG. Stability of anterior openbite treated with crib therapy. *Angle Orthod.* 1990;60(1):17–24.

## Author biography


**Fazal-ur-Raheman Chowdary**, Associate Professor

**Vishwanath S Patil**, Professor

**Basanagouda C Patil**, HOD and Professor

**Muhammed Faseehuddin**, Assistant Professor

**Akash Kencha**, Assistant Professor

**Abrar Younus A**, Private Practitioner  <https://orcid.org/0000-0002-5720-9185>

**Cite this article:** Chowdary FR, Patil VS, Patil BC, Faseehuddin M, Kencha A, Younus A A. An innovative approach for treatment of anterior open bite in Class II division 1 patient with zygomatic implant and spur assisted appliance - A case report. *IP Indian J Orthod Dentofacial Res* 2023;9(3):198-202.