

Content available at: <https://www.ipinnovative.com/open-access-journals>

IP Indian Journal of Orthodontics and Dentofacial Research

Journal homepage: <https://www.ijodr.com/>

Original Research Article

Comparison of predicted and actual treatment outcome based on steiner cephalometric analysis using nemotech software

Rigzing Lepcha¹, Rohit Khanna¹, Tripti Tikku¹, Sneha Lata Verma^{1,*},
Rana Pratap Maurya¹, Kamna Srivastava¹

¹Dept. of Orthodontics, Babu Banarasi Das College of Dental Sciences, BBDU, Lucknow, Uttar Pradesh, India



ARTICLE INFO

Article history:

Received 31-07-2022

Accepted 16-09-2022

Available online 27-10-2022

Keywords:

Prediction
Steiner Stick
Extraction
Incisor
Nemotech

ABSTRACT

Introduction: Social and psychological concerns, improved function, appearance, and self-esteem encourages a patient to pursue Orthodontic treatment, for which extraction may or may not be needed.

Conventionally steiner stick analysis or tweed head plate correction is followed to decide extraction during fixed orthodontic treatment for desirable treatment outcome. This study was designed to compare predicted position and angulation of maxillary and mandibular incisor by steiner stick analysis with the actual treatment outcome using nemotech software.

Materials and Methods : Sample was taken from our department consisting of pre and post treatment lateral cephalogram of 15 subject with age ranging from 20- 22years. Tracing was done using Nemotech software and values for Steiner's analysis was obtained, both for, pre and post treatment tracing. Prediction was done by Steiner Stick analysis(SSA) on the pre treatment tracing. The position and angulation of Maxillary and Mandibular incisor was compared between prediction based on SSA and post treatment outcome. The parameters taken were U1-NA Linear and U1-NA angular and L1-NB Linear and L1-NB angular and comparison were made using Paired Student T test.

Result: No significant difference was seen in U1-NA distance (in mm) and angulation(degree) Compared between predicted values(U1-NA- 2.478mm, 20.53 degree) and post treatment outcome (U1-NA-2.80mm, 22.733 degree) , $p>0.05$. Similarly no significant difference was seen in L1-NB distance (mm) compared between predicted (L1-NB 3.1227mm) and post treatment outcome(3.487 mm), $p>0.05$. However significant difference was seen for L1-NB angulation between predicted (22.573⁰) and actual post treatment outcome(26.02⁰), $p<0.05$.

Conclusion: Steiner Stick Analysis overestimated the values for angulation for Mandibular Incisors. This could be attributed to variability in mechanics or small size sample. Further studies should aim at comparisons done in larger sample size.

This is an Open Access (OA) journal, and articles are distributed under the terms of the [Creative Commons Attribution-NonCommercial-ShareAlike 4.0 License](https://creativecommons.org/licenses/by-nc-sa/4.0/), which allows others to remix, tweak, and build upon the work non-commercially, as long as appropriate credit is given and the new creations are licensed under the identical terms.

For reprints contact: reprint@ipinnovative.com

1. Introduction

Social and psychological concerns, improved function, appearance, and self-esteem encourages a patient to pursue Orthodontic treatment, for which extraction may or may not be needed. Conventionally Steiner Stick Analysis.¹⁻³

or Tweed Head Plate correction⁴ is followed to decide extraction during fixed Orthodontic treatment for desirable treatment outcome. The accuracy of prediction by these methods need to be assessed. Steiner Stick Analysis discuss the predetermination of anteroposterior position of the upper and lower incisors based on the appraisal of changes in the ANB angle and the position of the bony chin (Pg) to NB at the end of the treatment. Once the appraisal of the changes

* Corresponding author.

E-mail address: drsneh.lata@bbdu.ac.in (S. L. Verma).

in the ANB angle and the Pg-NB distance is put in place, the clinician can allude to a set of acceptable compromises for the incisor position to arrive at the so called 'settled' position. Finally, the treatment goal is individualized as these estimated values may be modified for individuals.

This study was designed to compare predicted position and angulation of Maxillary and Mandibular incisor by Steiner Stick Analysis with the actual treatment outcome using Nemotech software.

2. Materials and Methods

2.1. Sample

Sample was taken from record files of our department consisting of pre and post treatment lateral cephalogram of 15 subjects with age ranging from 20- 22 years. Informed consent from the patient and Ethical committee approval from the ethical committee of Babu Banarsi Das college of Dental Sciences, BBDU, Lucknow was taken.

2.2. Criteria for sample selection

2.2.1. Inclusion criteria

1. Adult patients (>18 yrs) to ensure complete growth of soft tissues.
2. Subjects with Class II Div 1 malocclusion or Class I Bimaxillary dentoalveolar protrusion who had undergone fixed orthodontic treatment after extraction of all 1st premolars.

2.3. Exclusion criteria

1. History of trauma in maxillofacial region.
2. Patients with congenital defect in craniofacial region or syndromes or any facial asymmetry.
3. Patients having history of previous orthodontic treatment orthognathic surgery.
4. Patients with abnormal morphology or size of nose, lip and chin region.

2.4. Armamentarium for the study

2.4.1. Material used for obtaining lateral cephalogram

1. Lateral cephalogram were taken from records file of the patient for whom cephalogram was taken from same machine in Department of Oral Medicine and Radiology.
2. Cephalostat machine: Planmeca proline XC cephalostat (Finland) machine were used to take digital lateral cephalograms of selected subjects. The exposure was set at 68KV, 5mA and exposure time was of 23 second. Pre and Post lateral cephalograms of each patient saved in CD-ROM were taken from the record files.

3. Nemoceph software: Nemoceph software (Dental studio version 6.0) was used to trace and analyze the lateral cephalogram uploaded on laptop.

2.5. Methodology

2.5.1. Methods of taking radiographs

Lateral cephalogram taken following standard protocol The lateral cephalograms were taken in natural head position with lips relaxed and teeth in centric occlusion. Subject was placed at a distance of 60 inches.(Figure 1). Soft copy of lateral cephalograms were transferred to a computer loaded with Planmeca software from where the digital lateral cephalograms were saved in bitmap files and taken in a CD ROM.

2.5.2. Transfer of soft copies of lateral cephalogram

The soft copies of all the lateral cephalograms were transferred to Nemotec software program (Dental studio-NX, version 6.0).(Figure 2)

2.5.3. Calibration of images

The images were calibrated by identifying two crosshairs 10 mm apart on lateral cephalogram using calibration tool of the software, both for pre and post treatment lateral cephalogram.

2.5.4. Identification of landmarks

The image enhancement feature of the software (basic an advanced cephalometric tools), like brightness, contrast adjustment and magnification were used to identify individual cephalometric landmarks as precisely as possible. The landmarks were marked with the help of mouse/cursor.

Following landmarks are used in the study (Figure 3)

1. Nasion (N): Most anterior point of the Nasofrontal suture in the midsagittal plane.
2. Point A: Deepest point in the midsagittal plane between the Anterior Nasal Spine and Prosthion.
3. Point B: Deepest point in the midsagittal plane between Infradentale and Pogonion. Most anterior point of the bony chin.
4. Following angular and linear parameters were measured on tracing with the help of the Nemotech software.(Figure 4)

Steiner Stick Analysis was done based on values as obtained for Steiner's Analysis in pretreatment tracing on Nemotech Software.

Steiners Prediction was compared with post treatment outcome.(Figure 6)

2.6. Data analysis

The mean and standard deviation for each of the cephalometric variable were taken from prediction based on

Steiner Stick Analysis and those achieved after treatment. Paired t-test was used to make adequate comparisons.

3. Observation and Results

From Table 1, it was observed that there was no significant difference was seen in U1-NA distance in mm and angulation in degree compared from predicted to post treatment as $p > 0.05$ for both when compared using Paired t test.

From Table 2, it was observed that there was no significant difference was seen in L1-NB distance in mm compared from predicted to Post treatment as $p > 0.05$ for both when compared using Paired t test but significant increase in L1-Nb angulation in degree was seen from predicted to post treatment as $p < 0.05$.

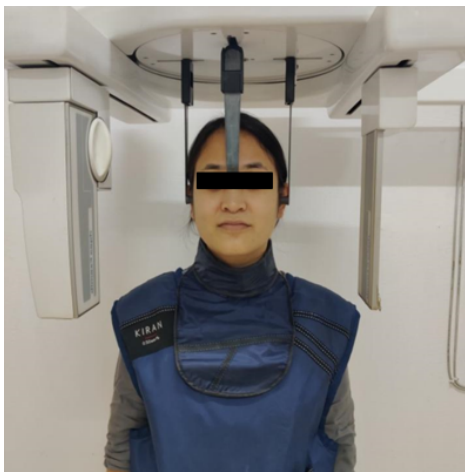

Fig. 1: Position of patient for taking lateralcephalogram.

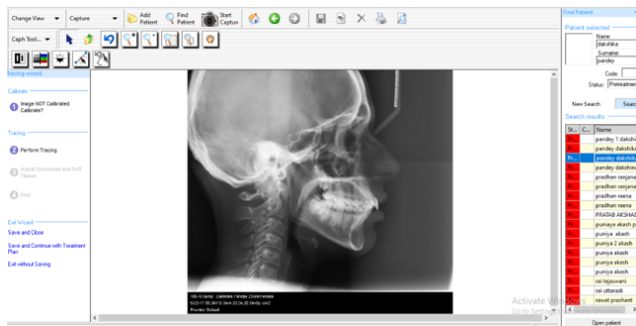


Fig. 2: Lateralcephalogram transferred to nemoceph software

4. Discussion

Most of the studies have evaluated the accuracy of prediction in orthognathic surgery cases⁵⁻⁹ but few evaluated[13] the accuracy of prediction case who had undergone fixed orthodontic treatment alone. These

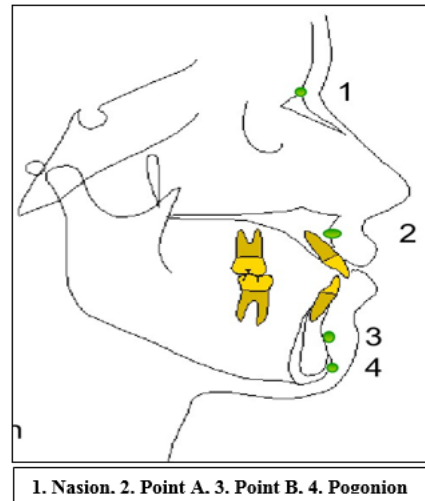


Fig. 3: Cephalometric landmark used in the study

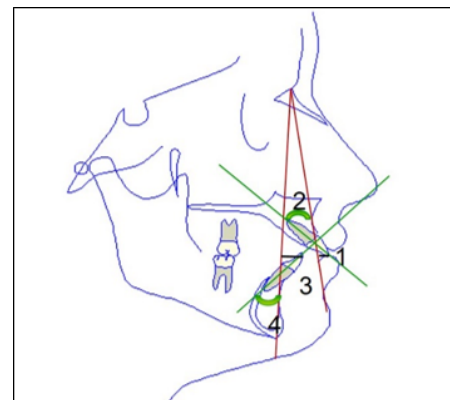


Fig. 4: Parameters used in the study.

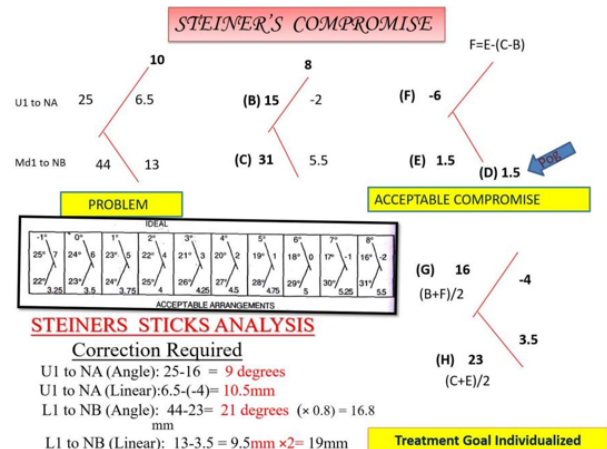


Fig. 5: Steiner stick analysis

Table 1: Predicted steiner stick analysis (PSSA)and post treatment outcome comparison of U1-NA

		Mean	Std. deviation	Std. Error mean	Mean difference	Std. deviation	P value
U1-NA mm	PSSA	2.4780	15	2.84794	.73533	-0.32	0.709
	POST			2.0877	.5390		
U1-NA mm	PSSA	20.53	15	2.774	.716	-2.2	0.116
	POST	22.733	15	4.6071	1.1895	5.0	

Table 2: Predicted steiner analysis (PSSA) an post treatment outcome comparison of L1-NB

		Mean	N	Std. deviation	Std. Error mean	Mean difference	Std. deviation	P value
L1-NB mm	PSSA	3.1227	15	1.93251	.49897	-0.36400	1.82005	0.451
	POST	3.487		1.4540	.3754			
L1-NB mm	PSSA	22.573	15	7.2537	1.8729	-3.4467	4.7949	0.015
	POST	26.020	15	7.1679	1.8507			

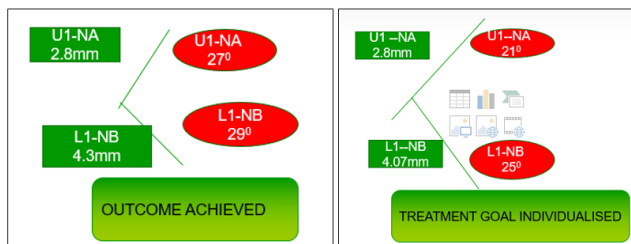


Fig. 6: Comparison of steiner stick prediction to actual post treatment outcome.

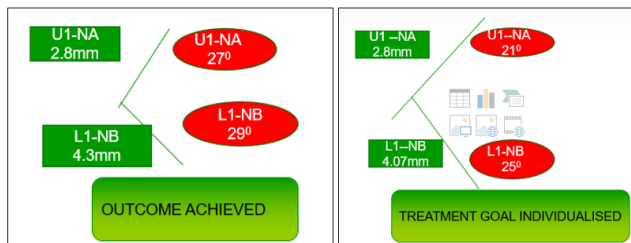


Fig. 7: Bar diagram showing maxillary incisors position and angulation

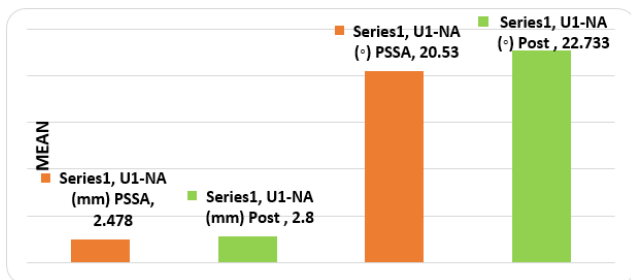


Fig. 8: Bar diagram showing mandibular incisors position and angulation

studies evaluated accuracy of prediction of Steiner Stick Analysis,¹⁰ manual and computerized¹¹ VTO¹² or morphing tool of digital cephalometric software. Determination of the treatment goal for an individual patient is very critical. One has to predict the changes in ANB the Pg NB distance during changes. The result of the present study show that the accuracy in predicting the values of the four variables at the end of the treatment is limited. Though position and angulation of Maxillary incisor, position of Mandibular Incisor was overestimated by SSA, but difference was statistically non significant in previous studies. Mandibular Incisor angulation was also overestimated and difference was statistically significant. (Figure 7).

Comparison with previous studies by Abdullah et al observed contrary result where U1-NA (linear in mm) and L1-NB (linear in mm) showed statistically significant difference between Steiner predicted value and actual post treatment outcome. Cangialosi et al⁶ found predicted value for Mandibular incisor position and angulation appeared to be inaccurate and overated for growing subject. The prediction of the other angles between anatomical planes was significantly accurate, however predicted of the Anteroposterior position and angulation of incisor were least reliable. (Figure 8)

Sample et al compared manual and computerized VTO forecast in growing subject and found significant difference for position and angulation of Maxillary Incisor by manual VTO and post treatment but showed insignificant difference for Mandibular Incisor position and angulation. Similar to our study it was general trend of overestimation in studies by Abdullah et al and Sample et al.

Steiner Stick Analysis helped in determining amount of space requirement in particular case to correct Maxillary and Mandibular Incisor position and angulation. However, it did not consider soft tissue profile of the patient. The overestimation by Steiner Stick Analysis could be due to the fact that retraction might have been stopped once

adequate changes in profile were achieved which might have been before achieving ideal hard tissue values of Steiner prediction.

Another limitation could be due to variability in orthodontic mechanics during the course of the treatment. Steiner Stick Analysis is quick, easy method of prediction possible on manual tracing and if used with careful correlation with soft tissue profile can help us in deciding amount of space required in orthodontic cases. Further, studies should aim at comparisons done in larger sample size.

5. Conclusion

Steiner Stick Analysis overestimated the values for angulation for Mandibular Incisors. This could be attributed to variability in mechanics or small size sample.

6. Source of Funding

None.

7. Conflict of Interest

None.

References

- Steiner CC. Cephalometrics for you and me. *Am J Orthod.* 1953;39:729–55. doi:10.1016/0002-9416(53)90082-7.
- Steiner CC. Cephalometrics in clinical practice. *Angle Orthod.* 1959;29(1):8–29. doi:10.1043/0003-3219(1959)029<0008:CICP>2.0.CO;2.
- Steiner CC. The use of cephalometrics as an aid to planning and assessing orthodontic treatment. *Am J Orthod.* 1960;46(10):721–35. doi:10.1016/0002-9416(60)90145-7.
- CHTweed. Clinical orthodontics. The C.V.Mosby company; 1996.
- Schultes G, Gaggl A, Kärcher H. Accuracy of cephalometric and video imaging program Dentofacial Planner Plus® in orthognathic surgical planning. *Comput Aided Surg.* 1998;3(3):108–14.
- Pektas ZO, Kircelli BH, Cilasun U, Uckan S. The accuracy of computer-assisted surgical planning in soft tissue prediction following orthognathic surgery. *Int J Med Robot.* 2007;3:64–71. doi:10.1002/rcs.127.
- Koh CH, Chew MT. Predictability of soft tissue profile changes following bimaxillary surgery in skeletal class III Chinese patients. *J Oral Maxillofac Surg.* 2004;62(12):1505–9. doi:10.1016/j.joms.2004.04.022.
- Aharon P, Eising S, Cisneros GJ. Surgical prediction reliability: a comparison of two computer software systems. *Int J Adult Orthodon Orthognath Surg.* 1997;12(1):65–78.
- Loh S, Heng JK, Ward-Booth P, Winchester L, McDonald F. A radiographic analysis of computer prediction in conjunction with orthognathic surgery. *Int J Oral Maxillofac Surg.* 2001;30(4):259–63.
- Abdullah RTH, Kuijpers MAR, Bergé SJ, Katsaros C. Steiner cephalometric analysis: predicted and actual treatment outcome compared. *Orthod Craniofac Res.* 2006;9(2):77–83. doi:10.1111/j.1601-6343.2006.00363.x.
- Cangialosi TJ, Chung JM, Elliott DF, Meistrell ME. Reliability of computer-generated prediction tracing. *Angle Orthod.* 1995;65(4):277–84. doi:10.1043/0003-3219(1995)065<0277:ROCPT>2.0.CO;2.
- L S, Sadowsky P, Bradley E. An evaluation of two VTO methods. *Angle orthod.* 1998;68(5):401–8. doi:10.1043/0003-3219(1998)068<0401:AEOTVM>2.3.CO;2.

Author biography

Rigzing Lepcha, Student

Rohit Khanna, Professor and Head

Tripti Tikku, Professor

Sneh Lata Verma, Reader

Rana Pratap Maurya, Reader

Kamna Srivastava, Reader

Cite this article: Lepcha R, Khanna R, Tikku T, Verma SL, Maurya RP, Srivastava K. Comparison of predicted and actual treatment outcome based on steiner cephalometric analysis using nemotech software. *IP Indian J Orthod Dentofacial Res* 2022;8(3):151-155.