

Content available at: <https://www.ipinnovative.com/open-access-journals>

IP Indian Journal of Orthodontics and Dentofacial Research

Journal homepage: <https://www.ijodr.com/>

Case Report

Orthosurgical management of an adult patient with severe Class-II malocclusion: A case report

Ashish Kamboj^{1,*}, SS Chopra², Nishant Sinha¹, Pritam Mohanty³, Chandan Misra⁴, Atul Bali⁵

¹Dept. of Orthodontics, Govt. Dental Centre, Leh, (UT of Ladakh), India

²Dept. of Dental Surgery, Armed Forces Medical College, Pune, Maharashtra, India

³Dept. of Orthodontics, KIDS, KIIT-DU, Bhubaneswar, Odisha, India

⁴Govt. Dental Centre, Leh, (Ut of Ladakh), India

⁵Army Dental Corps, India



ARTICLE INFO

Article history:

Received 02-03-2022

Accepted 10-03-2022

Available online 31-03-2022

Keywords:

Class II Malocclusion

Orthosurgical

BSSO

Mandibular Advancement

ABSTRACT

Class II malocclusion cases are of interest to orthodontist since they constitute a significant percentage of cases they treat. However, they are one of the most challenging malocclusions to diagnose and treat. There lies a significant difference in prevalence of Class II malocclusion among various populations. Prevalence of Class II malocclusion in India varies from 1.9% in Rajasthan to 8.37% in South India. Class II malocclusions have dental or skeletal or combination entities. Success in the management of skeletal Class II cases especially in the adult cases relies on proper diagnosis and treatment planning. The treatment of severe dentofacial deformities in adult patients is a challenging task for both the orthodontist and the maxillofacial surgeon. In adults with severe discrepancy, combined orthosurgical approach is the ideal way to achieve acceptable results. This case report presents an adult male patient with severe Class II malocclusion in which mandibular advancement was carried out with BSSO. Post-treatment results showed improved facial esthetics and Class- I relationship of the skeletal jaw bases with optimal dental occlusion.

This is an Open Access (OA) journal, and articles are distributed under the terms of the [Creative Commons Attribution-NonCommercial-ShareAlike 4.0 License](https://creativecommons.org/licenses/by-nc-sa/4.0/), which allows others to remix, tweak, and build upon the work non-commercially, as long as appropriate credit is given and the new creations are licensed under the identical terms.

For reprints contact: reprint@ipinnovative.com

1. Introduction

Class II malocclusion cases are of interest to orthodontist since they constitute a significant percentage of cases they treat. However, they are one of the most challenging malocclusions to diagnose and treat.

There lies a significant difference in prevalence of Class II malocclusion among various populations. Emmanuel¹ observed 1.1% prevalence in Nigerian, where as Silva et al² observed as high as 21.5% prevalence of Class II malocclusion in Latino adolescents. Prevalence of Class II malocclusion in India varies from 1.9% in Rajasthan to 8.37% in South India.^{3,4}

* Corresponding author.

E-mail address: aashishkamboj@gmail.com (A. Kamboj).

Class II malocclusions have dental or skeletal or combination entities. Furthermore, they can be attributed to maxillary prognathism, mandibular retrognathism or combination of both along with vertical and transverse problems. Success in the management of skeletal Class II cases relies on proper diagnosis and treatment planning. The treatment approach of skeletal Class II malocclusion depends upon the growth status of the patient. In adolescent cases, growth modulation with either removable or fixed myofunctional appliances to stimulate mandibular growth, head gear to restrict excessive maxillary growth or a combination approach is recommended.

However, in adults, esthetics is the major concern in severe Class II cases. The treatment of severe dentofacial

deformities in adult patients is a challenging task for both the orthodontist and the maxillofacial surgeon. Treatment is difficult because of the skeletal and facial disharmony, absence of jaw growth and a tendency to relapse.⁵ Critical diagnosis and ortho-surgical combination treatment approach is to be relied on for gaining optimum esthetic harmony and functional efficiency. Furthermore, acceptance of pleasing facial appearance is the prime importance factor in determining social relationship.⁶

2. Case Report

This case report describes a 20 years old male patient who reported to Orthodontic Department of a Government Dental Centre in Pune, Maharashtra, India with the chief complaint of forwardly placed upper front teeth.

2.1. Clinical examination

Extraorally, the patient exhibited square face with convex profile, incompetent lips and deep mentolabial sulcus (Figure 1). Intraorally, patient presented with Class II molar and canine relationship bilaterally, with proclined incisors, deep bite and increased overjet. Both the arches exhibited moderate spacing in the anterior teeth with deep curve of spee (Figure 2). Cephalometrically patient had skeletal Class II jaw bases on account of normal maxilla with retrognathic mandible and patient was in CVMI Stage-6 (Figure 3).

2.1.1. Problem list

1. Convex profile
2. Reduced nasolabial angle
3. Incompetent lips
4. Deep mentolabial sulcus
5. Spacing in upper arch and lower arch
6. Class-II molar & canine relation bilaterally
7. Increased overjet
8. Deepbite
9. Retrognathic mandible

2.1.2. Treatment objectives

The main objectives of the treatment were-

1. Improvement of facial esthetics
2. Achievement of straight facial profile
3. Achievement of lip competency
4. Correction of spacing in both the arches
5. Leveling and alignment
6. Correction of molar and canine relation
7. Correction of the underlying skeletal discrepancy

2.2. Treatment alternatives

There were two treatment alternatives, the first alternative was orthodontic treatment with dentoalveolar compensation

(Camouflage) using fixed orthodontic appliance. However, in this approach, the underlying skeletal problem of mandibular retrognathism couldn't be addressed. The second alternative was ortho-surgical treatment approach with bilateral sagittal split osteotomy with mandibular advancement.

Both treatment options were explained to the patient. As esthetics and overall facial appearance was the main concern, second treatment alternative was selected. This option would improve the existing profile and also reduce the severity of the mandibular retrognathism.

2.3. Treatment plan and progress

2.3.1. Presurgical orthodontic phase

Both maxillary and mandibular arches were banded and bonded using 0.22" MBT prescription and initially 0.014" NiTi wire was placed for levelling & alignment. After leveling and alignment of the upper and lower arches was complete (Figure 4), upper and lower anterior teeth space consolidation was carried out in 0.018" SS wire. Subsequently 0.019" X 0.025" NiTi wires were placed which were followed by 0.019" X 0.025" SS wires in both the arches. Patient's presurgical photographs (Figures 5 and 6) and radiographs were recorded again, then the case was re-evaluated. Prediction tracing was done (Figure 7), Mock surgery was carried out and surgical splint was fabricated (Figure 8). 0.021" X 0.025" stainless steel wires with soldered interproximal spurs were ligated in the maxillary and mandibular arches at the end of presurgical phase.

2.3.2. Surgical phase

The orthognathic BSSO surgery (Figure 9) was carried out with 7mm mandibular advancement to correct anteroposterior skeletal discrepancy. The surgical splint was then used to position & stabilize the mandible with the help of I-plates (Figure 10).

2.3.3. Postsurgical orthodontic phase

Four weeks post surgery the stabilizing archwires & splint were removed. Post-surgical occlusal settling was started in 0.014" Australian super plus wires in upper and lower arches and short Class II elastics (3/16") were administered in rectangular fashion (Figure 11). After ensuring the achievement of all intended goals, fixed orthodontic appliance was removed. Patient was then given upper Hawley's and lower FSW retainer.

2.3.4. Treatment results

Excellent facial and occlusal results were achieved. Significant improvement of the facial profile was appreciated (Figure 12). Intraorally, bilateral Class I molar and canine relation was achieved with normal overjet and overbite relation (Figure 13). Deep mentolabial sulcus

Table 1: Cephalometric reading

Parameters	Pre-Treatment	Pre-Surgical	Post-Treatment
SNA	81°	80°	80°
SNB	74°	74°	78°
ANB	7°	6°	2°
GoGn–SN	29°	30°	32°
Angle of Convexity	7°	3°	1°
SN-MP	28°	29°	31°
FMA	22°	23°	25°
Y-Axis	54°	56°	58°
LAFH	54mm	55mm	59mm
Co-Gn	116mm	116mm	123mm
U1-NA	53° (17mm)	24° (4mm)	22° (4mm)
L1-NB	25° (5mm)	26° (4mm)	27° (4mm)
Jarabak ratio	65%	64%	62%
IMPA	100°	98°	98°

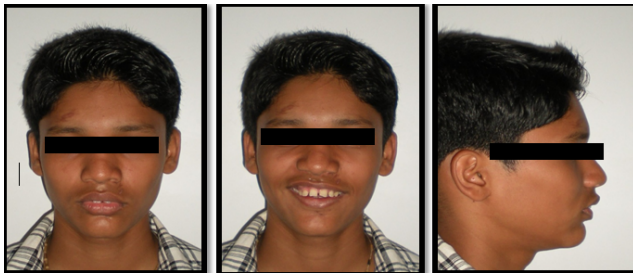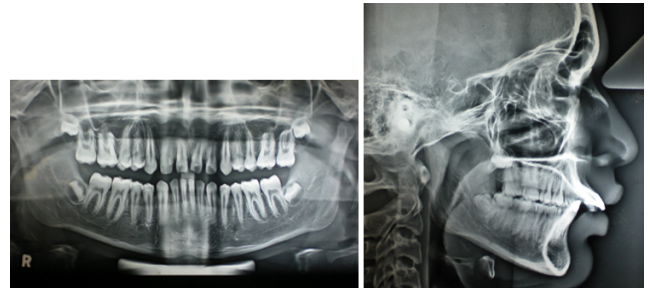
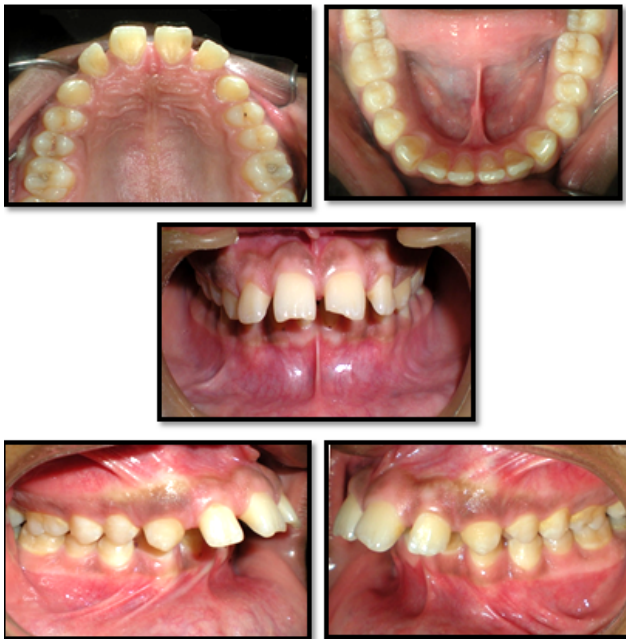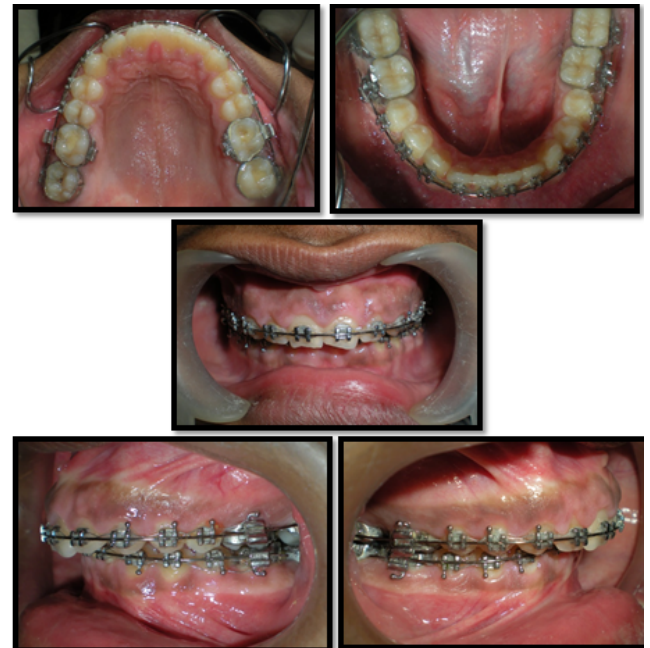**Fig. 1:** Pretreatment extraoral photographs**Fig. 3:** Pretreatment OPG & lateral cephalogram**Fig. 2:** Pretreatment intraoral photographs**Fig. 4:** Levelling and alignment complete



Fig. 5: Presurgical extraoral photographs

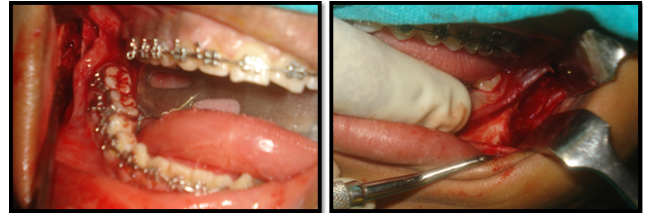

Fig. 9: Bilateral sagittal split osteotomy

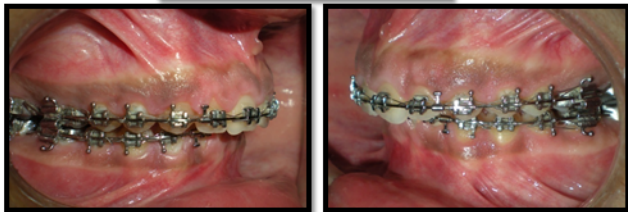
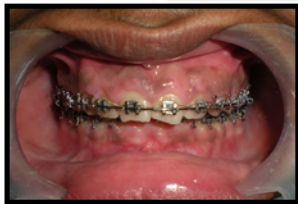
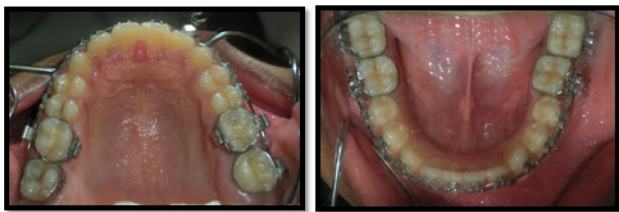
Fig. 6: Presurgical intraoral photographs

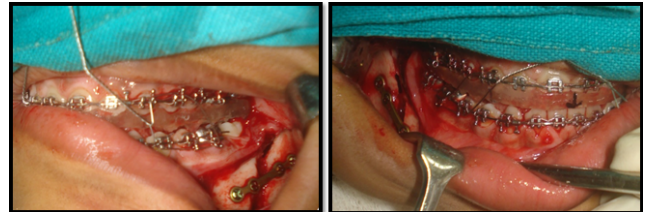


Fig. 10: Rigid internal fixation

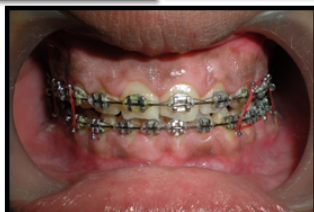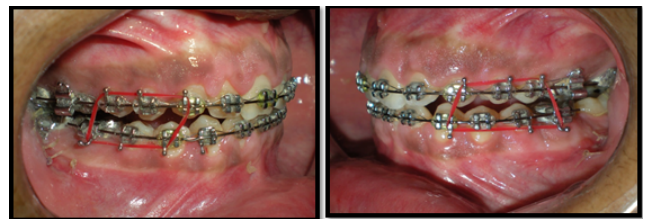


Fig. 11: Post surgical settling



Fig. 7: Presurgical prediction tracing




Fig. 8: Model surgery & splint fabrication



Fig. 12: Post treatment extraoral photographs

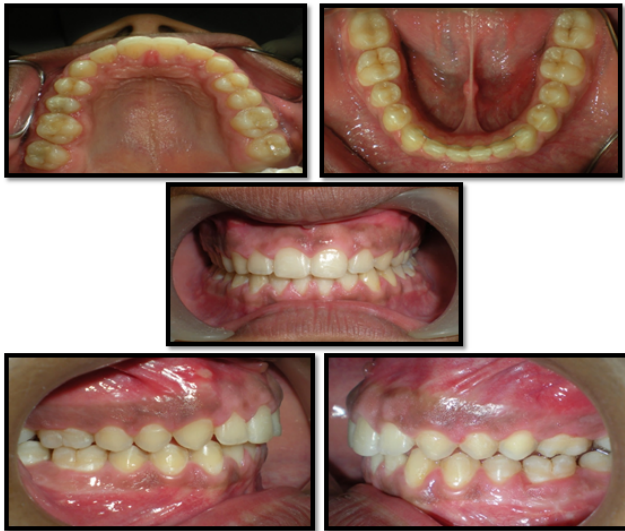

Fig. 13: Post treatment intraoral photographs

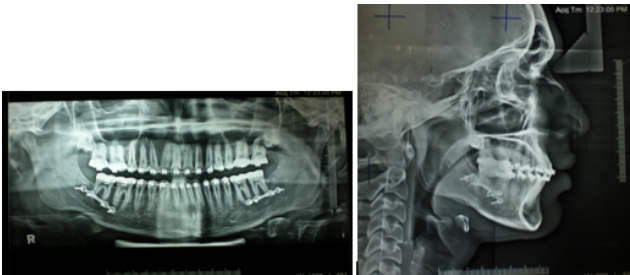


Fig. 14: Pre debonding OPG & lateral cephalogram

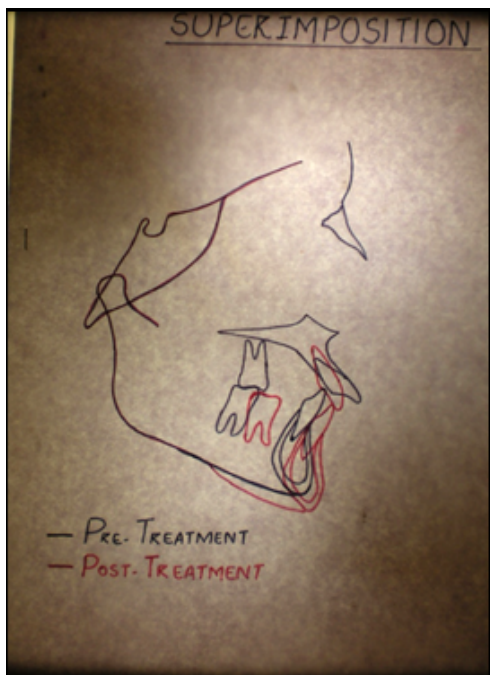


Fig. 15: Pre and post treatment cephalometric superimposition

was corrected. Mandibular retrognathism was improved from ANB 7° TO ANB 2° (Table 1). Post treatment radiographs before debonding (Figure 14) showed increase in lower anterior facial height and correction of mandibular retrognathism. (Figure 15) shows pretreatment and post treatment cephalometric superimposition. Overall, the treatment results were achieved as estimated during the treatment planning stage.

3. Discussion

Class II malocclusion can be corrected depending on the growth status and severity of the case. In adolescents, orthodontic correction can be carried out using removable/ fixed functional appliances.⁷ However, in adult patients' correction is done by orthodontics alone (Camouflage) or orthodontic-surgical combination. Orthognathic surgery is indicated when dental discrepancy cannot be corrected by orthodontic treatment alone or when facial esthetics is compromised. Many adult cases exhibiting severe skeletal Class II Div 1 malocclusion with mandibular retrognathism treated successfully with BSSO have been reported.^{8,9} Cases in whom mandibular advancement is carried out with BSSO are quite stable on long term basis with minimal to moderate relapse.^{10,11}

In the present case, an adult case of severe skeletal Class II Div1 malocclusion was treated with orthodontic-orthognathic combination. The treatment was focused to relieve upper anterior proclination, correct skeletal antero-posterior discrepancy and improve facial esthetics. Post-treatment results showed improved facial esthetics and dental occlusion. Convex facial profile and deep mentolabial sulcus were corrected and anterior vertical facial height was increased along with the correction of mandibular retrognathism.

4. Conclusion

Treatment of severe skeletal Class II Div-1 malocclusion in adult patients is a challenging task and a combined orthodontic-surgical approach can be used to obtain optimum esthetics & functional efficiency in these types of patients.

5. Conflict of Interest

None.

6. Source of Funding

This research did not receive any specific grant from funding agencies in the public, commercial, or not-for-profit sectors.

References

1. Emmanuel OA. Prevalence of malocclusion among school children in Benin City. *Nigeria J Med Biomed Res.* 2008;7(1-2):58–65.
2. Silva RG, Kang DS. Prevalence of malocclusion among Latino adolescents. *AM J Orthod Dentofacial Orthop.* 2001;119(3):313–5.
3. Trehan M, Chugh VK, Sharma S. Prevalence of malocclusion in Jaipur, India. *Int J Clin Pediatr Dent.* 2009;2(1):23–5. doi:10.5005/jp-journals-10005-1036.
4. K, Pavithra US, Abraham R. Prevalence of Malocclusion among adolescents in South Indian. *J Int Soc Prev Comm Dent.* 2013;3(2):97–102.
5. Wieslander L, Logerstrom L. The effect of activator treatment on Class II Malocclusion. *Am J Orthod.* 1979;75(1):20–6. doi:10.1016/0002-9416(79)90136-2.
6. Mcnamara JA, Bookstein FL, Shaugnessy TG. Skeletal and dental changes following functional regular therapy on Class II patient. *Am J Orthod.* 1985;88(2):91–110. doi:10.1016/0002-9416(85)90233-7.
7. Agarwal L, Singh K, Tandon R. Treatment of Class II Div 2 malocclusion using powerscope: A case report. *Orthodontic J Nepal.* 2018;8(1). doi:10.3126/ojn.v8i1.21352.
8. Hanumanth K, Krishnanayak US. Surgical Orthodontic Treatment of skeletal Class II malocclusion. *J Scientific Dent.* 2013;3(1):35–44.
9. Mohite A, Krishnanayak R, Patankar, Pawar S, Singh V. Bilateral Saggital split osteotomy and genioplasty; A case report. *J Dent Med Sc.* 2017;16(1):119–22. doi:10.9790/0853-160103119122.
10. Paunonen J, Helminen M, Peltomaki T. Long term stability of mandibular advancement with bilateral sagittal surgery. *J Cranio-Maxillary Surg.* 2018;46(9):1421–6.
11. Mulier D, Romero LG, Führer A, Martin C, Shujaat S, Shaheen E, et al. Long term dental stability after orthognathic surgery:A Systematic Review. *European J Orthod.* 2021;43(1):104–112.

Author biography

Ashish Kamboj, Orthodontist

SS Chopra, Professor

Nishant Sinha, Endodontist

Pritam Mohanty, Professor

Chandan Misra, Oral & Maxillofacial Surgeon

Atul Bali, Orthodontist

Cite this article: Kamboj A, Chopra SS, Sinha N, Mohanty P, Misra C, Bali A. Orthosurgical management of an adult patient with severe Class-II malocclusion: A case report. *IP Indian J Orthod Dentofacial Res* 2022;8(1):54-59.