

Content available at: <https://www.ipinnovative.com/open-access-journals>

IP Indian Journal of Orthodontics and Dentofacial Research

Journal homepage: <https://www.ijodr.com/>

Review Article

Cephalometric superimposition in orthodontics-A review

Nidhi Agrawal^{1,*}, Surbhi Gupta², Soumya Gupta¹, Shabana Nazmeen³,
Deepkesh Bhuyan⁴, Gangesh B Singh⁵

¹Dept. of Orthodontics and Dentofacial Orthopedics,, New Horizon Dental College and Research Institute, Bilaspur, Chhattisgarh, India

²Dept. of Orthodontist, Prime Hospital, Nagpur, Maharashtra, India

³Consultant Orthodontics, Bhilai, Chhattisgarh, India

⁴Dept. of Orthodontics, Hi-Tech Hospital, Bhubaneswar, Odisha, India

⁵Dept. of Orthodontics, Government Dental College, Raipur, Chhattisgarh, India



ARTICLE INFO

Article history:

Received 08-01-2022

Accepted 21-01-2022

Available online 31-03-2022

Keywords:

Cephalometrics

Superimposition

Lateral cephalograms

Growth

ABSTRACT

Superimposition is a method where serial cephalometric radiographs or tracings are taken for the same patient at different time intervals that is before, during and after treatment and superimposed on the biologically defined plane or surface to study changes in jaw and tooth positions respectively as a result from growth, treatment or a combination of two. With the progress of the orthodontic treatment as well as growth, detailed follow-up is important to monitor the changes from the treatment mechanics applied in order to enhance the dental and jaw function and dentofacial esthetics of an individual. The article aims at presenting a comprehensive review on the various methods of superimposition for proper evaluation of changes occurring in an individual following growth and treatment.

This is an Open Access (OA) journal, and articles are distributed under the terms of the [Creative Commons Attribution-NonCommercial-ShareAlike 4.0 License](https://creativecommons.org/licenses/by-nc-sa/4.0/), which allows others to remix, tweak, and build upon the work non-commercially, as long as appropriate credit is given and the new creations are licensed under the identical terms.

For reprints contact: reprint@ipinnovative.com

1. Background

Change in direction of jaw growth and tooth movement due to various orthodontic, orthopaedic, and surgical procedures can be properly analysed by superimposing tracings of serial lateral cephalograms which provides information about normal craniofacial growth and development as well as knowledge about the treatment effects produced. The comparison of cephalometric headfilms taken at intervals is the method used by the researchers and clinicians, which requires at least a working knowledge of sites and areas of skeletal growth. To determine the effect of growth and treatment, tracings of the headfilms are superimposed on the landmarks least affected by growth. However, none of the cephalometric superimpositions are completely accurate,

they serve as a valuable purpose in permitting an overall evaluation of change that has occurred due to growth or treatment.

2. Introduction

During the last 100 years, orthodontics has progressed from being a simplistic treatment modality for aligning teeth to a science of therapeutic intervention. With the introduction of radiographic cephalometry by Broadbent (USA) and Hofrath (GERMANY) 1931, facial changes that accompany growth and/or orthodontic treatment were better understood.¹ An added bonus of cephalometrics is its usage in assessing the changes in the skeleton, dentition and soft tissues over a period of time can be monitored by superimposition. A cephalometric superimposition is an analysis of lateral cephalogram of a same patient taken at

* Corresponding author.

E-mail address: nidhi.agrawal1610@gmail.com (N. Agrawal).

different times. The process includes placing two images upon each other, registering on structures that are relatively stable.² The purpose of superimpositions is to aid the orthodontist in determining the skeletal and dental changes that occur over time.

The cephalometric superimposition is implied over many aspects and applications in orthodontics as it helps to improve one's understanding of what happens during treatment, separate growth changes from dento-alveolar alteration, aids to localize and specify the effects of treatment due to growth modulation appliances both skeletal and dento-alveolar and fixed appliance technique (dental changes mainly) and also used to evaluate a patient's growth pattern between different ages. Cranial base superimposition is considered essential for assessment of the growth and treatment changes of the facial structures, to understand the amount and direction of maxillary and mandibular growth or displacement, for studying changes in maxillary-mandibular relationships and soft tissue (nose, lips, and chin) as well as overall displacement of the teeth.

The growth of the face occurs in all three dimensions, at different rates and sites with its structures changing their relative spatial positions in space with time. Some cranial structures establish their relative size and form early in life than the others, which may continue to actively grow till adulthood.³ The cranial base was considered stable since majority of the growth of the anterior cranial base, i.e. 90—95% was thought to be complete at 7 years of age. In order to facilitate identification of consecutive cephalograms the following color code has been suggested by the American Board of Orthodontists (1990): black is used for pretreatment, blue for progress of treatment, red signifies end of treatment and green indicates retention phase.⁴

3. Superimposition Methods

3.1. Broadbent triangle

The method introduced by Broadbent in 1931, in which the triangle is formed by joining Nasion, Sella, and Bolton point. A perpendicular is drawn from Sella to Na-Bo plane and its mid point is called Registration point [R]. (Figure 1) Two tracings are oriented such that they are superimposed at R points and the Bolton planes (Bo-Na) are parallel to each other (Broadbent, 1931).⁵

3.2. Sella-nasion line

American Board of Orthodontics (1990) recommended to orient two tracings on the Sella-Nasion line with registration at Sella. The method accurately describe linear growth changes at Nasion, but it incorporates those areas of the cranial base that continue to change during most of the growing years. (Figure 2)

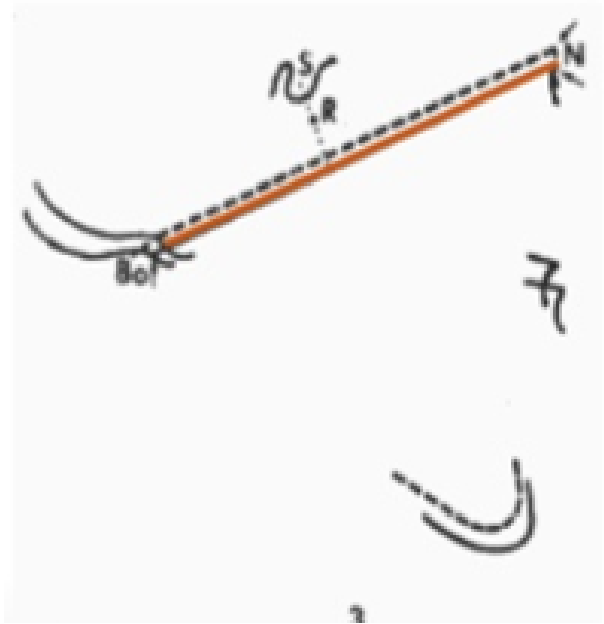


Fig. 1: Broadbent triangle

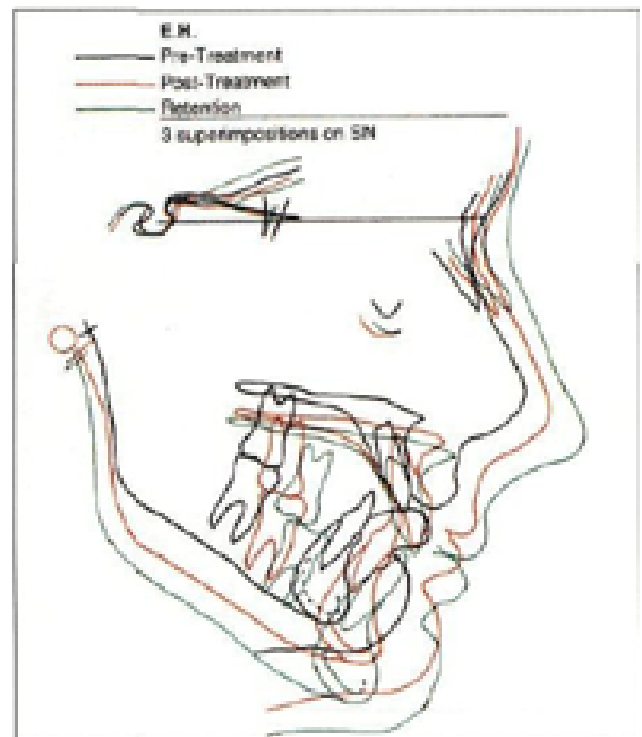


Fig. 2: Sella-Nasion Line

3.3. Basion horizontal

The concept was presented by Coben.⁶ The Basion Horizontal is a plane constructed at the level of the anterior border of the Foramen Magnum parallel to Frankfort horizontal. This line from Basion drawn parallel to the original Frankfort horizontal, establishes the constant SN-FH relationship and the Basion Horizontal plane of the series. For the analysis of craniofacial growth, superimposition of two tracings is done at Basion (as the point of reference). Serial tracings registered at Basion are oriented such that S-N planes are parallel.(Figure 3)

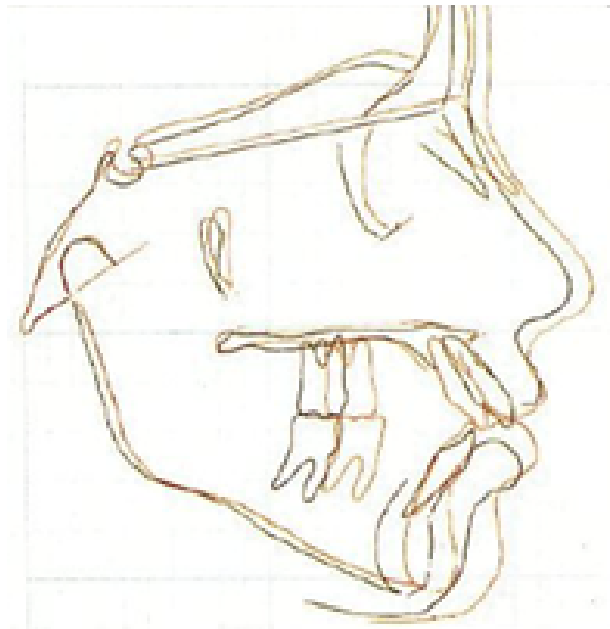


Fig. 3: Basion Horizontal

3.4. Basion-nasion plane

Ricketts (1979)⁷ suggested use of Basion-Nasion plane with registration at CC point for overall evaluation of the dentofacial changes. The plane allows to evaluate changes in facial Axis (BA-CC-GN), direction of chin growth, upper molar position. The methods of overall superimposition on S-N or BA-N lines have a low degree of validity, and high degree of reproducibility. As Nasion, Sella, and Basion move during growth due to remodeling on the anterior border of the Foramen Magnum and displacement of the occipital bone and growth in the spheno-occipital synchondrosis. Changes at S-N plane occurs due to forward displacement of Nasion during remodeling, enlargement of the frontal sinus, and hence upward or downward migration of the Frontonasal Suture and growth at the Spheno-occipital Synchondrosis.

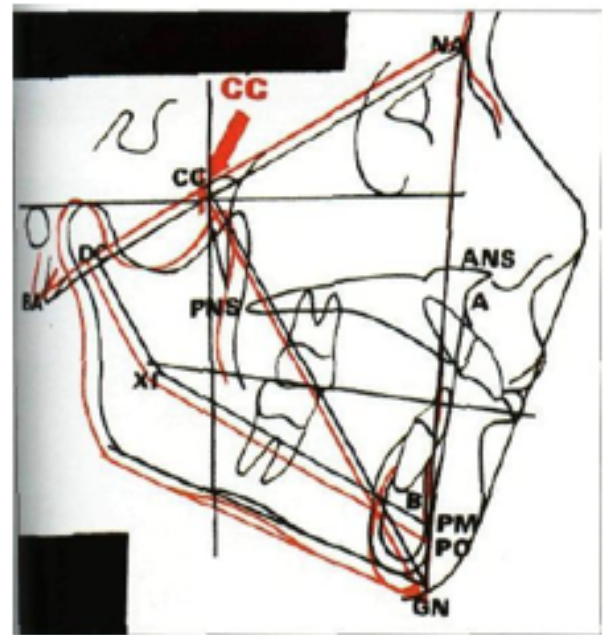


Fig. 4: Basion-Nasion plane

3.5. Reference structures for overall face superimpositions

Nelson⁸ (1960) and Melsen⁹ (1982) identified various bony surfaces that undergo relatively minimal alterations during the growth period suitable for accurate superimpositions. These structure are known as stable structures or reference structures.

3.6. Assessment of changes in teeth position

In order to assess the changes in the position of the teeth within the maxilla or mandible.

3.7. Maxillary superimpositions

The purpose of maxillary superimpositions is to evaluate the movement of the maxillary teeth in relation to the basal parts of the maxilla. Most of methods of maxillary superimpositions use palatal plane as reference plane. Registration on either ANS or PNS is unreliable as both the points undergo significant antero-posterior remodeling and registration on hard palate is also unreliable as it undergoes continuous resorption on its nasal surface and apposition on the oral side. Various methods for superimposing the maxillary structures are palatal plane registered at anterior nasal spine, nasal floors registered at the anterior surface of the maxilla, palatal plane registered at the pterygomaxillary fissure, infratemporal fossa and the posterior portion of the hard palate, basion horizontal registered at ptm co-ordinate, best fit of the internal palatal structures and structural

superimposition on the anterior surface of the zygomatic process of the maxilla.

3.8. Structural method of superimposition Bjork and Skieller (1977)

The method utilized anterior contour of the zygomatic process of the maxilla as registration point and 2nd film is oriented such that the resorptive lowering of the nasal floor is equal to the apposition at the orbital floor. The structural method of maxillary superimpositions has a medium to high degree of validity and low degree of reproducibility.¹⁰ Zygomatic process of the maxilla is characterized by double structures, which makes it difficult to identify accurately and hence to trace the construction line.(Figure 5)

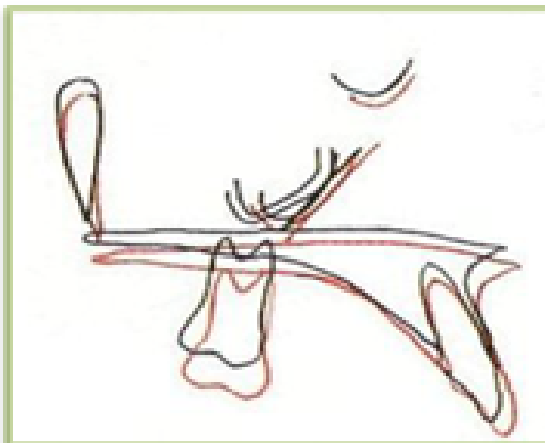


Fig. 5: Structural method

Process : Trace the anterior contour of the zygomatic process and construct a line that is tangential to it. Trace the contour of the palate, maxillary first molar, most labially positioned central incisor, floor of the orbit, N-S line, and the construction line. Superimpose the tracing on each other on the construction line. Move the superimpositions so that the amount of resorption at the nasal floor is equal to the apposition at the floor of the orbit. Stabilize the tracings together. The amount of maxillary rotation can be estimated from the two N-S lines.

3.9. Best fit method

McNamara in 1981 described BEST FIT METHOD for superimposition of maxilla made on the nasal and palatal surfaces of the hard palate in an area that is not significantly influenced by incisor tooth movement. It is used when the details of the zygomatic process of the maxilla are not clearly identifiable.

Process: Trace the outline maxillary structures palate, first permanent molars, entrance of the incisal canal and most labially positioned central incisor on the two

consecutive cephalograms, using the appropriate colours. Place the second tracing over the first one and adjust it to have the following structures arranged in a best fit alignment: the contour of the oral part of the palate, the contour of the nasal floor and the entrance of the incisal canal. Stabilize the two cephalograms together by means of a tape.

The purpose of mandibular superimpositions is to evaluate the movement of the mandibular teeth in relation to the basal parts of the mandible. Salzmann (1972)¹¹ has suggested number of areas for superimpositions: lower border of the mandible, tangent to the lower border of the mandible, mandibular plane between Menton and Gonion.(Figure 6) However, these methods are not very accurate in describing the changes within the mandible itself, as significant remodelling occurs at mandibular border (Bjork, 1963).¹²

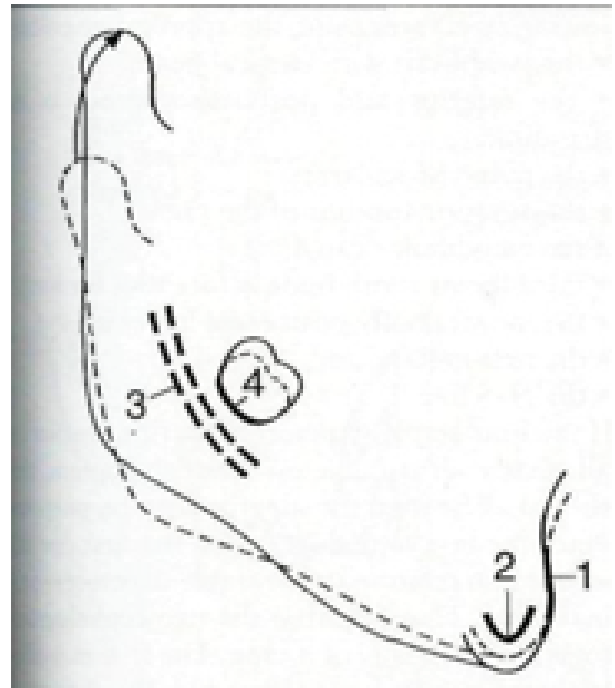


Fig. 6: Mandibular superimpositions

3.10. Stable structures method

Bjork and Skieller (1983) have indicated that the anterior contour of the chin, the inner contour of the cortical plates at the inferior border of the symphysis, the contours of the mandibular canal and lower contour of a mineralized molar germ are relatively stable and could be used for superimposition purposes.

Process: Trace the following structures using the appropriate colors on both cephalograms, symphysis with the inner cortical bone, inferior and posterior contour of the

mandible, articulare point, anterior contour of the ramus, mandibular canal, first molars, most labially positioned lower incisor; and third molar tooth buds before root formation (if present). Stabilize the cephalogram together in relation to the stable structures. By superimposing 2 cephalograms tracing, the growth pattern of the mandible can be estimated. When the stable structures that are intended to be used for superimposition are not easily identifiable, the lower border of the mandible can be used for orientation purposes.

3.11. Evaluation of amount and direction of condylar growth and evaluation of mandibular rotation

Condylar growth can be evaluated from the mandibular tracing if the head of the condyle can be clearly identified. Previously mentioned structures along with the N-S line are traced using the appropriate colors. Four stable structures described earlier if all clearly identifiable on the cephalogram, they should all be used for superimposition purposes. Place the last cephalogram on the first one and adjust it in relation to the stable structures of mandible. Then stabilize the two cephalograms together by means of a tape. The true mandibular rotation can be evaluated by the changes in the N-S lines. The angle expresses the amount of mandibular rotation.

3.12. Studies comparing different superimposition methods

You and Hagg¹³ (2000) conducted a study to compare the reliability of three superimposition methods: Björk's structural, Ricketts' four-position, and Panchez's method before and after Herbst treatment and found that all three methods were equally reliable and there was no significant difference among the three superimposition methods to evaluate the sagittal skeletal and dental changes. Yan and McNamara (2008)¹⁴ conducted a study to test the hypothesis that there is no difference between the information produced by superimposition of serial lateral headfilms on anatomical structures and that produced by superimposition on metallic implants according to the protocols of Björk. Results showed that the ABO maxillary superimposition method underestimates the vertical displacement and overestimates the forward movement of maxillary landmarks. Superimposing on the internal cortical outline of the symphysis and the inferior alveolar nerve canals generally approximates the mandibular superimposition on implants, although the lower anterior border of the symphysis may be a preferable area of superimposition. Superimposition on the lower border of the mandible does not reflect accurately the actual pattern of growth and remodelling of the mandible.

Huja et al. (2009)¹⁵ determined the ability to produce comparable superimpositions using hand tracing and digital

methods (Dolphin v10) & determined if a difference existed between the best-fit cranial base superimposition and S-N superimpositions using the digital method. This study validates the use of superimpositions produced by Dolphin Imaging version 10 and is a necessary step forward toward widespread acceptance of digital superimpositions. Lenza et al. (2015)¹⁶ investigated Björk structural method, Steiner/Tweed SN line, Ricketts N-Ba line at N-point and Ricketts N-Ba line at CC-point methods of cephalometric superimposition by means of assessing the longitudinal changes in craniofacial morphology caused by growth and response of adolescents with Class I malocclusion to orthodontic treatment involving first premolar extraction. They found that methods were reliable and presented similar precision when the overall facial changes due to active growth and/or orthodontic treatment were examined. Annie and Sundareswaran (2018)¹⁷ compared post-treatment effects following twin block appliance therapy, using three superimposition methods (Ricketts, Panchez and Centrographic), and concluded all three superimposition methods proved equally reliable.

3.13. 3D superimpositions

Two dimensional (2D) techniques suffer from flaws such as patient head position error, magnification error, geometric distortions and beam divergence. During the past decade, three dimensional (3D) technique is becoming more popular among orthodontist for diagnosis, treatment planning, surgical simulation and superimposition. CBCT images allows 3D evaluation of growth changes, treatment effects and stability of an individual with more accuracy.

4. Conclusion

Cephalometric superimposition has been extensively used to assess growth and treatment changes since its introduction and have been a main research tool in the hands of orthodontists. Growth & treatment changes occur in all the three dimensions of bony structures which cannot be precisely evaluated on a 2D radiograph. Three dimensional cephalometric superimposition can also be carried out for diagnosis and orthodontic treatment assessment: (1) voxel based, (2) landmark based and (3) surface based. The 3D visualisation and volume rendering images obtained through CBCT has opened up new vistas of studies in craniofacial morphology and studies on growth.

5. Conflict of Interest

None.

6. Source of Funding

This research did not receive any specific grant from funding agencies in the public, commercial, or not-for-profit sectors.

References

- Ricketts RM, Bench RW, Gugino CF, Hilgers JJ, Schullof RJ. Bioprogressive Therapy. Rocky Mountain Orthodontics; 1980.
- Jacobson A, Jacobson R. Radiographic cephalometry. Chicago: Quintessence Pub; 2006.
- Kharbanda OP. Cephalometric superimpositions In: Orthodontics. 2nd edn. vol. 2013. India: Elsevier; p. 273-89.
- Athanasiou A. Orthodontic cephalometry. 1st ed. London: Mosby-Wolfe; 1995. p. 105-25.
- Broadbent BH. Bolton standards and technique in orthodontic practice. *Angle Orthod.* 1937;7(4):209-33. doi:10.1043/0003-3219(1937)007<0209:BSATIO>2.0.CO;2.
- Coben SE. Basion Horizontal coordinate tracing films. *J Clin Orthod.* 1979;13(9):598-605.
- Ricketts RM, Bench RW, Gugino CF, Hilgers JJ, Schulhof RJ. Bioprogressive Therapy. Rocky Mountain Orthodontics: Denver. Colorado; 1979.
- Nelson TO. Analysis of facial growth utilizing elements of the cranial base as registrations. *Am J Orthod.* 1960;46:379.
- Melsen B, Melsen F. The postnatal development of the palatomaxillary region studied on human autopsy material. *Am J Orthod.* 1982;82(4):329-42. doi:10.1016/0002-9416(82)90467-5.
- Kristensen B. Cephalometric Superimposition: Growth and Treatment Evaluation. The Royal Dental College: Aarhus; 1989.
- Salzmann JA. Orthodontics in Daily Practice. JB Lippincott: Philadelphia; 1972.
- Bjork A. Variations in the growth pattern of the human mandible: Longitudinal radiographic study by the implant method. *Dent Res.* 1963;42(1):400-11. doi:10.1177/00220345630420014701.
- You QL, Hagg U. A comparison of 3 superimposition methods. *Eur J Orthod.* 1999;21(6):717-25. doi:10.1093/ejo/21.6.717.
- Gu Y, McNamara J. Cephalometric Superimpositions. *Angle Orthod.* 2008;78(6):967-76.
- Huja SS, Grubaugh EL, Rummel AM, Fields HW, Beck FM. Comparison of hand-traced and computer-based cephalometric superimpositions. *Angle Orthod.* 2009;79(3):428-35.
- Lenza MA, Carvalho AA, Lenza EB, Lenza MG, Torres HM, Souza JB, et al. Radiographic evaluation of orthodontic treatment by means of four different cephalometric superimposition methods. *Dental Press J Orthod.* 2015;20(3):29-36.
- Abraham RA, Sundareswaran S. Comparison of Ricketts, Pancherz and Centographic Superimposition Methods in Post-Treatment Assessment of the Effects of Twin Block-Appliance Therapy. *Iran J Ortho.* 2018;13(2):e12512. doi:10.5812/ijo.12512.

Author biography

Nidhi Agrawal, Lecturer  <https://orcid.org/0000-0001-9498-6226>

Surbhi Gupta, Consultant

Soumya Gupta, Reader

Shabana Nazmeen, Consultant Orthodontist

Deepkesh Bhuyan, Lecturer

Gangesh B Singh, Lecturer

Cite this article: Agrawal N, Gupta S, Gupta S, Nazmeen S, Bhuyan D, Singh GB. Cephalometric superimposition in orthodontics-A review. *IP Indian J Orthod Dentofacial Res* 2022;8(1):1-6.