



Case Report

Single phase correction of tongue thrust habit alongside fixed orthodontic treatment for closure of spaced dentition and midline diastema in a male patient with class I malocclusion without need for a two phase appliance therapy - A case report

Lishoy Rodrigues^{1,*}, Bhushan Jawale¹, Aljeeta Kadam², Priyaa Rajani¹

¹Dept. of Orthodontics and Dentofacial Orthopedics, Sinhgad Dental College and Hospital, Pune, Maharashtra, India

²Huntly Dental Practice, Scotland, United Kingdom



ARTICLE INFO

Article history:

Received 23-06-2020

Accepted 08-07-2020

Available online 04-09-2020

Keywords:

Tongue thrust correction
Midline Diastema
Fixed Appliance Therapy
Class I malocclusion
Spaced dentition
Aesthetic Improvement
Habit breaking

ABSTRACT

Maxillary midline diastema is one of the most frequently encountered esthetic problems in mixed and permanent dentition. Several causes have been attributed to the midline diastema, including developmental, pathologic or iatrogenic. It can also be seen as a transient malocclusion in which case any intervention is contraindicated. A wide range of possible treatments like restorative procedures, composite build up, surgeries (frenectomies) can be done, based on etiology. Thus, correct diagnosis of etiology and specific early intervention plays a major role in deciding the treatment plan. Class I malocclusion is one of the most common problems around the globe affecting around one-third of the patients who come for orthodontic treatment. This case report evaluates the management of Class I malocclusion with spaced dentition and a tongue thrusting habit in a male patient with the help of a single phase appliance therapy without the need for 2 phase correction, i.e. 1st the correction of tongue thrusting with the help of a habit breaking appliance followed by Fixed appliance therapy with braces. This modality not only saves time, but also promotes faster habit breaking as intervention is done in the earlier stages of life when the patient is still growing. Severe maxillary incisor proclination with a convex Orthognthic facial profile, increased mandibular plane angle, incompetent lips and increased overjet was observed on clinical and cephalometric analysis. Orthodontic treatment resulted in a marked improvement of the patient's smile and a remarkable increase in self-confidence and quality of life. The profile changes and treatment results were demonstrated with proper case selection and good patient cooperation with fixed appliance therapy.

© 2020 Published by Innovative Publication. This is an open access article under the CC BY-NC license (<https://creativecommons.org/licenses/by-nc/4.0/>)

1. Introduction

A space between adjacent teeth is called a “diastema”. Midline diastema (or diastemas) occur in approximately 98% of 6 year olds, 49% of 11 year olds and 7% of 12–18 year olds.¹ The midline is very often seen to be a routine part of the developing occlusion, due to the natural position of teeth in their bony crypts, the eruption path of the cuspids, and increase in the size of premaxilla at the time of eruption of the maxillary permanent central incisors. In Today's times, Fixed Appliance treatment can

significantly alter and improve facial appearance in addition to correcting irregularity of the teeth. Class I malocclusion is the second most prevalent occlusion after Class II malocclusion.^{1,2} Over the last few decades, there has been an increase in the awareness about orthodontic treatment which has led to more and more adults demanding high quality treatment in the shortest possible time with increased efficiency and reduced costs.³ There are many ways to treat Class I malocclusions, according to the characteristics associated with the problem, such as anteroposterior discrepancy, age, and patient compliance.^{4,5} The indications for extractions in orthodontic practice have historically been

* Corresponding author.

E-mail address: lishoy95@gmail.com (L. Rodrigues).

controversial.⁶⁻⁸. On the other hand, correction of Class I malocclusions in growing patients, with subsequent dental camouflage to mask the skeletal discrepancy, can involve either retraction by non extraction means simply by utilizing the available spaces or by extractions of premolars.^{9,10} Lack of crowding or cephalometric discrepancy in the mandibular arch is an indication of 2 premolar extraction.^{11,12} Fortunately, in some instances satisfactory results with an exceptional degree of correction can be achieved without extraction of permanent premolars. This case presents the correction of a Class I Spaced malocclusion in a male patient with a midline diastema, a tongue thrusting habit, increased overjet and a bimaxillary protrusion simply by executing a non extraction protocol by breaking the tongue thrusting habit alongside the progress of Fixed appliance therapy for retraction and closure of existing spaces. The Non Extraction protocol shown in this case is indicative of how a borderline extraction case can be converted into a non extraction case by routine Fixed Orthodontic treatment

2. Case Report

2.1. Extra-oral examination

A 19 year old male patient presented with the chief complaint of forwardly placed, spaced upper front teeth and excessive show of upper front teeth. On Extraoral examination, the patient had a convex profile, grossly symmetrical face on both sides, incompetent lips, moderately deep mentolabial sulcus and an average Nasolabial Angle, a Leptoprosopic facial form, Dolicocephalic head form, Average width of nose and mouth, minimal buccal corridor space, a consonant smile arc and slightly posterior divergence of face. The patient had no relevant prenatal, natal, postnatal history or a family history. However the patient had a tongue thrusting habit, which was diagnosed when the patient was asked to swallow on occlusion. The tongue protruded against the spaced dentition. On Smiling, there was a complete show of maxillary anterior teeth. However, mandibular teeth were not visible on smiling. The patient had a toothy smile. The patient had an unaesthetic flat smile arc and was very dissatisfied with his smile.

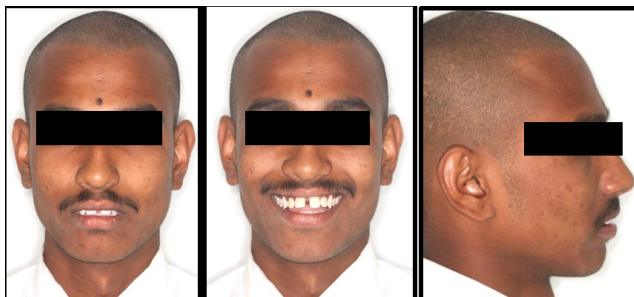

Fig. 1: Pre treatment extraoral photographs

2.2. Intra-oral examination

Intraoral examination on frontal view shows presence of a large midline diastema of 3mm. On lateral view the patient shows the presence of Class II div 1 incisor relationship, a Class I Canine relationship on both sides and a Class I molar relationship Bilaterally. Patient has an overjet of 6 mm and an overbite of 2 mm. There is spacing in upper anterior region with flared out anterior teeth, however the lower arch is moderately well aligned. The upper and lower arch shows the presence of a U shaped arch form and both upper and lower anterior region show flared out anterior teeth indicative of a bimaxillary dentoalveolar protrusion. OPG of the patient shows presence of 3rd molars in a developing stage and a spaced anterior dentition with a midline diastema.

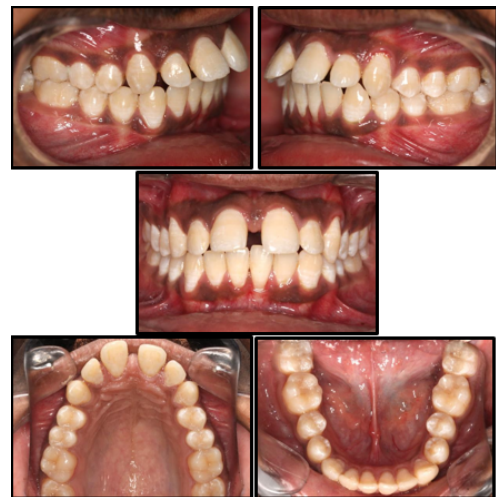

Fig. 2: Pre treatment intraoral photographs

Photographic Analysis

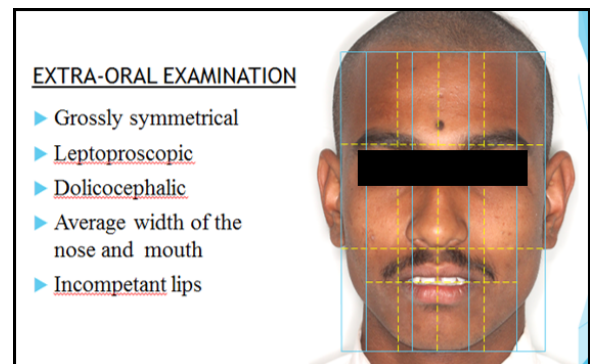
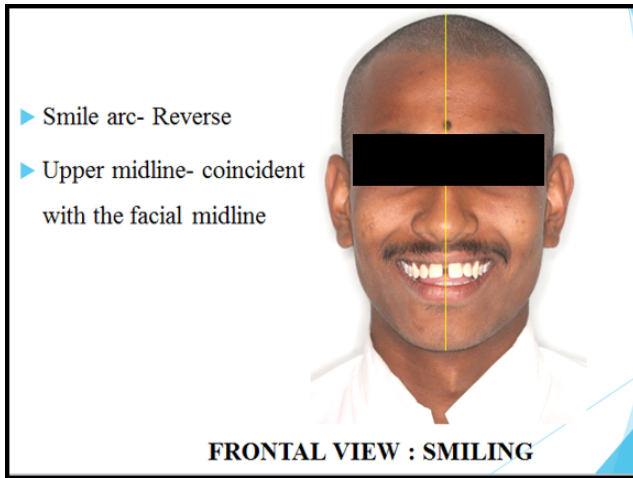
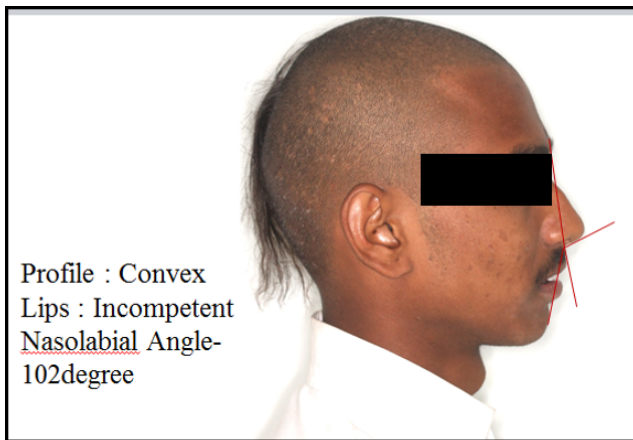


Fig. 3: Photographic Analysis



STEINER'S ANALYSIS			
Measurement	Mean	Pre Rx	Inference
SNA	82°	84°	Average
SNB	80°	82°	Average
ANB	2°	2°	Average
Go-Gn to Sn	32°	30°	Average growth pattern
U1 to NA angle	22°	38°	Proclined maxillary incisors
U1 to NA mm	4mm	11mm	Forwardly placed maxillary incisors
L1 to NB angle	25°	32°	Proclined man incisors
L1 to NB mm	4mm	7mm	Forwardly placed maxillary incisors
Interincisal angle	130°	106°	Proclined upper and lower anteriors
Occlusal plane - SN	14°	14°	Average
'S' Line			
U Lip	0mm	1mm	Protrusive upper and lower lips
L Lip	0mm	3mm	

Fig. 5: Pre treatment cephalometric readings



TWEEDS ANALYSIS			
Measurement	Mean	Pre Rx	Inference
FMA	25°	32°	Vertical growth pattern
FMA	65°	50°	
IMPA	90°	98°	Proclined lower incisors

Wits appraisal:-
BO ahead ofAO by 1 mm indicating mild anteroposterior skeletal dysplasia

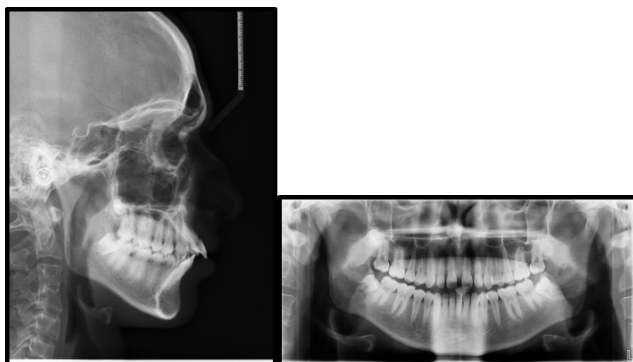


Fig. 4: Pre Treatment X-Rays

RICKETTS ANALYSIS			
Measurement	Mean (for 9 yrs)	Pre Rx	Inference
Facial axis(Ba-Na to Pt-Gn)	90± 3.5°	93°	Average
Facial angle(N-pg to FH)	87± 3°	84°	Average
Mandibular plane angle	26± 4.5°	28°	Average growth pattern
Convexity at Pt. A	2± 2mm	2 mm	Average maxilla
L1 to A - Pg	1± 2 mm	4 mm	Average
U6 to Ptv	Age + 3 yrs	16 mm	
L1 inclination(1 to A-Pog)	22± 4°	26°	Average
Lower lip to E plane(Pog-Pn)	-2 ±2 mm	0 mm	Average

MC NAMARA ANALYSIS			
Measurement	Mean	Pre Rx	Inference
N perp - A	0 -1mm	1 mm	Average
N perp to Pog	0-4 mm	4mm	Average
Facial axis angle(Ptm-Gn)-(Ba-Na)	0± 3.5°	3°	Average
Mand. Plane angle(FH-GoMe)	22 ± 4°	28°	Vertical growth pattern
Eff. Maxillary Length(Co- A)		104 mm	Average
Eff. Mandibular Length(Co-Gn)		140mm	Average
Maxillomandibular differential		36mm	Average
Lower ant. Facial ht(ANS-Me)		83mm	Average
U1 to Pt. A	4-6 mm	12 mm	Proclined max incisors
L1 to A-Pog	1-3mm	5mm	Proclined man incisors
Nasolabial angle	102 ± 8°	102°	Average nasolabial angle
Pharyngeal analysis	U	15-20	Adequate upper and lower airway passage
	L	11-14	

DOWNS ANALYSIS			
Measurement	Mean	Pre Rx	Inference
Facial angle	87.8° (82°-95°)	84°	Average
Angle of convexity	0° (-8.5°-10°)	10°	Average maxilla
Mandibular plane angle	21.9° (17°-28°)	28°	Average growth pattern
Y-axis	59° (53°-66°)	62°	Average
A-B plane angle	-4.6° (-9°-0°)	-4°	Average
Cant of occlusal plane	9.3° (1.5°-14°)	13°	Average
Interincisal angle	135.4 +/- 5.8	106°	Proclined upper and lower anteriors
Incisor mandibular plane angle	1.4° (-8.2°-7°)	-10°	Increased
Incisor occlusal plane angle	14.5° (3.5°-20°)	27°	Increased
U1 - A-Pog	2.7mm(-1-5mm)	12 mm	Average

Fig. 6:

RAKOSIJARABAK ANALYSIS			
Measurement	Mean	Pre Rx	Inference
Saddle angle	123± 5°	118°	Average
Articular angle	143± 6°	148°	Average
Gonial angle	128± 7°	126°	Average
Upper gonial angle	52-55°	53°	Average
Lower gonial angle	70-75°	74°	Average
Sum of posterior angles	396± 6°	392°	Average
Mandibular plane angle	32°	28°	Average growth pattern
Angle of inclination	85°	85°	Average
Basal plane angle	25°	24°	Average
Palatal plane to occlusal plane	11°	12°	Average
Occlusal plane to MP	14°	12°	Average
Post to Ant. Face ht. ratio	62-65%	63.5 %	Average growth pattern
Y - axis(FH-SeGn)	66°	62°	Average
U1 - SN	102± 2°	123°	Increased
U1-Palatal plane	70±5	53°	Proclined max incisors
L1 - MP	90± 3°	98°	Proclined man incisors

Table 1: Pre treatment cephalometric summary

Parameters	Pre- treatment
SNA	84°
SNB	82°
ANB	2°
WITS	1mm(BO ahead of AO)
MAX. LENGTH	104mm
MAN. LENGTH	140mm
IMPA	98°
NASOLABIAL ANGLE	102°
U1 TO NA DEGREES	38°
U1 TO NA mm	11mm
L1 TO NB DEGREES	32°
L1 TO NB mm	7mm
U1/L1 ANGLE	106°
SADDLE ANGLE	118°
ARTICULAR ANGLE	148°
GONIAL ANGLE	126°
FMA	32°
Y AXIS	62°

HOLDAYSAYS SOFT TISSUE ANALYSIS			
Measurement	Mean	Pre Rx	Inference
Facial angle	90± 3°	84°	Average
Upper lip curvature	2-5 mm	3mm	Average
Skeletal convexity at Pt. A	2 ± 2 mm	4 mm	Average
H line angle	7 - 15°	15°	Average
Nose tip to H line	12 mm	6 mm	Average
Upper sulcus depth	5 mm	5 mm	Average
Upper lip thickness	15 mm	14 mm	Average
Upper lip strain	2 mm	2mm	Average
Lower lip to H line	-1 to +2mm	1 mm	Average
Lower sulcus depth	5 mm	5 mm	Average
Soft tissue chin thickness	10-12 mm	10 mm	Average

3. Diagnosis

This 19 years old male patient is diagnosed with Angle’s Class I malocclusion with an average to vertical growth pattern, proclined upper and lower incisors, spacing in the upper and mild crowding in the lower anterior region, protrusive upper and lower lips, incompetent lips, an unaesthetic flat smile arc, an increased overjet and decreased overbite, tongue thrusting habit and presence of a midline diastema.

PROBLEM LIST			
	Anteroposterior	Vertical	Transverse
Dental	<ul style="list-style-type: none"> > Rotated 14,24,31,33,34,41,44 > Spacing in upper anterior teeth > Crowding in the lower anterior teeth > Proclined maxillary and mandibular incisors > Increased overjet 	Decreased overbite	NIL
Skeletal	NIL	NIL	NIL
Soft tissue	<ul style="list-style-type: none"> > Protrusive upper and lower lips > Tongue thrusting habit 	High frenal attachment	NIL

TREATMENT OBJECTIVES

- ▶ To correct spacing in the maxillary and crowding in mandibular anterior teeth
- ▶ To correct proclined maxillary and mandibular anterior teeth
- ▶ To correct rotated teeth
- ▶ To correct tongue thrusting habit
- ▶ To correct the high frenal attachment
- ▶ To maintain Angle's Class I molar relation on both sides
- ▶ To maintain Canine Class I relation on both sides
- ▶ To maintain congruent midlines
- ▶ To achieve a pleasing smile and a pleasing profile

TREATMENT PLAN

Fixed Mechanotherapy (MBT 0.022 slot)

- ▶ Banding of 16,26,36,46
- ▶ Bonding with MBT brackets
- ▶ Removable palatal crib engaged in the lingual sheath attached to the molar tubes
- ▶ Initial leveling and alignment with 0.016" NiTi wires, following sequence A of MBT
- ▶ Extraction of 14,24,34,44(Group B anchorage)
- ▶ Use of 0.019/0.025" rectangular NiTi followed by 0.019/0.025" rectangular stainless steel wires for retraction and closure of spaces.
- ▶ Refer for frenectomy before closure of midline diastema
- ▶ Final finishing and detailing with 0.014 round stainless steel wires
- ▶ Retention by means of lingual bonded retainers in the upper and lower arch

Nance Palatal Button Appliance was given for correction of tongue thrusting habit alongside fixed orthodontic braces treatment. Retraction and closure of spaces was then started by use of 0.019" x 0.025" rectangular NiTi with accentuated Anchor sweeps in the upper and lower stiff archwires for opening of bite to prevent the bite deepening during retraction followed by 0.019" x 0.025" rectangular stainless steel wires. Anchorage was conserved by light retraction forces constantly monitoring the already well settled molar relation. This is the most important step in a borderline extraction case wherein anchorage conservation is of utmost importance. Finally light settling elastics were given with rectangular steel wires in lower arch and 0.012" light NiTi wire in upper arch for settling, finishing, detailing and proper intercuspation. Midline Diastema closure was achieved. The smile of the patient changed from being flat and unaesthetic to a more pleasing and consonant.

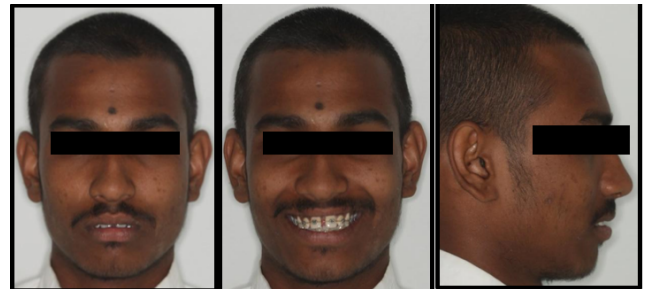

Fig. 8: Treatment extraoral photographs

Bolton ratio:-

Maxillary anterior excess:- 4.77 mm

Maxillary overall excess:- 0.94 mm

Ashley Howe's index:-

Need for extraction

Pont's Index :

Expansion needed

Arch Perimeter Analysis :

need to extract 1st premolars

Careys Analysis :

need to extract 1st premolars

Chadda's Index :

Expansion needed

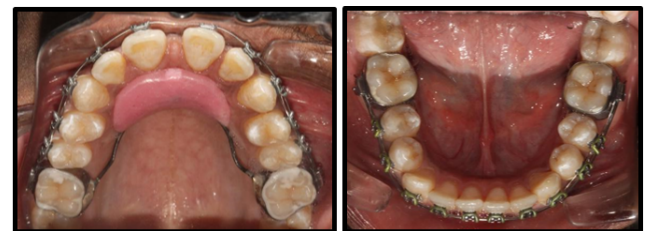

Fig. 9: Treatment intraoral photographs with nance palatal arch for habit breaking

Fig. 7: Model Analysis

3.1. Treatment Progress

Complete bonding & banding in both maxillary and mandibular arch done, using MBT-0.022X0.028"slot. Initially a 0.012" NiTi wire was used which was followed by 0.014, 0.016", 0.018", 0.020" NiTi archwires following sequence A of MBT. After 6 months of alignment and leveling NiTi round wires were discontinued. A Fixed

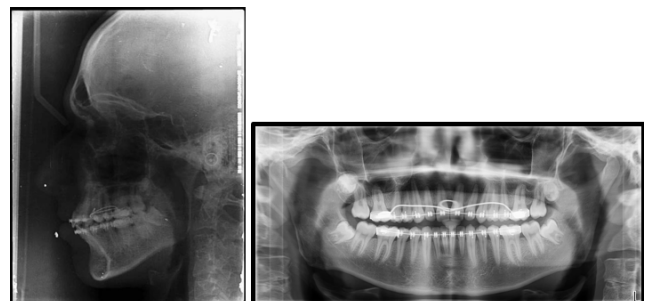
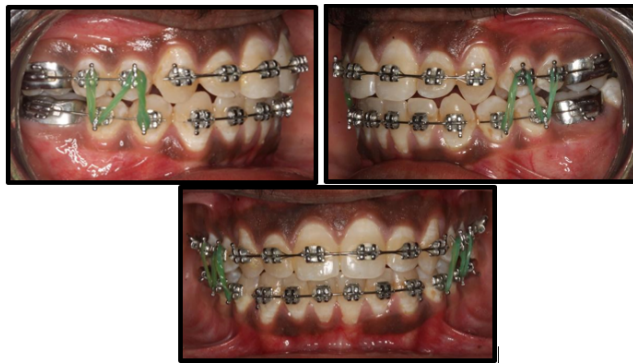

Fig. 10: PRE debonding x-rays

Table 2: Pre Debonding Cephalometric Readings

Parameters	Post-treatment
SNA	82°
SNB	80°
ANB	2°
WITS	1mm
MAX. LENGTH	99mm
MAN. LENGTH	138mm
IMPA	92°
NASOLABIAL ANGLE	106°
U1 TO NA DEGREES	30°
U1 TO NA mm	3mm
L1 TO NB DEGREES	27°
L1 TO NB mm	2mm
U1/L1 ANGLE	130°
SADDLE ANGLE	119°
ARTICULAR ANGLE	144°
GONIAL ANGLE	125°
FMA	28°
Y AXIS	64°

**Fig. 11:** Pre debonding extraoral photographs

4. Discussion

It is important for an Orthodontist to consider contributing factors before determining an optimal treatment plan. These include normal growth and development, tooth size discrepancies, excessive incisor vertical overlap of different causes, mesiodistal and labiolingual incisor angulation, generalized spacing and pathological conditions. A carefully developed differential diagnosis enables the practitioner to choose the most effective orthodontic and/or restorative treatment. Restorative and prosthetic treatment is usually employed to treat Diastemas based on tooth-size discrepancies. The most appropriate treatment often requires orthodontically closing the midline diastema. It is challenging to treat Class I malocclusion and bimaxillary protrusion without extraction of premolars. A well chosen individualized treatment plan, undertaken with sound biomechanical principles and appropriate control of orthodontic mechanics to execute the plan is the surest way to achieve predictable results with minimal side

effects. Class I malocclusion with spacing might have any number of a combination of the skeletal and dental component. Hence, identifying and understanding the etiology and expression of Class I spaced malocclusion and identifying differential diagnosis is helpful for its correction. The patient's chief complaint was forwardly placed, spaced and excessive show of upper front teeth. The selection of orthodontic fixed appliances is dependent upon several factors which can be categorized into patient factors, such as age and compliance, and clinical factors, such as preference/familiarity and laboratory facilities. The execution of only Fixed appliance therapy appropriately resulted in an improvement in the patient's profile in this case. Alongside fixed orthodontic treatment, a habit breaking Fixed Nance Palatal Button appliance was given to the patient for correction of his severe tongue thrusting habit. The SNA value showed a significant decrease from 84 to 82 degrees, the SNB value changed from 82 to 80 degrees thus addressing the major problem of maxillary and mandibular bidental protrusion. The mandibular incisor proclination reduced from 98 to 92 degrees, the nasolabial angle changed from 102degrees to 106degrees thus moderately improving the patient's profile and the Frankfurts mandibular plane angle showed changes from being vertical to more towards average growth pattern of patient due to the counterclockwise rotation of the mandibular plane. Successful results were obtained after the fixed MBT appliance therapy within a stipulated period of time. The overall treatment time was 12 months. After this active treatment phase, the profile of this 19 year old male patient improved significantly as seen in the post treatment Extra oral photographs. Removable Vacuum formed clear retainers were then delivered to the patient. Midline Diastema was corrected, spacing was corrected and the smile arc of the patient improved drastically to being consonant and pleasant. The patient was very happy and satisfied with the results at the end of the treatment.

5. Conclusion

This case report shows how a Tongue thrusting habit in a patient whose growth has nearly completed can be managed alongside fixed orthodontic treatment, thus saving time that is spend during a 2 phase appliance therapy with 1st correcting the inborn habit and then proceeding towards fixed braces treatment. The planned goals set in the pretreatment plan were successfully attained. Good intercuspation of the teeth was maintained with class I molar relationship by carefully conserving anchorage. Treatment of bimaxillary protrusion and localized spacing with midline diastema included the retraction and retroclination of maxillary and mandibular incisors with a resultant decrease in soft tissue procumbency and convexity. The maxillary and mandibular teeth were found to be esthetically satisfactory in the line of occlusion with a pleasing

Table 3: Comparison of pre treatment and pre debonding cephalometric readings

Parameters	Pre- treatment	Post-treatment
SNA	84°	82°
SNB	82°	80°
ANB	2°	2°
WITS	1mm(BO ahead of AO)	1mm
MAX. LENGTH	104mm	99mm
MAN. LENGTH	140mm	138mm
IMPA	98°	92°
NASOLABIAL ANGLE	102°	106°
U1 TO NA DEGREES	38°	30°
U1 TO NA mm	11mm	3mm
L1 TO NB DEGREES	32°	27°
L1 TO NB mm	7mm	2mm
U1/L1 ANGLE	106°	130°
SADDLE ANGLE	118°	119°
ARTICULAR ANGLE	148°	144°
GONIAL ANGLE	126°	125°
FMA	32°	28°
Y AXIS	62°	64°

consonant smile arc. The overjet become near ideal and normal overbite was found. The correction of the malocclusion was achieved, with a significant improvement in the patient aesthetics and self-esteem. The patient was very satisfied with the result of the treatment.

6. Source of Funding

None.

7. Conflict of Interest

None.

References

- Hossain MZ. Prevalence of malocclusion and treatment facilities at Dhaka Dental College and Hospital. *J Oral Health*. 1994;1(1).
- Ahmed N. Prevalence of malocclusion and its aetiological factors. *J Oral Health*. 1996;2(2).
- Khan RS, Horrocks EN. A Study of Adult Orthodontic Patients and their Treatment. *Br J Orthod*. 1991;18(3):183–94.
- Salzmann JA. Practice of orthodontics. Philadelphia: J. B. Lippincott Company; 1966. p. 701–725.
- Mcnamara JA. Components of Class II malocclusion in children 8 to 10 years of age. *Angle Orthod*. 1981;51:177–202.
- Case C. The question of extraction in orthodontia. *Am J Orthod*. 1964;50:660–91.
- Case CS, Dewey C. Discussion of Case: the question of extraction in orthodontia. *Am J Orthod*. 1964;50:900–12.
- Tweed CH. Indications for the extraction of teeth in orthodontic procedure. *Am J Orthod Oral Surg*. 1944;30(8):405–28.
- Cleall JF, Begole EA. Diagnosis and treatment of Class II Division 2 malocclusion. *Angle Orthod*. 1982;52:38–60.
- Strang RHW. Tratado de ortodoncia. In: Editorial Bibliográfica Argentina. Buenos Aires; 1957. p. 657–71.
- Bishara SE, Cummins DM, Jakobsen JR, Zaher AR. Dentofacial and soft tissue changes in Class II, Division 1 cases treated with and without extractions. *Am J Orthod Dentofacial Orthop*. 1995;107(1):28–37.
- Rock WP. Treatment of Class II malocclusions with removable appliances. Part 4. Class II Division 2 treatment. *Br Dent J*. 1990;168:298–302.

Author biography

Lishoy Rodrigues Post Graduate Student

Bhushan Jawale Professor

Aljeeta Kadam General Practitioner

Priyal Rajani Intern

Cite this article: Rodrigues L, Jawale B, Kadam A, Rajani P. Single phase correction of tongue thrust habit alongside fixed orthodontic treatment for closure of spaced dentition and midline diastema in a male patient with class I malocclusion without need for a two phase appliance therapy - A case report. *IP Indian J Orthod Dentofacial Res* 2020;6(3):163-169.