



Review Article

Infective endocarditis: An Orthodontist's perspective

Sumit Kumar Yadav^{1,*}, Neal Bharat Kedia², Gunjan Kedia², Kunal Kumar³¹Dept. of Orthodontics & Dentofacial Orthopedics, DJ College Of Dental Sciences & Research, Niwari Dehat, Uttar Pradesh, India²Dept. of Orthodontics & Dentofacial Orthopedics, Buddha Institute of Dental Sciences and Hospital, Patna, Bihar, India³Dept. of Dentistry, Patna Medical College and Hospital, Patna, Bihar, India

ARTICLE INFO

Article history:

Received 31-03-2020

Accepted 22-04-2020

Available online 27-05-2020

Keywords:

Infective endocarditis

Orthodontist

Treatment.

ABSTRACT

Infective endocarditis associated with orthodontic treatment is a rare occurrence. Unfortunately, many orthodontic practitioners do not treat patients potentially at risk of developing endocarditis due to the lack of practical guidelines and fear of precipitating the infection. Additionally, many patients that undergo orthodontic treatment are inappropriately prescribed antibiotic cover for procedures that have a minimal bacteraemia risk. In this paper the literature linking orthodontic treatment and infective endocarditis was examined. The appropriate management were recommended for patients with risk of infective endocarditis during orthodontic procedures.

© 2020 Published by Innovative Publication. This is an open access article under the CC BY-NC license (<https://creativecommons.org/licenses/by-nc/4.0/>)

1. Introduction

Infective endocarditis is a serious infection occurring on the endothelial surfaces of the heart, especially at the valves. Oral commensal bacteria are the important etiologic agents in this disease. Common dental procedures, even non-surgical dental procedures, can often cause bacteraemia of oral commensals. Infective endocarditis is a rare, but has very serious complication during dental treatment. One necessary prerequisite for the development of infective endocarditis is a bacteraemia, which can develop as a result of dental treatment. Patients with conditions that predispose to the development of infective endocarditis need to be identified and given prophylactic antibiotics before dental treatment known to generate a bacteraemia. Most types of dental procedures, which are known to cause bacteraemias, have been investigated and guidelines for the prevention of infective endocarditis have been published.^{1,2} However, there is still confusion, about what types of orthodontic procedures generate bacteraemias which could cause endocarditis in a susceptible patient. This has led

some orthodontists to be ultra-cautious and to not carry out orthodontic treatment in susceptible patients. The purpose of this paper was to examine the link between orthodontic procedures and infective endocarditis, and to make practical recommendations for practitioners.

1.1. The link between orthodontic treatment and infective endocarditis

The link between orthodontics and infective endocarditis has not been fully defined.^{3,4} Hobson and Clark, in a survey of 1038 orthodontists, found only eight cases of infective endocarditis diagnosed during or immediately after orthodontic treatment involving both fixed and removable appliances.⁴ The paucity of reported cases could reflect the fact that very limited orthodontic treatment has been done for patients converse is true, orthodontics is widely practiced on patients susceptible to infective endocarditis both in Europe and U.S.A. It would be necessarily follow that, since there is a paucity of cases, the risk between infective endocarditis and orthodontics must be very small. However, it is as yet unclear which clinical procedures in orthodontics could potentially result in the development of

* Corresponding author.

E-mail address: sky20083@gmail.com (S. K. Yadav).

endocarditis.

It has been postulated that placement of orthodontic bands could result in a bacteraemia. McLaughlin et al. were able to detect bacteraemias in 10 per cent of blood samples taken during band placement.⁵ One other study did not detect micro-organisms in the bloodstream during banding.⁶ This apparent contradiction in detection rates may be a result of difficulties in the techniques of bacteraemia detection. It could also (and more likely) be due to the fact that banding does not always produce detectable bacteraemias that could cause infective endocarditis.

Cleaning and polishing of teeth has been associated with bacteraemias and infective endocarditis.^{7,8} Therefore, this procedure could predispose patient at risk of infective endocarditis. Therefore according to literature antibiotic prophylaxis is required in susceptible patients for the placement and removal of bands, and any polishing of the teeth. The adjustment of fixed or removable orthodontic appliances has never been associated with a risk of a significant bacteraemia or a proven case of infective endocarditis. It is for this reason that the American Heart Association, in their recent guidelines did not recommend prophylaxis for adjustment of orthodontic appliances.⁹ Similarly, the taking of impressions for study models is not associated with a significant bacteraemia (that could cause infective endocarditis) and does not require prophylactic antibiotics. The exposure of teeth (particularly palatal canines) is a surgical procedure that would generate a bacteraemia and requires prophylactic antibiotics in patients susceptible to infective endocarditis. Once the tooth is exposed, the operative site may be considered in the same manner as an extraction site or erupting tooth, and does not require any further antibiotics. It has been argued that traction following excisional exposure may result in a reduced risk of bacteraemia compared to traction following replaced flap techniques.⁴ This recommendation may be based on the potential for bacteraemia during the period of traction. In our opinion any tooth movement through a replaced flap is analogous to accelerated tooth eruption and should not require prophylactic antibiotics.

1.2. Principles of prophylaxis

Prophylaxis is sometimes interpreted as only antibiotic cover; however, it should also be concerned with the maintenance of good oral hygiene and prevention of oral disease. Poor oral hygiene results in plaque accumulation and a resultant quantitative increase in plaque bacteria. The subsequent gingival inflammation and spontaneous bleeding caused by broken capillaries will lead to transitory bacteraemias. Hence, placement of orthodontic appliances and gingival inflammation in such a situation will result in an increase in bacteraemic episodes.

Transitory bacteraemias have been induced in patients with clinically healthy gingivae.¹⁰ Bacteraemias have also

been demonstrated with tooth brushing in the presence of inflammation and plaque, but the significant factor is that the bacteraemic load is reduced when oral hygiene is good.¹¹ Silver et al also showed that the percentage of positive cultures (a measure of the number of micro-organisms isolated) increased with increasing severity of inflammation.¹⁰ There are no reports of infective endocarditis being precipitated by oral hygiene procedures in patients with mouths that have a good gingival condition. The number of micro-organisms in a bacteraemia is also influenced by the degree of trauma after a particular manipulative procedure.¹² Therefore, antibiotic cover is recommended for some procedures and not others.¹

An effective method for reducing the level of bacteraemia is to use an oral rinse of 0.2 per cent (w/v) chlorhexidine solution.^{13,14} Repeated applications of chlorhexidine have not been found to result in changes in sensitivity to this disinfectant.^{15,16} This is distinct from patients who have received long term antibiotics where resistant strains of oral Streptococci, the most common bacteria identified in bacterial endocarditis, tend to be present in the mouth.¹⁷

1.3. Patients at risk from infective endocarditis

The most important factor in the assessment of patient's at risk from infective endocarditis is the patient's medical history. Patients can be divided into three types: high, moderate or negligible risk. The medical conditions that are in each of the three categories are shown in Table 1. Patients at high risk can potentially undergo orthodontic treatment, but the patient's cardiologist should be consulted to assess risk before treatment. If, after consultation with the patient's physician, the risk of infective endocarditis is considered to be high then treatment should not be undertaken. Patients at moderate risk of endocarditis can receive orthodontic treatment and they will need antibiotic cover for procedures that cause bacteraemia. Patients at negligible risk can be treated without antibiotic prophylaxis, but again, the precise nature of the patient's condition should be confirmed with the physician prior to the start of treatment. Many potential orthodontic patients give a history of a heart murmur. This requires investigation and clarification of whether the murmur is innocent, prior to undertaking any orthodontic treatment.

Antibiotic prophylaxis is recommended for the 'high' and 'moderate' risk categories, but not for the 'negligible' risk category. This latter category lists cardiac conditions in which the development of endocarditis is not higher than in the general population.

1.4. Special Risk Patients

The British Society of Antimicrobial Chemotherapy have recognized a group of patients, with endocardial disease, who they consider as 'special risk'; these are considered to

Table 1: Cardiac conditions associated with endocarditis (Dajani et al., 1997)⁹**High Risk**

1. Prosthetic cardiac valves, including bioprosthetic and homograft valves.
2. Previous bacterial endocarditis.
3. Complex cyanotic congenital heart disease (e.g. single ventricle states, of the transposition of the great arteries, tetralogy of Fallot)
4. Surgically-constructed systematic pulmonary shunts or conduits. Individuals with any of the above conditions are at a much higher risk for developing severe endocardial infection that is often associated with high morbidity and mortality.

Moderate Risk

1. Most other congenital cardiac malformations (other than those above or below).
2. Acquired valvular dysfunction (e.g. rheumatic heart disease).
3. Hypertrophic cardiomyopathy.
4. Mitral valve prolapse with valvular regurgitation and/or thickened leaflets.

Negligible Risk

1. Isolated secundum atrial septal defect.
2. Surgical repair of atrial septal defect, ventricular septal defect or patent ductus arteriosus.
3. Previous coronary artery bypass graft surgery.
4. Mitral valve prolapse without valvular regurgitation.
5. Physiological functional or innocent heart murmurs.
6. Previous Kawasaki disease without valvular dysfunction.
7. Previous rheumatic fever without valvular dysfunction.
8. Cardiac pacemakers and implanted defibrillators.

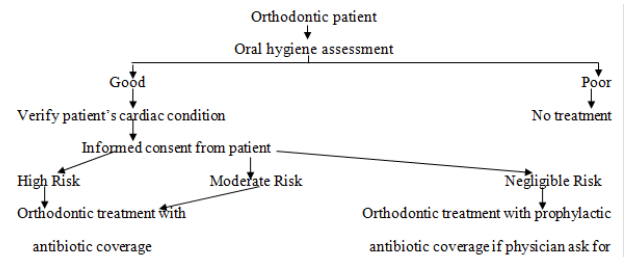
be particularly susceptible to infective endocarditis. Special risk patients are classified as those patients with endocardial disease who have had infective endocarditis or require a general anesthetic and

1. They have a prosthetic
2. Month.

1.5. The practicalities of orthodontic treatment in patients at risk from infective endocarditis and management recommendations

The patient's condition should be accurately understood before any treatment is stated and this may involve further confirmatory tests by the cardiologist (e.g. echocardiography). When the orthodontist is in possession of all this information then informed consent should be obtained from the patient and/or guardian as appropriate. Figure 1 shows a practical scheme for treating orthodontic patients at risk from endocarditis. In the opinion of the authors, the treatment formulated in patients at high risk of endocarditis should be practical, achievable, and not over ambitious. As with all orthodontic patients, oral hygiene should be impeccable before any treatment is started. Oral hygiene of a high standard is especially important in patients at risk from infective endocarditis since the accumulation of plaque increases the risk of significant bacteraemias during treatment. If the patient's oral hygiene lapses during treatment then consideration must be given to the abandoning of the appliance treatment if the hygiene does not rapidly improve. Patients at 'high' or 'moderate' risk should receive prophylactic antibiotics for procedures known to be associated with a bacteraemia.

Table 2 Lists orthodontic procedures and the need for antibiotic prophylaxis in the 'high' and 'moderate' risk

**Fig. 1:** Chematic representation of management of orthodontic patient at risk for infective endocarditis

categories.

etails the currently recommended regimen for the prophylaxis of infective endocarditis. Any orthodontic procedure in patients under any of the three risk categories should be done following a preliminaryrinse with 0.2 per cent chlorhexidine mouthwash. Daily chlorhexidine rinsing should also be advised if mucosal irritation occurs which results in bleeding from the appliance. For effective prophylaxis, antibiotic therapy ideally should be administered within 2 hours of the procedure. In order to reduce the number of prophylaxis courses, fixed appliance placement should be completed in one visit. This is possible with banding and bonding without separation or preferably, the bonding of brackets on all teeth.

In all of the 'risk' categories, the patient must be instructed to report back any unexplained illness after the orthodontic procedure has been conducted.¹⁸ There is still a possibility that infective endocarditis may occur despite appropriate antibiotic prophylaxis.^{19,20} This is said to be most likely within the first 30 days of the procedure, but due to the protracted nature of orthodontic treatment, the

Table 2: Requirement for prophylactic antibiotics for orthodontic procedures in patients at high or moderate risk of infective endocarditis

Procedure	Need for antibiotic prophylaxis
• Taking of impressions	No
• Taking of radiographs	No
• Separation	Yes
• Cleaning and polishing prior to banding	Yes
• Placement and adjustment of removable appliances	No
• Placement of bands	Yes
• Bonding of brackets	No
• Placement of archwires with elastics or ligatures	No
• Exposure of teeth	Yes
• Application of traction to exposed teeth either with replaced or excised flaps	No
• Mucosal trauma during archwire placement	Yes

Table 3: Antibiotic regimens recommended for the prophylaxis of dentally-induced infective endocarditis (adapted from the Endocarditis Working Party of the British Society for Antimicrobial Chemotherapy, 1992, 1998).^{1,2}

No penicillin allergy	Allergic to penicillin
Local or no anaesthetic Amoxycillin 3 g orally 1 hour pre-operatively General anaesthetic Amoxycillin (3 g) and probenidol (1 g) or Amoxycillin (3 g) orally 4 hours pre-operatively and amoxycillin (3 g) post-operatively or Amoxycillin (1 g) IV at induction and 500 mg orally 6 hours later Special risk patients* Amoxycillin (1 g) IV and gentamycin (120 mg) IV, pre-operatively or at induction and amoxycillin (500 mg) orally 6 hours later	Clindamycin 600 mg orally 1 hour pre-operatively These patients are classified as 'Special risk' Teicoplanin (400 mg) IV and gentamycin (120 mg) IV pre-operatively or at induction or Clindamycin (300 mg) IV given over 10 min in 50 ml of diluent pre-operatively or at induction and 150 mg (oral or IV) 6 hours later or Vancomycin (1 g) slow IV infusion (over not less than 100 min) followed by gentamycin (120 mg) IV pre-operatively or at induction

* Or patients who have been prescribed penicillin more than once in the previous month.

clinician should remain vigilant.²¹

1.6. Antibiotic management (points to remember)

1. Clindamycin tablets should be swallowed with a glass of water to prevent oesophageal irritation.
2. Children under 10 years of age half the adult dose of amoxycillin or clindamycin is recommended and children under 5 years a quarter of the adult dose. For children under 10 years of age, 20 mg of vancomycin should be used and 2 mg of gentamycin. Children under 14 years of age should be given 6 mg/kg of teicoplanin plus 2mg/kg of gentamycin.
3. For those patients not at special risk amoxycillin maybe given twice in 1 month as it is unlikely that proliferation of clinically significant amoxycillin resistant strains will occur after one 3-g dose of amoxycillin. A third dose of amoxycillin, however, should not be given until after an interval of 1 month. A time interval of at least 2 weeks is required before clindamycin can be again used for prophylaxis.

2. Conclusion

The lack of reported cases in the literature, suggests that infective endocarditis associated with orthodontic treatment is extremely rare. Nevertheless, guidelines are necessarily based on the available scientific evidence, but unfortunately such evidence is scarce.

1. Patients can be divided into high, moderate, and negligible risk of infective endocarditis based on their medical condition.
2. Patients with a 'high' predisposition to infective endocarditis should only be treated after consultation with their supervising physician.
3. Patients at 'medium' risk can be treated but antibiotic prophylaxis should be considered only for procedures causing bacteraemias.
4. In the opinion of the authors, based on the available evidence, patients with a 'low' risk of infective endocarditis can be safely treated, usually without antibiotic prophylaxis. All patients should have a 0.2 per cent w/v chlorhexidine mouthwash prior to each adjustment.

5. Certain procedures are known to be associated with bacteraemias, these include band placement, removal of bands, and surgical exposure of teeth. Such procedures require antibiotic prophylaxis in 'at-risk' patients.

3. Source of Funding

None.

4. Conflict of Interest

None.

References

1. BSAC. Working Party of the British Society for Antimicrobial Chemotherapy (1992) Antibiotic prophylaxis of infective endocarditis. *Lancet*. 1992;1:1292–93.
2. BSAC. Working Party of the British Society for Antimicrobial Chemotherapy (1998) Amoxicillin prophylaxis for endocarditis prevention (letter). *Br Dent J*. 1998;p. 184–208.
3. Gaidry D, Kudlick EM, Hutton JG, Russell DM. A survey to evaluate the management of orthodontic patients with a history of rheumatic fever or congenital heart disease. *Am J Orthod*. 1985;87(4):338–44.
4. Hobson RS, Clark JD. Management of the orthodontic patient 'at risk' from infective endocarditis. *Br Dent J*. 1995;178:289–95.
5. McLaughlin JO, Coulter WA, Coffey A, Burden DJ. The incidence of bacteremia after orthodontic banding. *American Journal of Orthodontics and Dentofacial Orthopedics*. 1996;109(6):639–644. Available from: [https://dx.doi.org/10.1016/s0889-5406\(96\)70076-8](https://dx.doi.org/10.1016/s0889-5406(96)70076-8). doi:10.1016/s0889-5406(96)70076-8.
6. Degling TE. Orthodontics, bacteraemia, and the heart damaged patient. *Angle Orthod*. 1972;42:399–401.
7. Everett ED, Hirschmann JV. Transient bacteremia and endocarditis prophylaxis. A review. *Medicine*. 1977;56:61–7.
8. Martin MV, Butterworth ML, Longman LP. Infective endocarditis and the dental practitioner: a review of 53 cases involving litigation. *Br Dent J*. 1997;182(12):465–468.
9. Dajani AS, Taubert KA, Wilson W, Bolger AF, Bayer A, Ferrieri P, et al. Prevention of bacterial endocarditis, recommendations by the of the American Medical Association. *J Am Heart Assoc*. 1997;277:1974–1801.
10. Silver JG, Martin AW, McBride BC. Experimental transient bacteraemias in human subjects with varying degrees of plaque accumulation and gingival inflammation. *J Clin Periodontol*. 1977;4(2):92–9.
11. Chung A, Kudlick EM, Gregory JE, Royal GC, Reindorf CA. Tooth-brushing and transient bacteremia in patients undergoing orthodontic treatment. *Am J Orthod Dentofac Orthop*. 1986;90(3):181–6.
12. Bender IB, Barkan MJ. Dental bacteremia and its relationship to bacterial endocarditis: preventive measures. *Compendium Continuing Educ Dent*. 1989;10:472–82.
13. Stirrups DR, Laws EA, Honigman JL. The effects of a chlorhexidine mouthrinse on oral health during fixed appliance orthodontic treatment. *Br Dent J*. 1981;151:84–6.
14. MacFarlane TW, Ferguson MM, Mulgrew CJ. Post-extraction bacteraemia: role of antiseptics and antibiotics. *Br Dent J*. 1984;156(5):179–81.
15. Schiott CR. Two years of oral use of chlorhexidine in man. *J Period Res*. 1976;11:153–57.
16. Millns B, Martin MV, Field EA. An investigation of chlorhexidine and cetylpyridium chloride resistant flora of dental students and theatre staff. *J Hospital Inf*. 1994;26:99–104.
17. Longman LP, Pearce PK, McGowan P, Hardy P, Martin MV. Antibiotic-resistant streptococci and infective endocarditis. *J Med Microbiol*. 1992;34:33–7.
18. Samaranyake LP. Orthodontics and infective endocarditis prophylaxis. *Br Dent J*. 1995;179(2):48.
19. Durack DT. Apparent failures of endocarditis prophylaxis. Analysis of 52 cases submitted to a national registry. *JAMA: J Am Med Assoc*. 1983;250(17):2118–22.
20. Bijl PVD, Maresky LS. Failures of endocarditis prophylaxis: selective review of the literature and a case report. *Ann Dent*. 1991;50:5–8.
21. van der Meer JTM, Michel MF, Valkenburg HA, van der Meer JTM, van Wijk W, Thompson J, et al. Efficacy of antibiotic prophylaxis for prevention of native-valve endocarditis. *Lancet*. 1992;339(8786):135–9.

Author biography

Sumit Kumar Yadav Reader

Neal Bharat Kedia Professor

Gunjan Kedia Senior Lecturer

Kunal Kumar Senior Resident

Cite this article: Yadav SK, Kedia NB, Kedia G, Kumar K. **Infective endocarditis: An Orthodontist's perspective.** *IP Indian J Orthod Dentofacial Res* 2020;6(2):39-43.