

Retrospective analysis of size and morphology of sella turcica in different skeletal patterns in Madinah, Saudi Arabia

Mohammed K. Badri^{1*}, Abdulraouf A. Alhojaily², Abdulrahim S. Qutub³, Fatemah K. Alshanqeeti⁴, Rawan A. Jarallah⁵, Saba Kassim⁶

^{1,6}Assistant Professor, ²⁻⁵General Dentist, ¹Dept. of Pedodontics & Orthodontics, ⁶Dept. of Preventive Dental Science, ¹⁻⁶College of Dentistry, Taibah University, Madinah, Saudi Arabia

*Corresponding Author: Mohammed K. Badri
Email: dr_m.badri@hotmail.com

Abstract

Introduction: Local and genetic factors influence size and shape of Sella Turcica (ST) and as such this may impact many parameters including Sella reference point for orthodontic treatment planning. Our aim was set to measure and assess ST morphology and link it with gender and different skeletal patterns.

Methods: This retrospective study conducted on the lateral cephalometric radiographs of 175 patients 15 years and above attending Taibah University Dental College and Hospital between 2011 and 2017. The patients' radiographs meeting inclusion criteria were stratified by gender and divided into three groups (Class I, II, and III) according to the skeletal classification. Length, depth and Anteroposterior (A-P) diameter of ST were measured using a cephalometric software program (Vista Dent) and the shape of ST according to established classifications in the literature. Descriptive statistics and inferential analysis (e.g. one-way analysis of variance (ANOVA) were performed.

Results: The mean/SD age of the patients was 27.43±7.54. The mean/SD length, depth and A-P diameter of ST for male and females were 10.56±1.68, 7.83±1.62, 11.98±1.90, 7.00±2.58, 6.81±1.64, 10.17± 1.86, respectively. There were significant differences ($p < 0.05$) between male and females in all ST size of all skeletal classes apart from the depth in both skeletal class I and II ($p > 0.05$). As for ST morphology 53% of patients had normal Sella shape. While comparing Sella shape with different skeletal classes there were significant differences with circular shape 55% in class I and flat shape 53.3% in class II patients.

Conclusions: Gender differences in ST size has been further confirmed in this study sample with the size significantly larger in males. Also, normal shape of ST is more common than other shape variations. This study can be used as a reference guide for future studies about ST size and morphology.

Keywords: Sella turcica, Sella size, Sella morphology, Lateral cephalometric.

Introduction

S-point, the geometric center of Sella Turcica (ST), is one of the most commonly used landmarks on Lateral Cephalometric Radiographs (LCR). S-point acts as a reference point for evaluating both jaws as they relate to each other and to the cranial base, and any changes in size or morphology of ST would affect that relation and might interpret normal variations or pathological conditions.¹

The shape of ST was investigated by many researches describing it in either healthy or diseased subjects. Previous studies showed that ST shape could have different variations that are shared equally between normal and abnormal patients,²⁻⁴ while some shape variations could be linked to specific medical conditions.⁵⁻⁷ Another important aspect is the size of ST, as it was assessed from radiographs typically ranges from 4 to 12 mm for the vertical and from 5 to 16 mm for the A-P diameters, if any deviation from the normal size and shape of ST detected, it could be considered as a pathologic condition of the gland.⁴ Increased size of pituitary gland maybe a sign of a pituitary tumor which is associated with over producing of some hormones causing a variety of signs and symptoms like Cushing's syndrome, acromegaly, and amenorrhea.⁵ In addition, some patients with enlarged size of ST such as in gigantism and acromegaly show specific skeletal relation (Class III skeletal).

In SA there is a paucity of research of ST morphology and size. A recent study in one of the highly populated city, Riyadh, SA reported size and shape of ST in different skeletal types showed the frequency of normal ST shape was 67 % and shape varies by 33%.⁸ As the ST varies in normal individual and are influenced by genetic and local factors,^{5,9} therefore, studying ST size and morphology for different skeletal type in different context is needed particular in areas with diverse ethnicities such as Madinah SA. Our aim was set to measure ST dimensions and assess its morphology in relation to gender and different skeletal patterns.

Materials and Methods

Study design and study setting

This was a retrospective study that included a convenience sample of LCRs for patients who came for orthodontic treatment over the period between 2011-2017. The LCRs were obtained from R4 Carestream (CS) Clinical and Practice Management Software Database Archives, (CS, Health, Inc. Rochester, NY, USA) at the Department of Pedodontics & Orthodontics, Taibah University Dental College and Hospital, Madinah, Kingdom of Saudi Arabia.

Inclusion and exclusion criteria, sampling and sample

Size calculation

The LCRs for male or female aged >15-years-old and with good quality LCRs i.e. a clear reproduction of ST (e.g. not pale, not dark and no artifacts) were set as inclusion criteria in the study. Patients with chronic diseases, bone tumors, skeletal alterations, without pre-treatment LCR, history of orthodontic treatment or orthognathic surgery, history of facial trauma and skull surgery were excluded from the study.

Of all the records (920) for the aforementioned period 342 did not meet the inclusion criteria and were excluded. The remaining 578 LCRs have undergone a multistage randomization. First, LCRs were stratified according to gender into two main groups (Males & Females) then each group was subdivided into 3 subgroups according to skeletal class (Class I, II, and III), after which samples randomly selected from each stratum using a random number generator website.

The sample size for the study was estimated as 175 LCRs using Open epi version 3, considering the confidence level at 95%, with expected frequency 75%. The sample was distributed as follow 90 LCRs for male with 30 LCRs allocated for each class likewise for female apart from Class III where only 25 LCRs were available.

Lateral cephalometric radiograph records measurements of ST

The KODAK 9000 Extra oral Imaging System at 80 kvp, 10 mA was used with 0.500 second exposure time. Digital software (Vista Dent) was used for analysis of the lateral cephalometric radiographs. This included measuring the size of ST and as such running cephalometric analysis to determine the skeletal classification. As for measuring the size (length, depth, AP diameter) of ST, the linear measurements in the current study located in the midsagittal plane as suggested by Silverman.¹⁰

1. The length of ST determined by measuring the distance from the tuberculum sella to the tip of the dorsum sella.
2. The depth of the ST determined by measuring a perpendicular line from the line above to the deepest point on the floor.
3. The anteroom-posterior diameter of ST: determined by a line drawn from the tuberculum sella to the furthest point on the posterior inner wall of the fossa (Figure 1).

With respect to shape of ST the two well-known classifications of ST for Gordon and Bell (1922) and Axelsson et al (2004) were used to determine the ST shape. Gordon and Bell¹¹ suggested three different morphological appearances, circular, oval, and flat sella shapes (Figure 2). However, Axelsson et al¹² proposed six different morphological appearances of ST: 1) normal; 2) oblique anterior wall; 3) irregularity (notching) in the posterior part of the dorsum sellae 4) bridging; 5) double contour of the floor; and 6) pyramidal shape of the dorsum sellae (Figure 3).

Ethical considerations

The study was reviewed and granted approval (TUCDREC/2018102/Qutub) by Research Ethical Committee of Taibah University. All procedures followed were in accordance with the Helsinki declarations, patients' personal information were coded and the researchers only had access to the records.

Statistical analysis

Descriptive statistics (mean±SD and frequency and percentages) was performed to report sample demographic characteristics and ST dimensions. The intra and inter raters' reliability (test re-test intraclass correlation coefficient [ICC]) was checked and ICC was between 0.98-0.99. Bivariate analysis chi-squared test was performed to examine association of gender with ST classifications and unpaired T-Test to compare the ST dimension (length, depth and AP diameter) between males and females. Also, ANOVA was run to compare the means of the ST dimensions for the three different skeletal classes and the means of the three dimensions for the three skeletal within genders (male and female). If ANOVA was significant a *post hoc* pairwise comparisons using Bonferroni correction method was run to identify significantly different pairs. The significant level was set at $p \leq 0.05$ for all tests. The Statistical Package for Social Sciences Software (SPSS) for windows was used for data analysis.

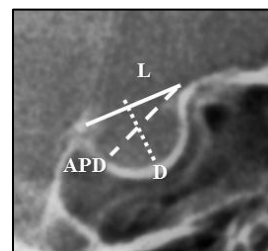


Fig. 1: Linear measurements of ST. L- length, D- depth, and APD- anteroposterior diameter

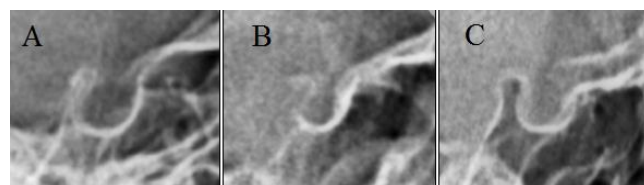


Fig. 2: Classification of the three types of ST: (A) Circular, (B) Oval, (C) Flat Based on Gordon and Bell.

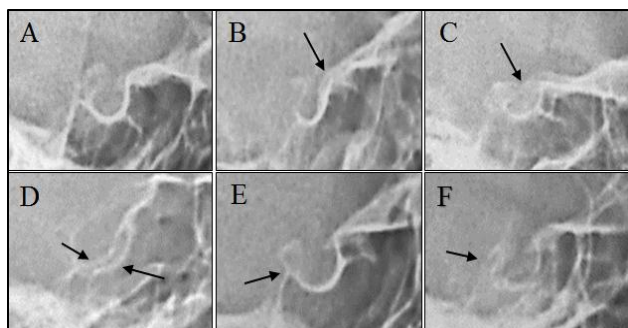


Fig. 3: Morphological variations of ST shape. (A) Normal, (B) Oblique anterior wall “arrow”, (C) sella turcica bridging “arrow”, (D) double contour of floor “arrows”, (E) irregular (notching) dorsum sella “arrow”, (F) pyramidal shape “arrow” based on Axelsson.

Results

The mean±SD age of the patients was 27.43± 7.54 years. The age for male in skeletal Class I, II, III was 27.60 ±10.69, 26.76 ±6.75, 25.46 ±5.43 years and for female was 27.53 ±7.27, 28.16 ±5.68, 29.36 ±8.35 years, respectively.

Gender comparisons of ST skeletal size

The total comparisons of skeletal size (length, depth and A-P diameter) for Class I, II, II for both male and females revealed that male had statistically significant (p <0.05) larger length, depth and A-P diameter (Table 1). The differences between male and female in ST size was further observed per each skeletal class (Table 1), apart from the depth in Class I and class II which were comparable between both groups (p>0.05).

Comparisons of ST size between different skeletal classifications

In (Table 2) the one-way analysis of variance (ANOVA) shows that there were no statistical significant differences (p>0.05) in length, depth and A-P diameter between all skeletal classifications. This was further observed between skeletal classes grouped based on gender (p>0.05).

Sella Turcica shapes

According to Gordon and Bell’s classification our results revealed a majority of circular 43% and flat 39% ST shapes.

Table 2: Comparison of ST dimensions between different skeletal classes, using one-way ANOVA test.

Variable	Length Mean±SD	Depth Mean±SD	A-P Diameter Mean±SD
Both genders			
Skeletal I (n=60)	9.00 ±2.83	7.43 ±1.79	11.17 ±2.09
Skeletal II ((n=60)	8.75 ±2.84	7.22 ±1.55	11.13±1.88
Skeletal III (n=55)	8.73 ±2.77	7.33 ±1.77	10.98 ±2.29
p-value	0.841	0.809	0.886
Male			
Skeletal I (n=30)	10.91 ±1.34	7.69 ±1.84	12.23 ±1.82
Skeletal II ((n=30)	10.37 ±1.82	7.61 ±1.41	11.65 ±2.05
Skeletal III (n=30)	10.40 ±1.83	8.17 ±1.55	12.05 ±1.83
p-value	0.386	0.352	0.488

Skeletal Class I patients had 55% circular shape, and skeletal Class II had 53% flat shape (Table 3). However, according to Axelsson¹⁰ the morphology of ST in our study appeared normal in majority of patients 53% regardless of the patient’s gender or the skeletal type, while variation in the shape was present in 47% of the subjects. The least reported of the variations was the pyramidal shape, in only 4 subjects. Females showed higher prevalence of ST shape variations 64.7% than males 30%. All skeletal classes have more than half of subjects with ST of normal shape (Table 4).

Table 1: Comparison of ST dimensions based on gender

Total			
Dimensions	Male (n-90)	Female (n-85)	P-value
	Mean±SD	Mean±SD	
Length	10.56 ±1.68	6.99 ±2.58	0.0005
Depth	7.87 ±1.61	6.80 ±1.63	0.0005
A-P Diameter	11.98 ±1.90	10.17 ±1.86	0.0005
Skeletal Class I			
Dimensions	Male (n-30)	Female (n-30)	P-value
	Mean±SD	Mean±SD	
Length	10.91 ±1.34	7.10 ±2.65	0.0005
Depth	7.69 ±1.84	7.61 ±1.72	0.255
A-P Diameter	12.23 ±1.82	10.10 ±1.80	0.0005
Skeletal Class II			
Dimensions	Male (n-30)	Female (n-30)	P-value
	Mean±SD	Mean±SD	
Length	10.37 ±1.82	7.12 ±2.77	0.0005
Depth	7.61 ±1.41	6.84 ±1.62	0.570
A-P Diameter	11.65 ±2.05	10.60 ±1.56	0.0005
Skeletal Class III			
Dimensions	Male (n-30)	Female (n-25)	P-value
	Mean±SD	Mean±SD	
Length	10.40 ±1.83	6.72 ±2.34	0.0005
Depth	8.17 ±1.55	6.33 ±1.49	0.0005
A-P Diameter	12.05 ±1.83	9.71 ±2.17	0.0005

Female	7.10 ±2.65	7.16 ±1.72	10.10±1.80
Skeletal I (n=30)	7.12 ±2.77	6.84 ±1.62	10.60±1.56
Skeletal II (n=30)	6.72 ±2.34	6.33 ±1.49	9.71± 2.17
Skeletal III (n=25)			
p-value	0.826	0.172	0.205

Table 3: Distribution of the three shapes based on Gordon and Bell classification

Shape	Gender		Skeletal Class			Total
	Male	Female	Class I	Class II	Class III	
Circular	29 (32.2)	47 (55.3)	33 (55)	21 (35)	22 (40)	76 (43.3)
Oval	19 (21.1)	12 (14.1)	7 (11.7)	7 (11.7)	17 (30.9)	31 (17.7)
Flat	42 (46.7)	26 (38.2)	20 (33.3)	32 (53.3)	16 (29.1)	68 (38.8)

*Frequency, (%)

Table 4: Distribution of the six shapes based on Axelsson’s classification

Shape	Gender		Skeletal Class			Total
	Male	Female	Class I	Class II	Class III	
Normal	63 (70)	30 (35.3)	31 (51.7)	32 (53.3)	30 (54.5)	93 (53.1)
Oblique anterior	9 (10)	14 (16.5)	6 (10.0)	8 (13.3)	9 (16.4)	23 (13.1)
Irregular dorsum	6 (6.7)	17 (20)	7 (11.7)	8 (13.3)	8 (14.5)	23 (13.1)
Bridging	9 (10)	9 (10.6)	7 (11.7)	8 (13.3)	3 (5.5)	18 (10.3)
Double contour	1 (1.1)	13 (15.3)	8 (13.3)	3 (5)	3 (5.5)	14 (8)
Pyramidal	2 (2.2)	2 (2.4)	1 (1.7)	1 (1.7)	2 (3.6)	4 (2.3)

*Frequency, (%)

Discussion

In the current study data from subjects of 15 years and older were analyzed retrospectively to investigate the morphological variations in structure and size of the ST in both genders with different skeletal classes in Al-Madinah, Saudi Arabia.

In regards to the size of ST, we have detected a significant difference in the three dimensions (length, depth, and AP diameter) between males and females in all three-skeletal classes with males showing larger dimensions. These findings contrary to number of studies^{8,13-16} which reported no statistically significant dimensions’ differences based on gender and these studies were reported from different settings (Saudi Arabia, Pakistan, Iraq, Nigeria and India). One should consider the role of several factors such as: age, ethnicity, geographic area and method of measuring of the study samples. However, when considering certain dimension of ST size among male and female, multiple studies^{12,17,18} showed that there was a significant difference in the length of ST based on gender. Notably, adult males had bigger length compared to adult females and these findings in line with our study findings.

Upon comparing ST dimensions based on the skeletal class, no significant differences were noted in this study between Class I, II, or III, not even upon comparing skeletal classes under the same gender. Most previous studies^{13,14,16,19-21} reported coinciding findings, more specifically Yousif et al, Shah et al, and Valizadeh et al investigated skeletal differences in subjects older than 15 years. Similar to our investigation we did involve those age groups to avoid any changes in the size or shape of ST due to remodeling at younger ages.²² On the contrary only Alkofide⁸ and Sathyanarayana et al¹² showed significant difference between diameter and length of ST and the skeletal class, being both larger in skeletal class III. Unlike

the current study they included young age groups as young as 9 years old that might played a role in the findings.

Gordon and Bell were among the first who categorized the shape of ST in normal individuals based on how it appeared on a sagittal cross section on the projected radiograph. They described three basic shapes: circular, oval, and flat. Their investigations on 104 normal children revealed the predomination of the circular shape in most age groups.¹¹ Moreover, 1000 adults were studied by Camp for their ST shape and concluded that most shapes were either circular or oval.² Preston had similar findings in a sample of 182 Caucasians in which flat sellae were revealed in less than 10% of the subjects, and could not find a relationship between any shape and the skeletal class.¹⁹ In a sample of 228 Nigerians, Zagga et al²³ found that oval ST was significantly greater than other shapes (83%). On the contrary, a study on 200 Koreans revealed that the floor of ST was of flat in more than half of the subjects.²⁴ In the current study, circular shape showed predominance 43%, but unlike previous studies flat shape also predominated with 39%. In addition, skeletal Class I showed 55% subjects with circular ST, skeletal Class II showed 53% flat ST, while skeletal Class III was almost evenly distributed over the three shapes.

In 2004, Axelsson et al. elaborated on a more detailed description of the different shapes of normal ST¹², in which it was the most popularly used in the recent literature. They have described five variations from the normal sella shape that was originally based on the sella described by Bjork and Skieller.²⁵ They found that 68% of ST had normal shape, and several other studies were in consistent with normal shape ranging between 61% and 76%.^{8,13,14,17} Our finding was comparable, with 53% of ST had normal shape. On the contrary, few studies showed that less than half of the subjects had normal shape.^{16,20,21}

In our study, shape variations were predominantly seen in females 65%, while males showed only 30% shape variations. One variation was an oblique anterior wall of ST, in literature it presented a range of as low as 4% up to 14.5%^{8,12-14,17,21} except for 2 studies in Iran and India where they showed high occurrence with 20% and 29%, respectively^{16,20}. In the current study, oblique anterior wall was seen in 13% of the cases in line with the range seen from previous studies. In previous studies, ST with irregularities in the posterior wall ranged between 5.5% and 22%^{8,12-14,16,17,20,21,26} our finding was within the range (13%).

In regards to bridging of ST, results from previous studies were oscillating. Alkofide⁸ and Yousif et al¹⁴ reported prevalence of 1.1% and 0.76%, respectively, and Shah et al¹³ did not detect any cases with ST bridging. Valizadeh et al²⁰ reported a relatively very high bridging prevalence of 23% in Iranian adults, most of them were of skeletal Class III type. In most studies bridging was in the range of 7.5% - 11%^{12,16,17,21,26}, and the majority were predominating in patients with skeletal Class III^{14,17,20}. Consistently, in this study ST bridging showed a prevalence of 10.3%; however, most of the subjects were of Class I and II skeletal type as it also was reported by Magat et al²¹ and Oktem et al.²⁶ Although Axelsson reported a single case of ST with double contour of the floor¹², later studies revealed a higher prevalence 3.5%-10%^{8,13,14,16,17,20,21,26}. Our study was in the same range with 8% prevalence of double contouring. The prevalence of pyramidal variation of ST was among the least in literature. In most studies it was as low as 2.8% and up to 8%^{8,12,13,16,17}; however, Oktem et al²⁶ and Magat et al²¹ reported unusual higher prevalence 14% and 15.5%, respectively. Our finding was in consistency with most studies having a prevalence of 2.3%.

The main strengths of the study include the range of age investigated in this study compared to other studies elsewhere, in addition, the setting of the study i.e. this area is well known by diverse ethnicity groups though not investigated and finally, the consistency (calibration and reliability of measurements) in measuring different aspect of ST. However, limitations of the study were identified and this included data obtained was from one center, therefore, generalizability of the results is not appropriate.

Conclusion

Significant gender variations in size of the ST was found among this study sample though the size of ST was non-significantly different between the three skeletal classes, notably, larger size among males. In addition, normal shape of ST was more common than other shape variations, while most of the variations were predominant in females. ST bridging was not limited to Class III skeletal as majority of subjects were of skeletal Class I and II types. Class I skeletal individuals showed more circular shape sella and class II showed more flat shape sella. The results of this study could be considered as a reference for ST shape and dimensions in Madinah, and addition to the pool of knowledge in Saudi Arabia and the region, which together

with the existing data base will provide a valuable guide and norms for future studies.

Source of Funding: None.

Conflict of Interest: None.

References

- Sathyanaarayana HP, Kailasam V, Chitharanjan AB. Sella turcica-Its importance in orthodontics and craniofacial morphology. *Dent Res J* 2013;10(5):571-5.
- Camp JD. Normal and pathologic anatomy of the sella turcica as revealed by roentgenograms. *Am J Roentgenol* 1924;12, 143-56.
- Gordon MB, Loomis Bell AL. Further roentgenographic studies of the sellaturcica in abnormal children. *J Pediatr* 1936;9(6):781-90.
- Kantor ML, Norton LA. Normal radiographic anatomy and common anomalies seen in cephalometric films. *Am J Orthod Dentofac Orthop Off. Publ. Am. Assoc. Orthod. Its Const. Soc. Am. Board Orthod.* 1987;91(5):414-26.
- Kjaer I. Sella turcica morphology and the pituitary gland—a new contribution to craniofacial diagnostics based on histology and neuroradiology. *Eur. J. Orthod* 2015;37(1):28-36.
- Kjaer I, Wagner A, Madsen P, Blichfeldt S, Rasmussen K, Russell B. The sella turcica in children with lumbosacral myelomeningocele. *Eur. J. Orthod* 1998;20(4):443-8.
- Becktor JP, Einersen S, Kjaer I. A sella turcica bridge in subjects with severe craniofacial deviations. *Eur J Orthod* 2000;22(1):69-74.
- Alkofide EA. The shape and size of the sella turcica in skeletal Class I, Class II, and Class III Saudi subjects. *Eur J Orthod* 2007;29(5):457-63.
- Snyder LH, Blank F. Studies in human inheritance. XXVII, the inheritance of the shape of the Sella turcica. *Ohio J Sci* 1945;45:12-5.
- Silverman FN. Roentgen standards for size of the pituitary fossa from infancy through adolescence. *Am J Roentgenol Radium Ther Nucl Med* 1957;78(3):451.
- Gordon MB, Bell AL. A roentgenographic study of the sella turcica in normal children. *New York State J Med* 1922;22: 54-9.
- Axelsson S, Storhaug K, Kjaer I. Post-natal size and morphology of the sella turcica. Longitudinal cephalometric standards for Norwegians between 6 and 21 years of age. *Eur J Orthod* 2004;26(6):597-604.
- Shah AM, Bashir U, Ilyas T. The shape and size of the sella turcica in skeletal class I, II & III in patients presenting at islamic international dental hospital, Islamabad. *Pakistan Oral Dent J.* 2011;31(1):102.
- Yousif HA, Mohammed Nahidh BDS, Yassir YA. Size and morphology of sella turcica in Iraqi adults. *Mustansiria Dent J* 2010;7(1):23-30.
- Osunwoke EA, Mokwe CR, Amah-Tariah FS. Radiologic measurements of the sella turcica in an adult Nigerian population. *Int J Pharm Res* 2014;4:115-7.
- Nagaraj T, Shruthi R, James L, Keerthi I, Balraj L, Goswami RD. The size and morphology of sella turcica: A lateral cephalometric study. *J Med Radiol Pathol Surg* 2015;1:3-7.
- Sathyanaarayana, Haritha Pottipalli; Kailasam, Vignesh; Chitharanjan AB. The Size and Morphology of Sella Turcica in Different Skeletal Patterns among South Indian Population: A Lateral Cephalometric Study. *J Indian Orthod Soc* 2013;47(4):266-71.
- Abu Ghaida JH, Mistareehi AJ, Mustafa AG, Mistarihi SMA, Ghozlan HH. The normal dimensions of the sella turcica in Jordanians: A study on lateral cephalograms. *Folia Morphol* 2017;76(1):1-9.
- Preston CB. Pituitary fossa size and facial type. *Am J Orthod* 1979;75(3):259-63.
- Valizadeh S, Shahbeig S, Mohseni S, Azimi F, Bakhshandeh H. Correlation of Shape and Size of Sella Turcica With the Type of Facial Skeletal Class in an Iranian Group. *Iran J Radiol* 2015;12(2).
- Magat G, Ozcan Sener S. Morphometric analysis of the sella turcica in Turkish individuals with different dentofacial skeletal patterns. *Folia Morphologica* 2018;77(3):543-50.

22. Afrand M, Ling CP, Khosrotehrani S, Flores-Mir C, Lagravère-Vich MO. Anterior cranial-base time-related changes: A systematic review. *Am J Orthod Dentofacial Orthop* 2014;146(1):21-32. 6.
23. Zagga A D, Ahmed H, Tadros A A, Saidu S A. Description of the normal variants of the anatomical shapes of the sella turcica using plain radiographs: Experience from Sokoto, Northwestern Nigeria. *Ann Afr Med* 2008;7:77-81
24. Choi WJ, Hwang EH, Lee SR. The study of shape and size of normal sella turcica in cephalometric radiographs. *Korean J Oral Maxillofac Radiol* 2001;31(1):43-9.
25. Bjork A, Skieller V. Normal and abnormal growth of the mandible. A synthesis of longitudinal cephalometric implant studies over a period of 25 years. *Eur J Orthod* 1983;46.
26. Öktem H, Tuncer Nİ, Şençelikel, T, et al. Sella turcica variations in lateral cephalometric radiographs and their association with malocclusions. *Anatomy* 2018;12(1):13-9.

How to cite this article:Badri M K, Alhojaily A A, Qutub A S, Alshaqueeti F K, Jarallah R A, Kassim S. Retrospective analysis of size and morphology of sella turcica in different skeletal patterns in Madinah, Saudi Arabia. *Indian J Orthod Dentofacial Res* 2019;5(4):137-42.