

## Condemn thumb sucking, not the child

Sana Akhtar<sup>1</sup>, Mohd Ghaus Ali<sup>2</sup>, Neha Priya<sup>3</sup>, Meenakshi Singh<sup>4</sup>, Sagun Rajpal<sup>5</sup>, Chaitra T.R<sup>6\*</sup>

<sup>1-5</sup>Post Graduate Students, Dept. of Pedodontics and Preventive Dentistry, Kothiwal Dental College and Research Centre, Moradabad, Uttar Pradesh, India

### Abstract

Thumb sucking or non-nutritive sucking is considered as the most prevalent oral habit. This habit can be empty or meaningful with a deep rooted psychological connection. The problem must be approached with care and understanding. Many dental problems like jaw disorders, dental caries, palatal narrowing, malocclusion, anterior open bite, movement of canine teeth, narrowing of maxilla, intrusion of anterior teeth and cross bite development are associated with thumb sucking. The treatment planning varies with the age, gender and emotional status of the child. The approach to the treatment will vary from child to child.

**Keywords:** Habit, Thumb sucking, Bluegrass appliance.

### Introduction

Thumb sucking or non-nutritive sucking is a common habit among young children. Non-nutritive sucking is often considered as the first step in the child's self-regulation and also in the emotional development.<sup>1</sup> According to Sigmund Freud, thumb sucking is natural for an infant and young child<sup>2</sup> and is associated with the oral phase of child development. Prolonged sucking after infancy and young adulthood is linked with emotional instability.<sup>3</sup> Benjamin's Learned Theory believes in what is called as the rooting and placing reflex to be initiator of thumb sucking.<sup>3</sup>

Thumb/finger sucking is considered to be the most prevalent oral habit, with a reported incidence ranging from 13% to almost 100% at some time during infancy.<sup>4</sup> Prevalence is influenced by many factors such as sex, birth rank, feeding method and socio-economic status. In a retrospective survey conducted in Central Kerala, India on 1034 children between 4-13 years of age (478 males and 556 females), the prevalence of oral habits was found to be 72.7% where thumb sucking was seen in 17% children.<sup>5</sup> Internationally, the prevalence estimation for digit sucking varies in between 34-90% in the early stages of life.<sup>6</sup>

The problem of thumb sucking must always be approached with care and understanding. In most cases, the problem can be completely eliminated while in some, it can only be prevented. Thumb sucking can be meaningful and empty.<sup>7</sup> A meaningful habit is a psychological problem and should be treated as such with the psychological approach, while an empty habit is a dental problem and should be treated by a dentist from the dental approach, that is, with a habit reminder.

Thumb suckers can really damage their teeth in long term. Most common problems associated are jaw disorders, dental caries, palatal narrowing, malocclusions, anterior open bite, movement of canine teeth, narrowing of maxilla, intrusion of anterior teeth and cross bite development.<sup>8</sup> This

case report describes the correction of thumb sucking habit of a 10-year-old child.

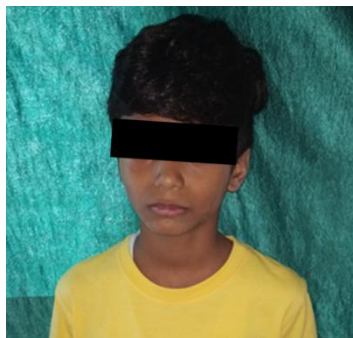### Case Report

A 10-year-old came with his parents to the Department of Pedodontics and Preventive Dentistry, Kothiwal Dental College and Research Centre, Moradabad. The guardians complained of the child sucking his thumb while sitting idly, watching television, using mobile phone and while sleeping. Various chemical methods were already used by the parents and several dental appliances were also given in the previous year but everything failed. The child was thin, quiet and shy. He was constantly looking down throughout the appointment. In the first appointment, small conversations were made with the child to make him comfortable and also to understand the family. It was noted that he lived in a joint family, was the second child in his family, and was always criticized for his bad performance in school and was compared with his over performer elder sister. Also, he was regularly scolded and sometimes made fun of for his habit by the family members, especially his father. The parents were asked for psychiatric consultation, for which they were not very willing. The family was informed about the harmful effects of the habit. The parents were told to completely ignore the habit from then, and the child was made happy by asking about the things he liked, about his favourite cartoon characters, his favourite games, his ambition to become a police officer in future. The family was recalled after 3 days. In this appointment, the photographs and other records were taken. Communication to understand and to make him feel comfortable were made again. By the end of the second appointment, the child was smiling and was talking willingly.

\*Corresponding Author: Chaitra T.R, Dept. of Pedodontics and Preventive Dentistry, Kothiwal Dental College and Research Centre, Moradabad, Uttar Pradesh, India

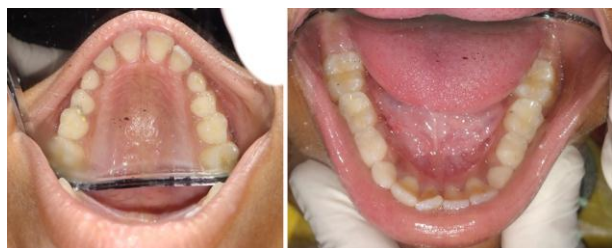Email: [chaitu4363@yahoo.co.in](mailto:chaitu4363@yahoo.co.in)

<http://doi.org/10.18231/j.ijodr.2019.025>

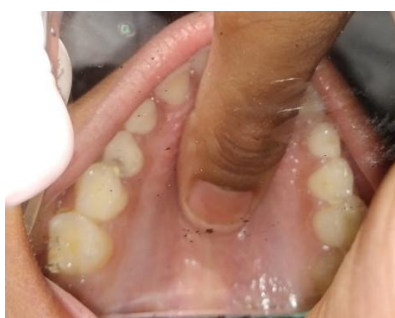

**Fig. 1:** Thin and quiet child

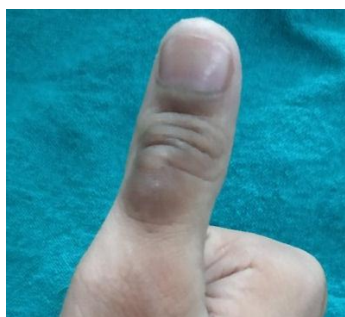Extraoral examination revealed a straight profile and a clean right thumb with short nail and callus formation. On intraoral examination, V-shaped upper and U-shaped lower arches were seen and the placement of thumb was adjacent to the first and the second primary molars. The treatment plan was made to stop the thumb sucking habit followed by correction of the proclination and spacing present in the upper and lower arches. The treatment was made to correct the habit of thumb sucking followed by fixed orthodontic treatment for the correction of the malocclusion.



**Fig. 2:** V-shaped maxillary and U-shaped mandibular arches

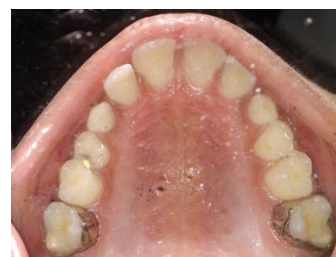

**Fig. 3:** Position of thumb in mouth



**Fig. 4:** Clean, short nailed thumb with callus formation

In the next appointment, after 3 days, the child was friendly, and not scared by the procedure. He was pre-informed about each step and his permission was taken before every step. The bands were fabricated on the first permanent molars followed by the impressions of the upper and the lower arches. A hand puppet, in shape of a policeman, was given to the child to keep on his hand. He was also asked to make a story with the puppet for the next appointment. This was a gift to the child for his good behaviour during the appointment.

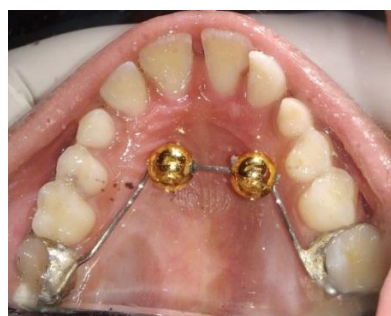


**Fig. 5:** Bands fabricated on the first permanent molars



**Fig. 6:** Hand puppet

The child was recalled after 2 days and a modified bluegrass appliance was given to the child. It was checked that the beads were placed to the most palatal part, not touching the palate or the tongue. The instructions were given to roll the beads by tongue instead of thumb sucking until the next appointment. The child was recalled after 10 days.



**Fig. 7:** Bluegrass appliance

After 10 days, the child was asked about the habit. He had not performed that during the period. A gift was given to the child for his success. He was very happy for his achievement. He was again recalled after 1 month. According the family, the child had completely given up his habit by that time. The appliance was kept was 2 more months. The child is kept on follow up for one year for fixed orthodontic intervention.

## Discussion

Thumb sucking is often associated with neuropsychiatric problems and the duty of the dentist must be to illustrate the problem to the child and the parents and not just to force the child to stop the habit. Age appropriate explanation about the ill effects of the continuation of the habit must be told to the child.<sup>9</sup> Positive reinforcement is also very important. The child must be rewarded for making the effort in discontinuation of the habit.<sup>9</sup> A simple contract of not sucking the thumb for a specific time period, known as the contingency contract, is made between the child and the dentist. The child must be rewarded if he keeps the contract.<sup>10</sup> Patience and tolerance is the key to the successful treatment of a meaningful habit.<sup>7</sup> We must not only aim for the habit discontinuation but also, and more importantly, to develop an emotionally secure and well-balanced person.

A constant reminder appliance is given to the child who is willing to stop the habit but requires some assistance.<sup>11</sup> The reminder can be intraoral, that involves the appliances placed inside the mouth, or extraoral. The extraoral appliances can be in the form of chemicals applied to the thumb, adhesive tapes, thumb posts etc. Clinically it has been observed that the chemical substances are not very effective.<sup>12</sup> Adhesive tapes carry risks like infection and restriction of blood circulation.<sup>13</sup> Thumb posts are made up of acrylic and they can be placed on the thumb of the child to cover the thumb. In this case, a hand puppet was given to the child. The puppet act as a reminder for the child and also a toy to express his feelings. Talking through the puppet made it easy for him to express his fears and kept his thumb away from his mouth.

In children with deep rooted habits, appliance therapies are required. The appliances can be removable or fixed. Palatal cribs, spurs, bars, hay rakes etc. are the most commonly given appliances. However, several problems like difficulty in speech and eating, iatrogenically self-inflicted wounds as well as emotional disturbances are encountered with these.<sup>14</sup> Bluegrass appliance, introduced by Haskell and Mink in 1991, is a solution to these problems. It is easy to use, adapt to and non-destructive. In this case, a modified bluegrass appliance was given, that consisted of two 3 millimetre acrylic beads across a palatal wire. It also follows the principles of Castillo-Morales for neuromuscular stimulations.<sup>15</sup> The child is asked to rotate the beads instead of sucking the thumb. The beads have a synergistic effect in reminding the child of the for the interception of the habit and then generates a non-harmful

habit of playing with the beads. Hence, the beads act not only as a reminder but also as a distraction to the child. Haskell and Mink designed this appliance for the children in early or late mixed dentition who had the desire to stop their habit. their usual sucking habit was at night or when they were tired or upset.<sup>16</sup> If habit persists for longer time exhibiting posterior crossbite, modified blue grass appliance can be given with Quad Helix to expand the arch.<sup>17</sup> In a retrospective study done by Stephen Greenleaf and John Mink, success rate of 93% was reported with average reported time for the cessation of the habit to be 12.3 weeks +/- 12.2 weeks.<sup>18</sup>

## Conclusion

Thumb sucking is a very common habit. It must be dealt with a thorough knowledge, understanding, acceptance and open-mindedness. The approach to the treatment will vary from child to child. Our aim must be to stop the habit and to develop an emotionally secure and well-balanced person.

## Source of Funding

None.

## Conflict of Interest

None.

## References

1. Maqurie JA. The evaluation and treatment of pediatric oral habits. *Dent Clin North Am* 2000;44(3):659-69.
2. Freud, S. Three contributions to the theory of sex, in Brill, A.A. (ed.). The basic writings of Sigmund Freud. New York, Random House.1938.
3. Ayer WA, Gale EN. Psychology and thumbsucking. *J Am Dent Assoc* 1970;80(6):1335-7.
4. Shetty RM, Shetty M, Shetty NS, Deoghare A. Three-alarm system: Revisited to treat thumb-sucking habit. *Int J Clin Pediatr Dent* 2015;8(1):82-6.
5. Anila S, Dhanya RS, Thomas AA, Rejeesh TI, Cherry KJ. Prevalence of oral habits among 4–13-Year-Old children in Central Kerala, India. *J Natural Sci Biol Med* 2018;9(2):207-10.
6. Khayami S, Bennani F, Farella M. Fingers in mouths: from cause to management. *NZ Dent J* 2013;109(2):49-50.
7. Klein ET. The thumb-sucking habit: Meaningful or empty?. *Am J Orthod* 1971;59(3):283-9.
8. Karimi M. Dental Complications of Sucking Thumbs. Interventions In Pediatric Dentistry: *Open Access J* 2018;1(3):38-40.
9. Van Norman R. Digit sucking: It's time for an attitude adjustment or a rationale for the early elimination of digit-sucking habits through positive behavior modification. *Int J Orofacial Myology* 1985;11:14-21.
10. Srinivasan D, Aegappan S, Louis J. Management of Persistent Non Nutritive Sucking Habit. *Chettinad Health City Med J* 2012;1(2):62-4
11. Gairuboyina S, Chandra P, Anandkrishna L, Kamath PS, Shetty AK, Ramy M et al. Non-nutritive Sucking Habits: A Review. *J Dent Oro-facial Res* 2014;10(2):22-7.
12. Alemran SE. A new method in reminder therapy technique for ceasing digit sucking habit in children. *J Clin Pediatr Dent* 2000;24:261-3
13. Benjamin LS. The beginning of thumb sucking. *Child Dev* 1967;38:1065-78

14. Diwanji A, Jain P, Doshi J, Somani P, Mehta D. Modified bluegrass appliance: a nonpunitive therapy for thumb sucking in pediatric patients—a case report with review of the literature. *Case Rep Dent* 2013;1-4.
15. Kelly G, Pritchard M, Thompson S. The use of orofacial regulation therapy, including Palatal Plate Therapy, in the management of orofacial dysfunction in patients with Down syndrome. *J Disabil Oral Health* 2012;14(1):15-24.
16. Haskell BS, Mink JR. An aid to stop thumb sucking: the "Bluegrass" appliance. *Pediatr Dent* 1991;13(2):83-5.
17. B. S. Haskell, "Construction of a habit correction roller with arch expansion: chair side application of a new 2 piece bondable "Bluegrass" appliance," *J South Eastern Soc Pediatr Dent* 2002;8(1):22–6.
18. Greenleaf S, Mink J. A retrospective study of the use of the Bluegrass appliance in the cessation of thumb habits. *Pediatr Dent* 2003;25(6):587-90.

**How to cite this article:** Akhtar S, Ali MG, Priya N, Singh M, Rajpal S, Chaitra TR. Condemn thumb sucking, not the child. *Indian J Orthod Dentofacial Res* 2019;5(3):117-120.