

Intrusion of bilaterally supraerupted maxillary first molars: A simple, clinically noninvasive approach

Sujit Navnath Zadake^{1*}, Pravinkumar Marure², Suresh Kangane³, Anand Ambekar⁴

¹Post Graduate Student, ²Associate Professor, ³Professor and HOD, ⁴Professor and PG Guide, ¹⁻⁴Dept. of Orthodontics, ¹⁻⁴Maharashtra Institute of Dental Sciences & Research Dental College, Latur, Maharashtra, India

Abstract

Loss of the mandibular first permanent molar causes the supraeruption of the opposing maxillary first molar that often leads to occlusal interference, loss of periodontal bony support, and inadequate area to restore the mandibular edentulous space. It is highly impossible to restore the posterior occlusion without orthodontic molar intrusion or segmental surgical impaction, which often suggest the need for significant reduction of maxillary molar crown height, with the potential need for costly iatrogenic root canal therapy and restoration. Supra-erupted maxillary first molars are most frequently seen in adult patients because of the loss of contralateral tooth. This article discuss about a novel technique for first-molar intrusion with a helix incorporated in arch wire and intrusion arm soldered to Trans-palatal arch.

Keywords: Supra-erupted, Molar intrusion, Edentulous space, Noninvasive, Contralateral tooth.

Introduction

Bilateral loss of the mandibular first permanent molar causes supra-eruption of the opposing maxillary first molars, resulting in occlusal interference and functional disturbances, compromised periodontal health, and increased complexity of restoring the edentulous space. Though many authors have suggested the use of temporary anchorage devices (TADs) for molar intrusion, its impact on patient's psychology demonstrates it to be an invasive procedure. [1, 2] This article focuses on achieving molar intrusion with a clinically noninvasive approach.

Appliance fabrication, placement, and biomechanics

Material required: Stainless steel molar bands, 0.017 x 0.025 inch rectangular stainless steel arch wire, molar tube, 19 gauge stainless steel wire, solder, flux, and weldable lingual buttons.

1. The band was made on to over-erupted first molar and adjacent second maxillary molar and transferred to study cast. (Fig. 1)
2. Transpalatal arch (TPA) was fabricated for maxillary second molar, by using 19 gauge stainless steel wire. Also the intrusion arm with open helix was constructed with the same wire (19 gauge S.S.) and it is soldered to TPA, 2mm away from the palatine soft tissue.
3. This modified TPA is then secured into the lingual sheath which is welded on the molar band on maxillary second molar. The band was then cemented. (Fig. 2)
4. On the band of over-erupted first molar, lingual buttons were welded with one on each, buccal and palatal surfaces. The band was then cemented. (Fig. 2)
5. 0.017 x 0.025 inch rectangular S.S. is bent at 90° distal to second premolar bilaterally, then wire is carried into the buccal vestibule with a helix of 2mm diameter. The helix

was adjusted so as to lie at the height of the center of resistance as well as the mesio-distal center of the over-erupted molar. Wire is then bent downward and again at 90° mesial to second molar to engage into molar tube. (Fig. 3)

6. For intrusion, elastomeric chain (E – chain) was attached from helix of rectangular S.S. wire, involving the welded button (on buccal side), then crossing over the occlusal surface of the over-erupted first molar to the welded button on the opposite side (on palatal side), carried further to the opposing open helix which is soldered to TPA. (Fig. 4).



Fig. 1: Molar bands transferred to study cast



Fig 2: Intrusion arm with open helix soldered to TPA

*Corresponding Author: Sujit Navnath Zadake, Dept. of Orthodontics, Maharashtra Institute of Dental Sciences & Research Dental College, Latur, Maharashtra, India

Email: zadakesujit09@gmail.com

<http://doi.org/10.18231/j.ijodr.2019.024>




Fig. 3: 0.017 X 0.025 inch rectangular S.S. archwire bent to form closed helix

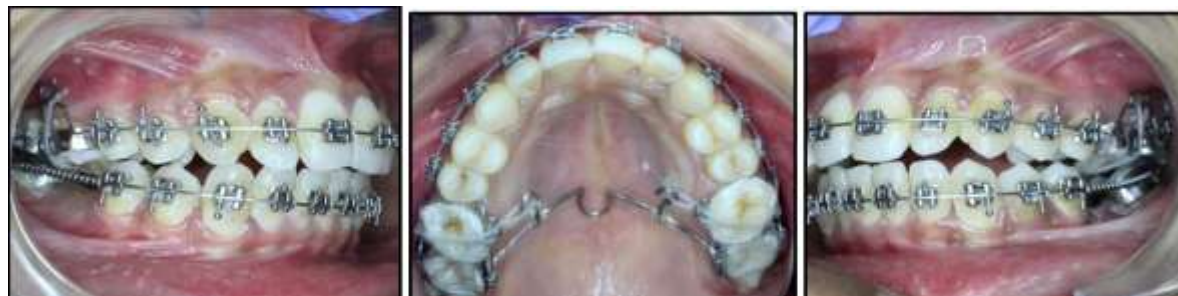

Fig. 4: For intrusion, elastomeric chain was attached from helix of rectangular S.S. wire, involving the welded button on buccal side then crossing over the occlusal surface of the over-erupted first molar to the welded button on the palatal side.

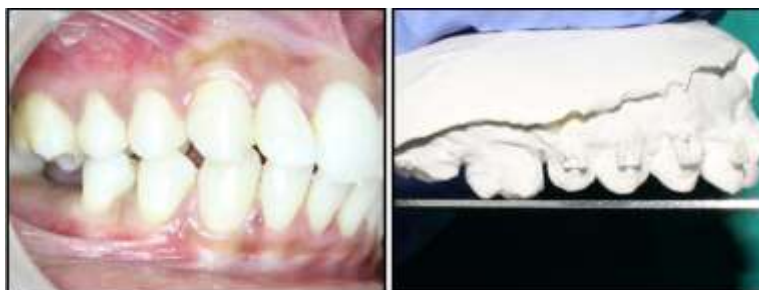

Fig. 5: (Right side), A – Pretreatment photograph. B – Supra-erupted upper right molar.

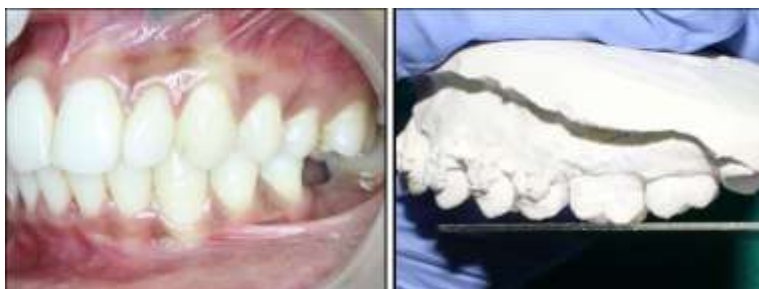

Fig. 6: (Left side), A – Pretreatment photograph. B – Supra-erupted upper left molar.

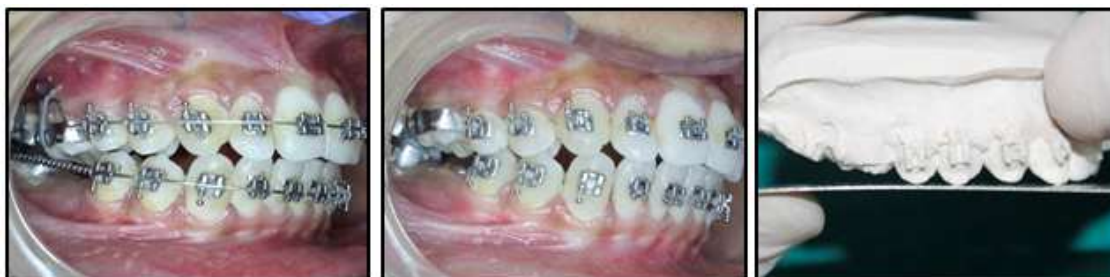

Fig. 7: (Right side) A – Intrusive force applied, B- Post intrusion photograph, C- Post intrusion study model of right side

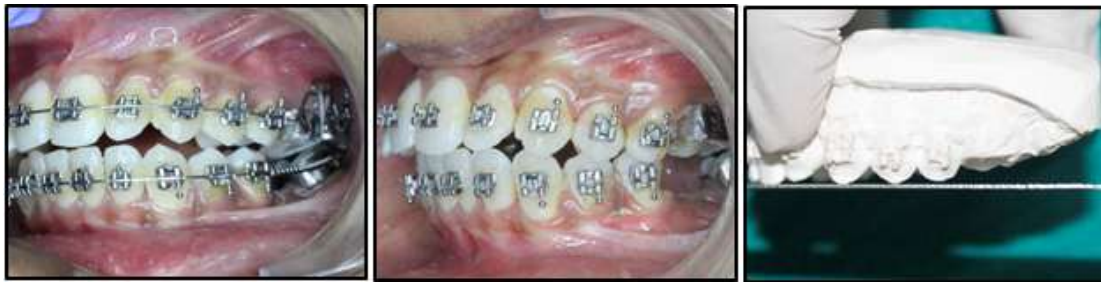

Fig. 8: (Left side), A – Intrusive force applied, B- Post intrusion photograph, C- Post intrusion study model of left side

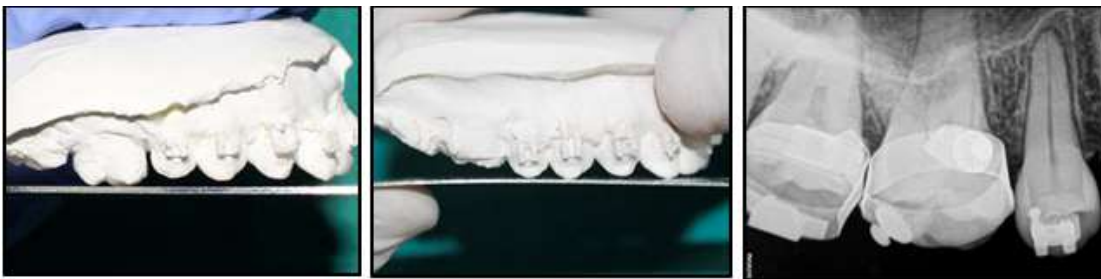

Fig. 9: (Right side) Comparative photographs of before and after intrusion on study models and RVG

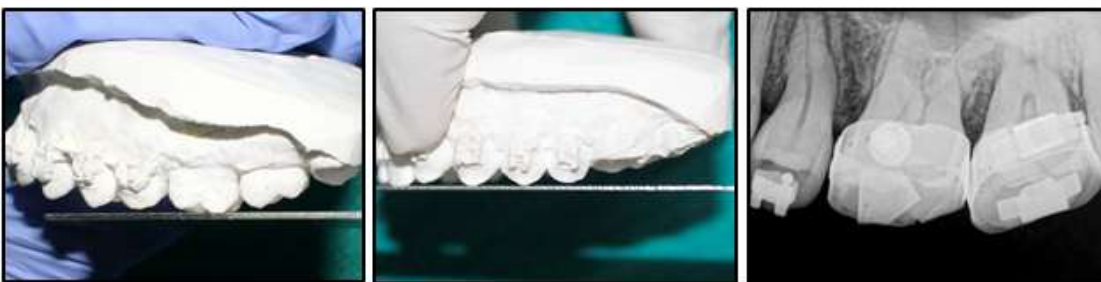

Fig. 10: (Left side) Comparative photographs of before and after intrusion on study models and RVG



Fig. 11: Amount of intrusion was measured by superimposing pre and post-intrusion lateral cephalograms

Biomechanics:

The buccal and palatal forces delivered by the elastomeric chain on over-erupted maxillary molar through the center of resistance achieved equilibrium between buccal and palatal root torque, resulting in a net intrusive force without crown tipping.^{3,4} The main role of TPA was to gain anchorage and to reduce the reactionary extrusive force on first molar.

In the patient shown here, a supra-erupted upper right (Fig. 5A, B) and left first molar (Fig. 6A, B) was intruded. Over intrusion of the maxillary first molars for prosthesis placement was planned. Results are appreciated by

comparing pre and post intrusion photographs, study models, and RVG (Fig. 7-10). Amount of intrusion was measured by superimposing pre and post-intrusion lateral cephalograms. 3mm of intrusion was achieved within 2 months of span (Fig. 11). No evidence of root resorption was appreciated radiographically on RVG (Fig. 12). No ill-effects were observed in the surrounding gingival tissues and bony structures.

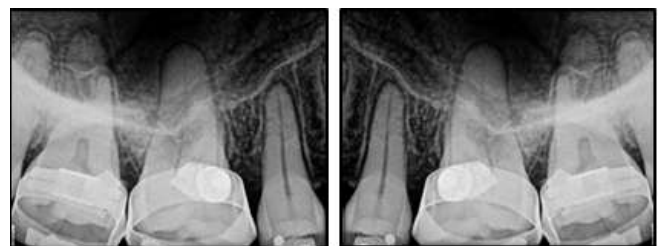

Fig. 12: No evidence of root resorption was appreciated radiographically on RVG.

Advantages

1. Appliance design is simple and easy to fabricate.

2. Less chair side time is required for fabrication of wire component (0.017 x 0.025 S.S.).
3. This is a segmental approach and therefore, can be used bilaterally for right or left side(s).
4. This fabricated appliance design can be used for intrusion of maxillary first and second molar.
5. This segmental approach can be used in those patients who are not exposed to fixed orthodontic treatment.
6. Since the hook of stainless steel wire lies near or in line with the center of resistance of the tooth to be intruded, the intrusion so achieved is effective in nature.

Conclusion

To conclude, this article demonstrates a clinically noninvasive, cost-effective, and simple procedure to achieve an effective bilateral molar intrusion.

Source of Funding

None.

Conflict of Interest

None.

References

1. Celenza F. Implant-enhanced tooth movement: Indirect absolute anchorage. *Int J Periodontics Restorative Dent* 2003;23:533-41.
2. Khera AK, Raghav P, Shivangi. A simplified segmental approach to maxillary molar intrusion. *J Indian Orthod Soc* 2015;49:226-7.
3. Cope JB. Temporary anchorage devices in orthodontics: A paradigm shift. *Semin Orthod* 2005;11:3-9.
4. Roberts-Harry D, Sandy J. Orthodontics. Part 9: Anchorage control and distal movement. *Br Dent J* 2004;196:255-63.

How to cite this article: Zadake SN, Marure P, Kangane S, Ambekar A. Intrusion of bilaterally supraerupted maxillary first molars: A simple, clinically noninvasive approach. *Indian J Orthod Dentofacial Res* 2019;5(3):113-6.