

Odontome associated with impaction of maxillary central incisor: An orthodontic case report

Mridul Khanduri¹, Harmeet Manocha², Merin Paul^{3*}, Prakirti Srivastava⁴

¹Professor and Head, ²⁻⁴Post Graduate Student, ¹⁻⁴Dept. of Orthodontics and Dentofacial Orthopedics, ¹⁻⁴Uttaranchal Dental and Medical Research Institute, Dehradun, Uttarakhand, India

***Corresponding Author: Merin Paul**

Email: paul.merin86@gmail.com

Abstract

Odontomas are the most common type of odontogenic tumors. They are included under the benign calcified odontogenic tumors. Odontomas are basically classified into two types, complex and compound odontomes. Generally, Odontomes are asymptomatic. Occasionally, signs and symptoms relating to their presence do occur in form of impactions. The presence of odontomes in the anterior region more often leads to the impaction of the permanent anterior teeth. We report a case of a 13 year old male, who came to the Department of Orthodontics and Dentofacial Orthopedics, Uttaranchal Dental and Medical Research Institute, Dehradun, Uttarakhand with left maxillary central incisor impaction due to the presence of an odontome in the left maxillary central incisor region. The surgical removal of the odontome was carried out. Combined approach with surgical exposure and the application of an orthodontic force brought the impacted left maxillary central incisor down to its proper position in the dental arch.

Keywords: Odontomes, Impaction, Maxillary Central Incisor Impaction.

Introduction

Odontomas are hamartomatous lesions rather than true neoplasms which are classified into compound and complex.¹ Compound odontomas are malformations in which all the tissues are in organized pattern giving resemblance to the tooth whereas the complex odontomes do not have an organized arrangement of the tissues. These are variable in size and shape; however, whether they are complex or composite type, they usually have broader and wider cross-section and their presence will be more likely to impede the eruption of the central incisors than a supernumerary tooth.

Impactions are quite common in the routine dental practice but the impactions of central incisors are the least frequent impacted teeth with an incidence rate of 0.06- 3%.³⁻⁶ Early diagnosis is very important and interceptive orthodontic treatment could not only improve skeletal malrelationship and eliminate functional interferences, but also may correct disturbances during the eruption.⁸

The maxillary incisors are the most prominent teeth in an individual's smile, they are also the teeth that are on maximum display during speech in most individuals and the

normal eruption, position and morphology of these teeth are crucial to facial esthetics and phonetics.⁹ As missing upper incisors are regarded as unattractive this may have an effect on self-esteem and general social interaction, and it is important to detect and manage the impaction as early as possible.¹⁰

In this case report we discuss the surgical removal of the odontome, followed by the surgical exposure of the impacted central incisor and the orthodontic traction of the impacted central incisor teeth.

Case Report

A 13 year old male came to the Department of Orthodontics and Dentofacial Orthopedics, Uttaranchal Dental and Medical Research Institute, Dehradun, Uttarakhand with the chief complaint of spacing in the upper front region of the jaw. The patient's medical and family history was insignificant. Extraoral examination revealed a mesocephalic and mesoprosopic face with an orthognathic profile and an obtuse nasolabial angle (Fig. 1).

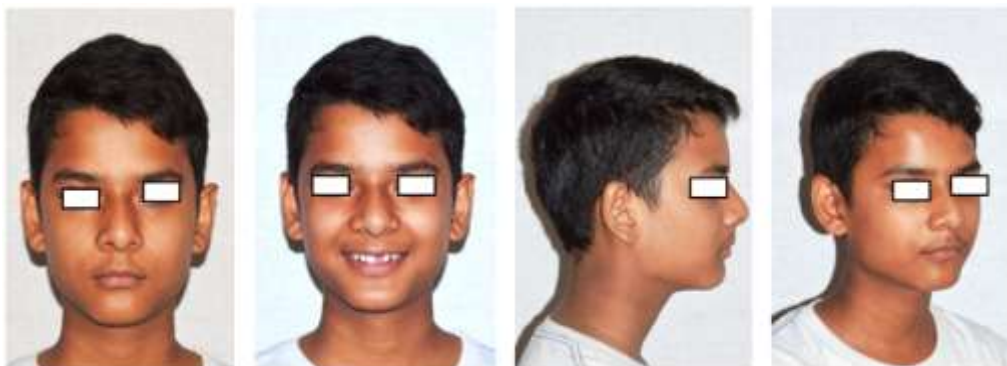

Fig. 1: Pre-treatment Extraoral Photographs

Intraoral examination showed the spacing in the maxillary anterior region along with the clinical absence of a permanent maxillary left central incisor with no evidence of eruption (Fig. 2).

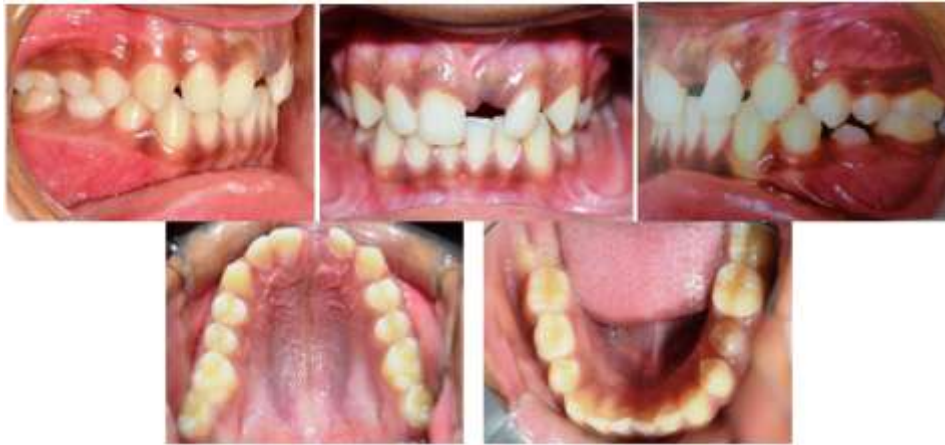

Fig. 2: Pre- treatment Intraoral Photographs

Radiographic examination (maxillary occlusal radiograph) revealed the presence of the impacted maxillary right central incisor and an odontome (Fig. 3).

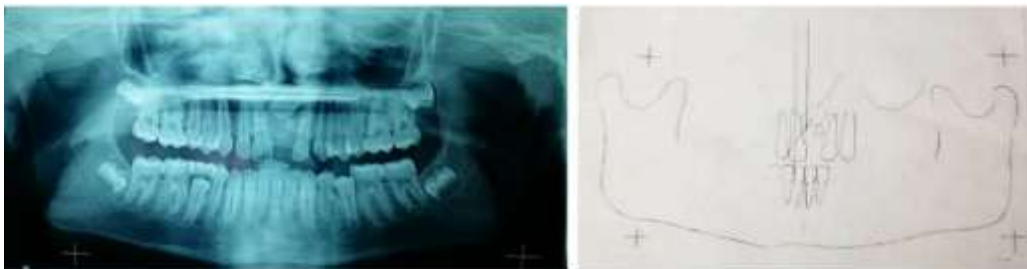

Fig. 3: OPG and classification of the impacted incisor.

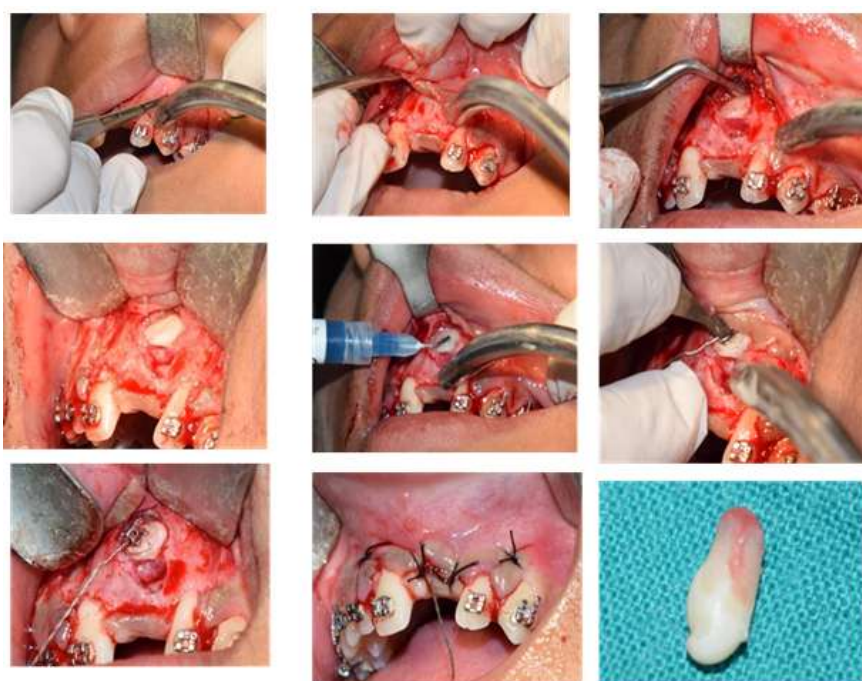
The OPG revealed an α - angle of 25° and the impacted central incisor lies in sector 2 (According to the Ericsson and Kurol Classification)(Fig. 3). Cephhalometric analysis reveals a class II skeletal base with class II molar relation, retroclined upper incisors, proclined lower incisor and a horizontal growth pattern (Fig. 4)(Table-1).

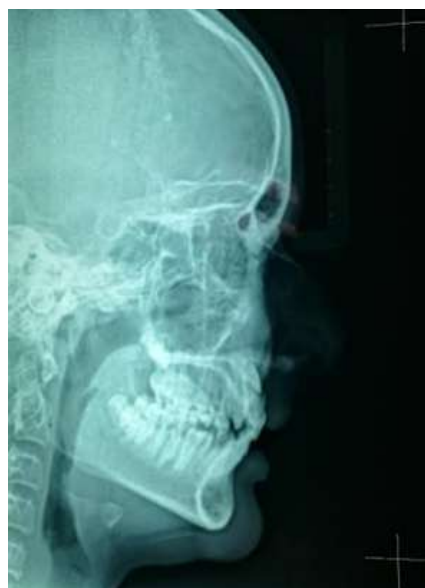

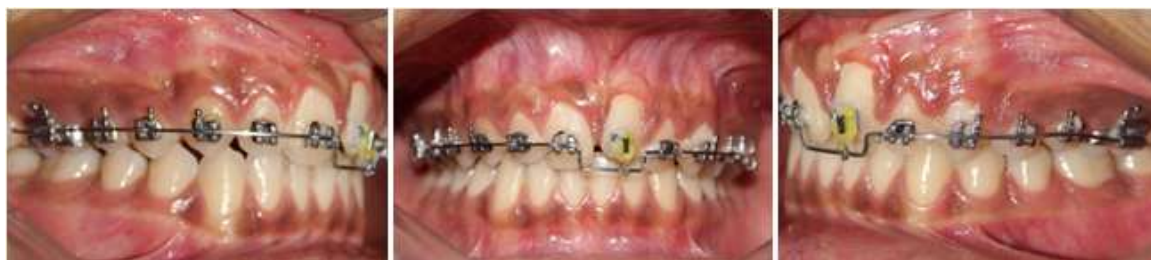Fig. 4: Pretreatment Lateral Cephalogram

Table 1: Pre and Mid Cephalometric values

Criteria	Norm	Pre-Treatment	Mid- treatment
SNA	80-82 ⁰	84 ⁰	83 ⁰
SNB	78-80 ⁰	78 ⁰	78 ⁰
ANB	2 ⁰	6 ⁰	5 ⁰
U1-NA	22 ⁰	18 ⁰	12 ⁰
L1-NB	25 ⁰	27 ⁰	27 ⁰
U1-L1	131 ⁰	160 ⁰	136 ⁰
GoGn-Sn	32 ⁰	23 ⁰	24 ⁰
L1-APog	2mm	2mm	3mm
Y-Axis	53 ⁰ -66 ⁰	66 ⁰	63 ⁰
FMPA	25 ⁰	20 ⁰	18 ⁰
IMPA	90 ⁰	105 ⁰	104 ⁰
Wits Appraisal	-2 -4mm	6mm	2mm
Jarabak's Ratio	62- 64	76	78.30

**Fig. 5:** Surgical removal of odontome and surgical exposure of the impacted central incisor and placement of the attachment**Fig. 6:** Mechanics for the traction of impacted central incisor

The bone and the connective tissue covering the tooth were removed, and the odontome was removed and sent for pathological examination. Crown was exposed for bonding the Beggs bracket n with a ligature wire tied to it. The flap was closed after bonding the lingual button, and the ligature wire was brought out and passively tied to the archwire. After 2 weeks, orthodontic traction of the impacted incisor was started (Fig. 6). 10 months since the commencement of the orthodontic therapy the central incisor was successful results were seen in the patient (Fig. 7 and 8).

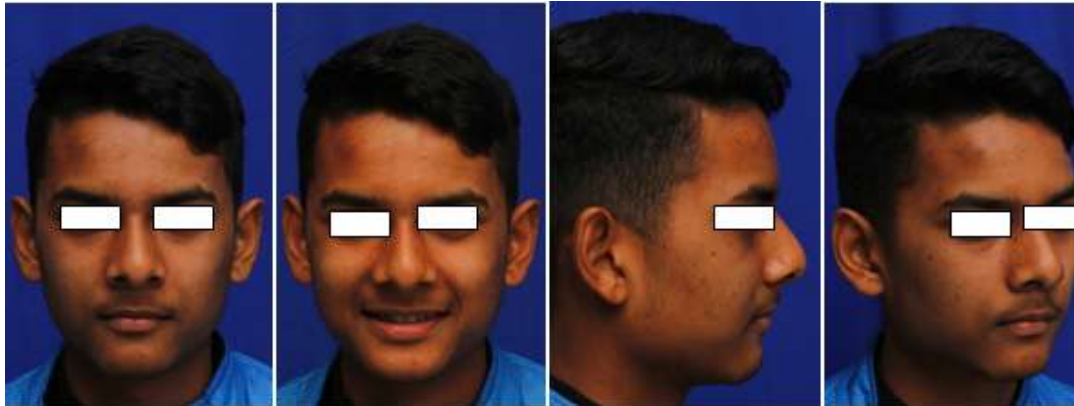


Fig. 7: Mid- treatment Extra oral Photographs

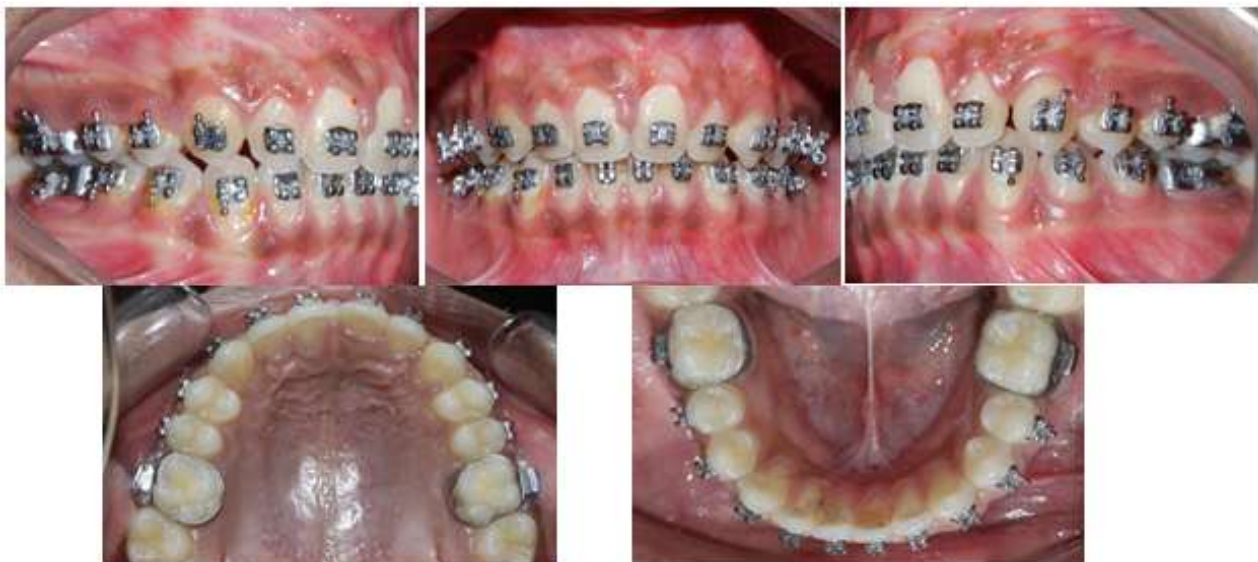

Fig. 8: Mid- treatment Intra oral Photographs

Results

After 12 months of active treatment, impacted right central incisor was successfully bring in proper position and normal functional occlusion was established (Fig. 7-9). The repositioned incisor had slightly irregular gingival contour. The mid-treatment radiograph showed no root resorption or alveolar bone loss. Regarding esthetic factors, patient was satisfied with the results.

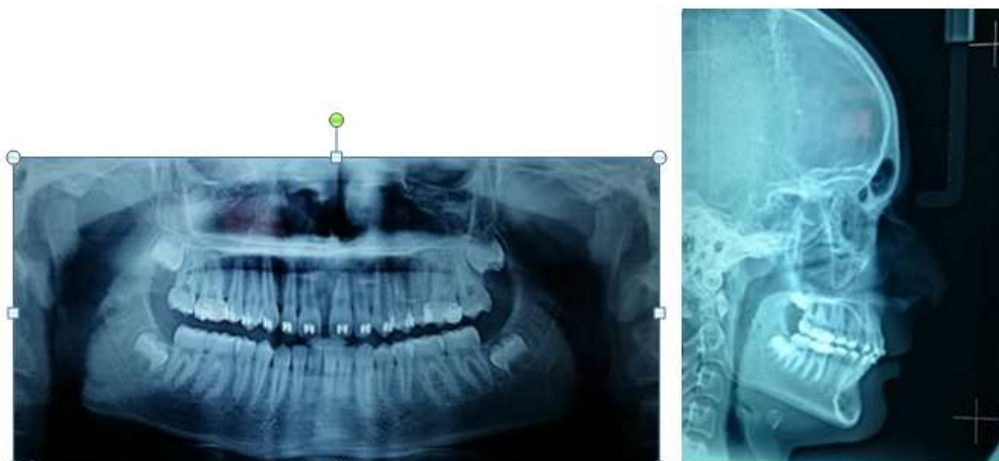


Fig. 9: Mid treatment Radiographs

Multidisciplinary treatment plan was planned: surgical removal of supernumerary teeth followed by orthodontic correction of the unerupted permanent maxillary left central incisor.

Treatment Objectives

1. Create the space for impacted central incisor
2. Orthodontic traction of impacted tooth
3. Establish an acceptable functional occlusion.

Treatment Options

The following are three possible treatment options.

1. Creation of space for impacted tooth, surgical crown exposure and removal of odontoma, and orthodontic traction of the impacted central incisor
2. Extraction of the impacted central incisor and temporary restoration with removable prosthetic denture, followed by a permanent restoration with bridge or an implant when growth ceases
3. Extraction of the impacted central incisor and closure of the space, converting the lateral incisor into the central incisor with subsequent prosthetic restoration.

After a thorough discussion of the various treatment with the patient's parents, we decided to approach the first treatment option with patient's and his parent's consent.

Treatment Plan

The treatment was planned in three steps.

1. Create the space for impacted left central incisor
2. Surgical exposure of impacted central incisor and removal of odontoma
3. Traction of maxillary right central incisor, with special attention to the gingival recession.

Treatment Progress

Banding and bonding of the maxillary arch was done with the 0.022 X0.028" MBT bracket system. The initial alignment was performed with a 0.016-inch Ni-Ti wire, followed by a 0.016-inch stainless steel wire. The maxillary teeth were consolidated in the right and left quadrant along with the use of a NiTi open coil spring to create space for the incisors. The patient was referred to the oral surgeon for exposure of the impacted incisor. The surgeon followed the closed eruption technique and raised a wide mucoperiosteal flap (Fig. 5).

Discussion

Odontomes are relatively common odontogenic lesions which are generally asymptomatic and are diagnosed mostly in the second decade of life. The most common site for the presence of odontomes are in the anterior part of maxilla either between the roots the erupted teeth or ver the crown of the unerupted teeth leading to delayed eruption of the teeth or its impaction. An anomaly in the eruption of anterior teeth can affect facial esthetics and may cause psychological problems. Several techniques have been developed as a choice of treatment for this scenario. The

successful management of theodontome and impacted central incisor is often a difficult task and enquires the joint expertise. It is important that orthodontist and oral surgeon together prepare a full proof treatment plan based on scientific rationale. Several reports have indicated an impacted tooth can be brought into proper alignment in the dental arch. The following factors are used to determine whether successful alignment of an impacted tooth can take place: (1) the position and direction of the impacted tooth, (2) the degree of root completion, (3) the degree of dilacerations, and (4) the presence of space for the impacted tooth.^{3,11-15} Orthodontic and surgical intervention should not be delayed to avoid unnecessary difficulties in aligning the tooth in the arch.¹⁶ Various surgical techniques have been described for exposing impacted teeth before orthodontic tooth movement.¹⁷ Two of the most commonly used surgical exposure techniques for labial impacted teeth are: the window approach and a technique which exposes only 4–5 mm of the most superficial portion of the labial aspect of the cusp tip while maintaining 2–3 mm of keratinized tissues.^{18,19} In this case, the available space for tooth alignment was sufficient and the tooth was in a favourable position. The tooth was brought into right anatomical position in the dental arch. If the impacted tooth is diagnosed with its root completely formed or if present in an unfavorable position, combination of surgical and orthodontic treatment has to be carried out.

Conclusion

The management of an odontome depends on its location, number and its relation to the adjacent tooth. The treatment of an unerupted maxillary central incisor tooth will depend on its state, position, and presence of enough space in the dental arch. If eruption is delayed, the permanent tooth should be exposed because it is important to allow the tooth to erupt into correct position as soon as possible. Impaction of maxillary permanent incisors is not a frequent case in dental practice, but its treatment is challenging because of the importance of these teeth in facial esthetics.

Conflict of Interest: None.

References

1. Brin I, Zilberman Y, Azaz B. The unerupted maxillary central incisor: Review of its etiology and treatment. *ASDC J Dent Child* 1982;49(5):352-6.
2. Zilberman Y, Malron M, Shteyer A. Assessment of 100 children in Jerusalem with supernumerary teeth in the premaxillary region. *ASDC J Dent Child* 1992;59(1):44-7.
3. MacPhee CG. The incidence of erupted supernumerary teeth in consecutive series of 4000 school children. *Br Dent J* 1935; 58:59–60.
4. Grover PS, Lorton L. The incidence of unerupted permanent teeth and related clinical cases. *Oral Surg Oral Med Oral Pathol* 1985;59(4):420-5.
5. Brin I, Zilberman Y, Azaz B. The unerupted maxillary central incisor: Review of its etiology and treatment. *ASDC J Dent Child* 1982;49(5):352-6.
6. Zilberman Y, Malron M, Shteyer A. Assessment of 100 children in Jerusalem with supernumerary teeth in the premaxillary region. *ASDC J Dent Child* 1992;59(1):44-7.

7. MacPhee CG. The incidence of erupted supernumerary teeth in consecutive series of 4000 school children. *Br Dent J* 1935; 58:59–60.
8. Grover PS, Lorton L. The incidence of unerupted permanent teeth and related clinical cases. *Oral Surg Oral Med Oral Pathol* 1985;59(4):420-5.
9. Brin I, Zilberman Y, Azaz B. The unerupted maxillary central incisor: Review of its etiology and treatment. *ASDC J Dent Child* 1982;49(5):352-6.
10. Zilberman Y, Malron M, Shteyer A. Assessment of 100 children in Jerusalem with supernumerary teeth in the premaxillary region. *ASDC J Dent Child* 1992;59(1):44-7.
11. MacPhee CG. The incidence of erupted supernumerary teeth in consecutive series of 4000 school children. *Br Dent J* 1935; 58:59–60.
12. Grover PS, Lorton L. The incidence of unerupted permanent teeth and related clinical cases. *Oral Surg Oral Med Oral Pathol* 1985;59(4):420-5.
13. Chaushu S, Zilberman Y, Becker A. Maxillary incisor impaction and its relationship to canine displacement. *Am J Orthod Dentofacial Orthop* 2003;124:144–50. [[PubMed](#)] [[Google Scholar](#)]
14. Becker A. Orthodontic treatment of impacted teeth. 3rd ed. West Sussex: John Wiley & Sons; 2012. Maxillary Central Incisors; pp. 70–91.
15. Brin I, Zilberman Y, Azaz B. The unerupted maxillary central incisor: Review of its etiology and treatment. *ASDC J Dent Child* 1982;49(5):352-6.
16. Zilberman Y, Malron M, Shteyer A. Assessment of 100 children in Jerusalem with supernumerary teeth in the premaxillary region. *ASDC J Dent Child* 1992;59(1):44-7.
17. MacPhee CG. The incidence of erupted supernumerary teeth in consecutive series of 4000 school children. *Br Dent J* 1935;58:59–60.
18. Grover PS, Lorton L. The incidence of unerupted permanent teeth and related clinical cases. *Oral Surg Oral Med Oral Pathol* 1985;59(4):420-5.
19. Becker A, editor. Orthodontic treatment of impacted teeth. 3rd ed: Wiley-Blackwell; 2012.
20. Cozza P, Marino A, Laganà G. Interceptive management of eruption disturbances: case report. *J Clin Pediatr Dent* 2004;29(1):1–4
21. Huber KL, Suri L, Taneja P. Eruption disturbances of the maxillary incisors: a literature review 1. *J Clin Pediatr Dent* 2008;32(3):221–30.
22. Jones JW. A Medico-legal Review of Some Current UK Guidelines in Orthodontics: A personal View. *J Orthod* 1999;26:307–24.
23. Lin YT. Treatment of an impacted dilacerated maxillary central incisor. *Am J Orthod Dentofacial Orthop* 1999;115:406–9. [[PubMed](#)]
24. Wasserstein A, Tzur B, Brezniak N. Incomplete canine transposition and maxillary central incisor impaction a case report. *Am J Orthod Dentofacial Orthop* 1997;111:635–9. [[PubMed](#)]
25. Kolokithas G, Karakasis D. Orthodontic movement of dilacerated maxillary central incisor. *Am J Orthod* 1979;76:310. [[PubMed](#)]
26. Tanaka E, Watanabe M, Nagaoka K, Yamaguchi K, Tanne K. Orthodontic traction of an impacted maxillary central incisor. *J Clin Orthod* 2001;35:375. [[PubMed](#)]
27. Uematsu S, Uematsu T, Furusawa K, Deguchi T, Kurihara S. Orthodontic treatment of an impacted dilacerated maxillary central incisor combined with surgical exposure and apicoectomy. *Angle Orthod* 2004;74:132.
28. Kuftinec MM, Stom D. The impacted maxillary canine; II. Clinical approaches and solutions. *J Dent Child* 1955;62:325–37. [[PubMed](#)]
29. Kuftinec MM, Stom D, Shapira Y. The impacted maxillary canine; I Review of concepts. *ASDC J Dent Child* 1955;62:317–24.
30. Moss JP. An orthodontic approach to surgical problems. *Am J Orthod* 1975;63:363–90. [[PubMed](#)]
31. Levin MP, D'Amico RA. Flap design in exposing unerupted teeth. *Am J Orthod* 1974;65:419–22.

How to cite this article: Khanduri M, Manocha H, Paul M, Srivastava P. Odontome Associated with Impaction of Maxillary Central Incisor: An Orthodontic Case Report. *Indian J Orthod Dentofacial Res* 2019;5(2):