

Mandibular buccal shelf and infra zygomatic crest – A safe zone for miniscrew insertion

Snehal Pathak^{1*}, Tushar Patil², A. Mahamuni³, K. Jaju⁴, Rajlaxmi Rai⁵

^{1,5}Assistant Professor, ²HOD, ³Professor, ⁴Reader, ¹Dept. of Orthodontics and Dentofacial Orthopedics, ¹⁻⁵Shri. Yashwantrao Chavan Memorial Medical and Rural Development Foundation's Dental College and Hospital, Ahmednagar, Maharashtra, India

***Corresponding Author: Snehal Pathak**

Email: pathaksnehal38@gmail.com

Abstract

Miniscrew has brought evolution in the world of orthodontics by providing skeletal anchorage which helps to convert surgical case into non-surgical case. Various sites (commonly interradicular region) are present for miniscrew insertion. Commonest disadvantage is loosening of implant during course of treatment. Thickness of cortical bone which is a variable factor is important for bone screw stability. Mandibular buccal shelf region and infra zygomatic crest region provide adequate cortical bone thickness and are apt site for bone screw placement. The aim of the study was to analyze Mandibular buccal shelf region and infra zygomatic region and provide anatomical map to clinician for bone screw placement.

Keywords: Mandibular buccal shelf region, Infra zygomatic crest region, Skeletal anchorage, Cortical bone thickness, Bone screw.

Introduction

In orthodontic armamentarium, orthodontic anchorage screw brought about renaissance. It helps the orthodontist to overcome challenge, gain absolute anchorage and also convert borderline surgical case to non-surgical case. Various anatomical sites which are present for miniscrew insertion includes palate, infra zygomatic crest, retromolar area and buccal alveolar process of maxilla and mandible.

Numerous case reports are present which state that orthodontic anchorage screw placed in mandibular buccal shelf and infra zygomatic crest are reliable for absolute anchorage and helpful for canine retraction, en masse retraction, anterior retraction, segmented orthodontics, intrusion of posterior teeth and distalization of maxillary and mandibular arch. Advantage to place screw in Infra zygomatic crest and mandibular buccal shelf is that, they do not interfere with tooth movement.

Before evaluating miniscrew application, critical issue which is utmost important is to consider anatomical guideline for safe insertion of orthodontic anchorage screw. Thus, the objective of this review is to discuss the advantage of mandibular buccal shelf and infra zygomatic crest region over other site for the placement of miniscrew.

Discussion

Is primary stability of miniscrew dependent on cortical thickness?

Primary stability is defined as absence of mobility in the bone bed after miniscrew placement.¹ It is dependent on mechanical engagement of implant with the bone socket. Quality and quantity of bone, implant design and site where implants are placed is also dependent on primary stability. Bone quality is not defined clearly in the literature. In relation to orthodontic screw, some authors state that cortical bone thickness is referred to bone quality.² Markezanet al.² concluded in meta-analysis that there is positive correlation between cortical bone thickness and primary stability. From clinical point of view, orthodontist

must be aware that thin cortical bone might generate poor primary stability of orthodontic anchorage screw. Mandibular buccal shelf has greater cortical thickness as compared to another site present on the mandible. Thus, placement in mandibular buccal shelf will provide greater primary stability and implant success.

Why to consider mandibular buccal shelf?

Hitherto, cortical bone thickness and bone width are important micro and macro anatomic factors when planning for placement of orthodontic anchorage screws. Mandible has greater compact cortical bone. Mandibular buccal shelf is a buccal alveolar bone of mandible. It is present from first molar region to the external oblique ridge which allows clinician to insert the orthodontic anchorage screw in an orientation parallel to the long axis of molar roots.

Mandibular buccal shelf offers an ample of bone quality and quantity for miniscrew insertion. Mandibular buccal screw lies lower and lateral to second molar region. Orthodontic bone screw can also be placed on external oblique ridge, if mandibular buccal shelf is thin and deep, which is commonly seen in Indian population.¹¹ Nucera et al.³ stated that enough cortical bone thickness in mandibular buccal shelf is present lateral to distal root of second molar, with screw insertion located 4 mm buccal to CEJ.

“Cortical bone thickness increased from anterior to posterior alveolar bone region”, stated by Hyo- Sang Park.⁴ He also states that posterior cortical bone also showed greater cortical bone thickness. Average Bone thickness at first and second molar area was 2.48 mm, 3.17 mm in Korean population. Ozdemir et al. presented mandibular cortical bone at all interradicular site from canine to second molar was thinner in hyperdivergent than normo and hypodivergent patients.

Parinyachaiphun et al.⁵ measured cortical bone thickness at two sites: 1) contact point of mandibular first / second molar; 2) mesial aspect of second molar in mandible. They also consider distance from molar root at these two sites, so

as to ensure that orthodontic anchorage screw would not be in contact with root during distalization. This was done to consider space available (half diameter of orthodontic anchorage screw plus periodontal ligament width i.e. 1.21 mm) in order to avoid contact of orthodontic anchorage screw with root of teeth. They concluded that cortical bone thickness at mesial aspect of second molar was thicker than that of first/second molar contact point site. The mesial side of mandible second molar was safe zone for placement of mandibular buccal shelf orthodontic anchorage screw, as its slope was flatter and gave more distance from molar root than first/second molar contact point site.

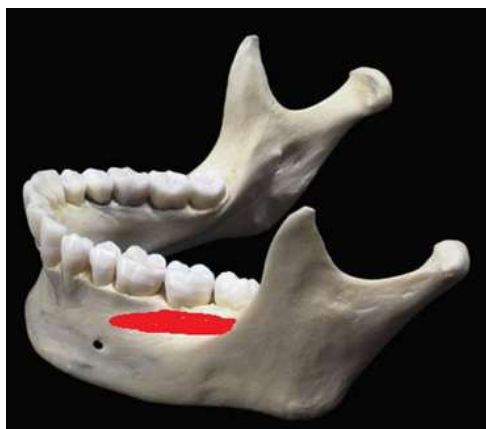


Fig. 1: Diagram representing the mandibular buccal shelf area.

Elshebiny et al.⁷ found mandibular buccal shelf region superior to other regions in the mandible. Mandibular buccal shelf region was thinner to mandibular first molar, unable to serve reliable insertion site. While in contrast, bone width at mandibular second molar showed adequate bone width and reliable insertion site (distal half buccal bone of second molar).

Chang et al.⁶ found the slope of mandibular buccal shelf becomes flatter from anterior to posterior region which makes easier placement for orthodontic anchorage screw. Degree of slopes varies among every individual. Relatively flat relationship was noted in first and second molar interproximal area. Thus, he collectively stated that mandibular buccal shelf is apt site for absolute anchorage to retract molars for class III malocclusion correction and to retract molars for non-extraction treatment of mandibular crowding. Buccal cortical bone is thicker in mandible; cortical bone thickness increases while shifting away from the alveolar crest i.e. increase distance from midsagittal plane. Overall, all studies affirm that when comparing cortical bone thickness in mandibular buccal shelf is superior than rest of bone available in mandible for placement of orthodontic anchorage screw which will provide absolute anchorage.

Why to consider infra zygomatic crest?

Anatomically, infra zygomatic crest is a pillar of cortical bone at zygomatic process of maxilla. Clinically, it is bony

ridge curvature running between alveolar and zygomatic process of maxilla. In short, it lies buccally to zygomatic process of maxilla above first permanent molar.

Lin et al.⁸ stated infra zygomatic crest lies higher and lateral to first and second molar region. They preferred bone screw placement in first and second molar region, closer to mesiobuccal root of first molar. In adults, it is above maxillary first molar while in young person it is in between second premolar and first molar.

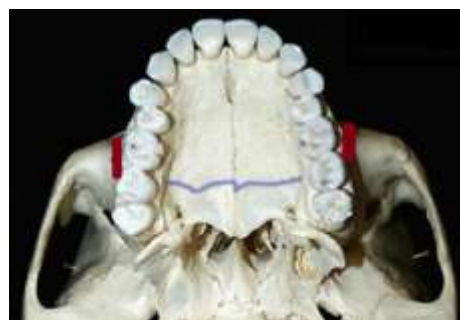

Fig. 2: Diagram representing the infra zygomatic crest region.

Infra zygomatic crest has thicker cortical bone, which provides good primary stability. This region has best bone quality in maxilla of partially edentulous patients. Buccal cortical plate and sinus floor are two cortical plates of infra zygomatic crest. Thus, anatomically it provides advantage for bicortical fixation and primary stability for orthodontic anchorage screw.

Infra-zygomatic crest a suitable site for correction in vertical dimension. It was revealed that sufficient cortical bone thickness is present for 6mm implants, if placed at specific angulation to occlusal plane. 5 to 9 mm of bone thickness is present in infra zygomatic crest when measured at 40° to 75° to occlusal plane and 15 to 17 mm above occlusal plane.

Limitations

1. Young subjects has less dense cortical bone in infra zygomatic crest and mandibular buccal shelf region
2. Ozdemir et al.⁵ stated that increased vertical skeletal pattern will has reduced cortical bone thickness and thus effect the primary stability of orthodontic anchorage screw. Miyawaki et al. reported that patients with high mandibular plane angle will have low success rate.
3. Poor oral hygiene, local inflammation around screw and type of mucosa surrounding the bone screw are the factors which affect the stability. Viwattanatipa et al.⁹ reported infra zygomatic crest has low non-keratinized tissue. Non keratinized tissue has less resistant to the effect of plaque which could be one of the reasons to affect primary stability of orthodontic anchorage screw.
4. Chang et al.¹⁰ stated, primary stability is effected because of less attached gingiva and presence of movable mucosa in infra zygomatic crest and mandibular buccal shelf region.

Conclusion

This article has highlighted that bone density and soft tissue health directly affects implant stability. Mandibular buccal shelf and infra zygomatic crest offers enough bone quality and quantity for bone screw insertion. However, the anatomy of the site varies considerably between individuals.

Conflict of Interest: None.

References

- Javed F, Romanos GE. The role of primary stability for successful immediate loading of dental implants. A literature review. *J Dent* 2010;38(8):612-20.
- Marquezan M, Mattos CT, Sant'Anna EF, de Souza MM, Maia LC. Does cortical thickness influence the primary stability of miniscrews?: A systematic review and meta-analysis. *Angle Orthodontist* 2014;84(6):1093-103.
- Nucera R, Lo Giudice A, Bellocchio AM, Spinuzza P, Caprioglio A, Perillo L et al, Bone and cortical bone thickness of mandibular buccal shelf for mini-screw insertion in adults. *Angle Orthodontist* 2017;87(5):745-51.
- Park HS. An anatomical study using CT images for the implantation of micro-implants. 2002;32(6):435-41.
- Parinyachaiphun S, Petdachai S, Chuenchompoonut V. Considerations for placement of mandibular buccal shelf orthodontic anchoring screw in Class III hyperdivergent and normodivergent subjects—A cone beam computed tomography study. *Orthodontic Waves* 2018;77(1):44-56.
- Chang C, Huang C, Roberts WE. 3D cortical bone anatomy of the mandibular buccal shelf: a CBCT study to define sites for extra-alveolar bone screws to treat Class III malocclusion. *Int J Orthod Implantol* 2016;41:74-82.
- Elshebiny T, Palomo JM, Baumgaertel S. Anatomic assessment of the mandibular buccal shelf for miniscrew insertion in white patients. *Am J Orthod Dentofacial Orthop* 2018;153(4):505-11.
- Lin J, Roberts E. CBCT Imaging to diagnose and correct the failure of maxillary arch retraction with IZC screw anchorage. *IJOI* [Internet]. 2014;3:4-17.
- Viwattanatipa N, Thanakitcharu S, Uttraravichien A, Pitiphat W. Survival analyses of surgical miniscrews as orthodontic anchorage. *Am J Orthod Dentofacial Orthop* 2009;136(1):29-36.
- Chang C, Liu SS, Roberts WE. Primary failure rate for 1680 extra-alveolar mandibular buccal shelf mini-screws placed in movable mucosa or attached gingiva. *Angle Orthod* 2015;85(6):905-10.
- Ghosh A. Infra-zygomatic crest and buccal shelf - Orthodontic bone screws: A leap ahead of micro-implants – Clinical perspectives. *J Indian Orthod Soc* 2018;52:S127-41.

How to cite this article: Pathak S, Patil T, Mahamuni A, Jaju K, Rai R. Mandibular buccal shelf and infra zygomatic crest – A safe zone for miniscrew insertion. *Indian J Orthod Dentofacial Res* 2019;5(2):60-62.