

Sexual dimorphism of hyoid bone morphology and position from third cervical vertebrae

Vishal Patel^{1,*}, Neeral Barthunia², Sandeep Singh Bhatia³, Hamendra Singh Hada⁴, Mayur Savaliya⁵

^{1,4,5}Post Graduate Student, ²Professor and HOD, ³Reader, ¹⁻⁵Dept. of Orthodontics and Dentofacial Orthopedics, Daswani Dental College and Research Center, Kota, Rajasthan, India

***Corresponding Author: Vishal Patel**

Email: vishalpatel_0407@yahoo.co.in

Abstract

Introduction: This study correlates hyoid bone morphology and position to third cervical vertebrae (C₃) in males and females using lateral cephalograms.

Material and Methods: lateral cephalograms were taken of 300 subjects, 150 male age 11-16 years and 150 female age 10-14 years. Linear measurements were taken from most antero-inferior point of third cervical vertebrae (C₃) to most anterior point of hyoid bone, hyoid bone length and width.

Result: These parameters revealed linear measurements consistently larger length, width & distance from C₃ (p=0.002, p=0.013 & p<0.0001) in males than in females (p=0.583, p=0.346, p<0.0001) respectively.

Conclusion: Statistically significant difference where noticed and linear measurements were consistently larger in male than in female. The hyoid bone was positioned more inferiorly and anteriorly and was more prominent in male than in female as age progressed.

Keywords: Hyoid bone, Third cervical vertebrae (C₃), Lateral cephalograph.

Introduction

Orthodontics is the field of dentistry which includes the study of growth and development of the dentofacial complex particularly, and the growth and development of the body generally. Overall growth and development should be recognized as one of the most important factors in orthodontics and dentofacial orthopaedics because it has considerable influence in the diagnosis, treatment plan and eventual outcome of orthodontic treatment. Hereditary, functional, environmental, sexual, nutritional and metabolic factors influence normal growth and development. The proportional effects of these factors are not easily determined, but the patient should be evaluated based on these influences.

The hyoid bone is an interesting avenue for consideration in the assessment of skeletal maturation. The bone lies between the base of the mandible and third cervical vertebrae. It is made up of six ossification centres, two for the hyoid body and one for each cornu, with subsequent synchondroses of cartilaginous joints followed by bony fusions.¹

Age and gender related morphological variations of hyoid bone have been the focuses for many searches in forensic science and legal medicine. Some studies particularly investigated on the age of unilateral and bilateral fusion of the greater cornua (GC) and the body of the hyoid in females and males, as fused hyoid bone is more likely to fracture during manual strangulation skeletal remains. Many of these studies included subjects between the third to seventh decade of life and therefore, there is insufficient information on the maturation of hyoid bone in adolescents.²⁻⁵

The hyoid bone is the bony origin of the root of the tongue and the site of insertion of the muscles of the hyoid biodynamic system (which regulates mastication, deglutition and phonation), while its horns delimit the

laryngeal part of the pharynx within which the superior opening of the larynx is included. Furmanik, Szcypinska & Biegaz (1976) showed that the dimensions of the middle part of the laryngeal cavity are closely related to the span of the greater horns of the hyoid bone.⁶

The hyoid bone is the only bone in the body that is not articulated with other skeletal bones. Orbans⁷ and many others say that the hyoid bone develops from the second and third brachial arches. The posterior portion of the tongue also develops from these two arches. Bosma⁸ believes that the hyoid may be essential in early life in keeping the pharynx air passage open.

In the literature, it has been shown that changes in mandibular position are related to hyoid bone changes and that the hyoid position adapts to anterior-posterior changes in head posture. Furthermore, studies on the relationship between the hyoid and the facial skeleton and cervical column have indicated that the hyoid-cervical relationship is more stable than the relationship of the hyoid to the skull and mandible. Consequently, studies examining different malocclusions can reveal the role of the hyoid bone in the dentofacial system and the response of mandibular development to these malocclusions.

Materials and Methods

Source of the data

The study is set up in Daswani Dental College & Research Centre, Ranpur, Kota. This study will include 300 untreated young male and female of Hadoti population visiting the Department of Orthodontics And Dentofacial Orthopaedics will be included in the study as per the inclusion and exclusion criteria.

Total of 150 male and 150 females falling in the age group of 11-16 years old and 10-14 years old were taken respectively.

1. Each Patient underwent lateral cephalogram radiographs.
2. Lateral Cephalogram were taken on Planmeca Proline 60Kvp 5ma with exposure time of 14 sec using digital sensor.
3. Distance from X-ray source to the subject's mid sagittal plane was fixed at 6 feet. Radiograph was taken with the FH plane parallel to floor with the subject being positioned in a cephalostat comfortably.

Patient selection criteria

1. The subjects were all from Hadoti region
2. Well-nourished and free of any known systemic disease.
3. None underwent neither previous orthodontic treatment nor extraction of any permanent teeth.
4. Normal growth and development.
5. No previous history of trauma or injury to the face regions.
6. The patients and parental consent was taken before taking radiographs.

Hyoid bone is assessed by linear measurements: (Fig 1)

1. Length of hyoid bone.
2. Width of hyoid bone.
3. Distance of hyoid bone from antero-inferior point of C3 to most anterior point of hyoid bone.

Calibration devices

1. Lateral Cephalogram.
2. 0.35 mm diameter lead pencil and metal scale.
3. Tracing board.

Results

Correlation of Hyoid Bone Length, Hyoid Bone Width and Distance from C3 with Age in males

In males, age group 11-16 years were taken. Hyoid bone length, width and distance from C₃ showed significant changes as the age progressed (table 1).

Table 1: Correlation of hyoid bone length, hyoid bone width and distance from C3 with age in males.

	Mean	Std. Deviation	N	r value	P value
Age	13.9329	1.55817	150		
Hyoid Bone Length	10.8600	1.36116	150	0.253	0.002*
Age	13.9329	1.55817	150		
Hyoid Bone Width	3.3400	1.16337	150	0.202	0.013*
Age	13.9329	1.55817	150		
Distance From C3	35.3933	3.67085	150	0.720	<0.0001*

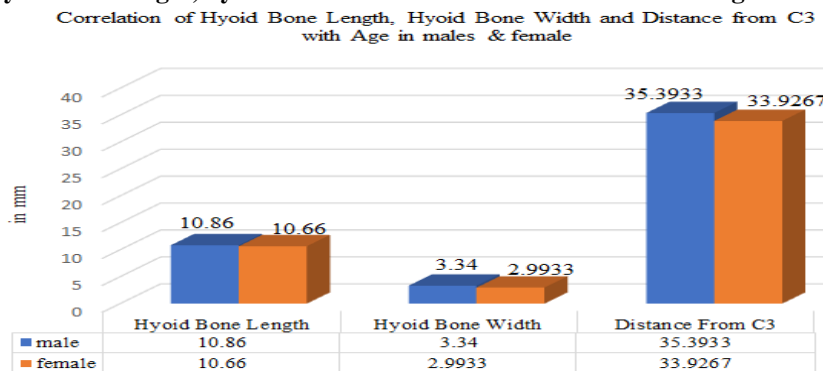
Correlation of hyoid bone length, hyoid bone width and distance from C3 with age in males

In females, age group 10-14 years were taken. Hyoid bone length, width showed insignificant readings, while distance from C₃ showed significant changes as the age progressed (table 2).

Table 2: Correlation of hyoid bone length, hyoid bone width and distance from C3 with age in females

	Mean	Std. Deviation	N	r Value	P value
Age	12.6733	1.33360	150		
Hyoid Bone Length	10.6600	0.81784	150	0.045	0.583
Age	12.6733	1.33360	150		
Hyoid Bone Width	2.9933	0.49827	150	0.078	0.346
Age	12.6733	1.33360	150		
Distance From C3	33.9267	3.07642	150	0.503	<0.0001*

Chart 1: Correlation of hyoid bone length, hyoid bone width and distance from C3 with age in male & females



These parameters revealed linear measurements consistently larger length, width & distance from C₃ (p=0.002, p=0.013 & p<0.0001) in males then in females (p=0.583, p=0.346, p<0.0001) respectively.

Discussion

In the early stages of life, the hyoid bone is placed at the inferior edge of mandibular border, but with the aging process, it gradually descends and eventually is fixed next to the fourth cervical vertebra (C4). The hyoid bone is unique in not having joints with any other bone and floating in connection with ligaments and muscles. Thus, the position of hyoid bone differs as a result of any changes in the body gesture, head position and other physiological states. In addition, the hyoid bone moves in response to mouth's different functions such as respiration and ingestion. Extensive research has been conducted in order to identify the position of the hyoid bone in various dentofacial patterns. The studies have shown that changes in the position of the mandible are related to those in the hyoid bone and the position of hyoid bone adjusts to antero-posterior changes in the head posture.^{9,10} In contrast to the variation in its anteroposterior position is its stability superoinferiorly. Both in the growing individual and in the group it maintains a position at a level between the bottom of the third and top of the fourth cervical vertebrae.

In the present study it has been shown that the hyoid bone was placed anterior in males compared to females for all subjects with significant ($p < 0.0001$). This is in agreement with the result of the study by Sahin Saglam¹¹ which, concluded that the hyoid bone position is superior and posterior in females ($p < 0.0001$).

In a study Micheal Stephovich¹² developed a technique for measuring the hyoid bone in three position, he also studied the position of the hyoid bone to the cervical vertebrae. It was found that the hyoid plane, when extended backward, usually passed through the body of the third cervical vertebrae. Therefore in this study the third cervical vertebrae was taken as a reference point.

In the current investigation the distance from most antero-inferior point of the third cervical vertebrae (C₃) to most anterior point of hyoid bone is longer in males than in females ($p < 0.0001$) which is similar to study done by Samare Mortazavi.¹³ Considering the larger size of muscles, bones, and overall skeleton in males, it is expected that the distance from hyoid bone to adjacent landmarks be more in males than females, which is in accordance with this study's findings.

On the other hands, smaller distances in females from the hyoid bone to craniofacial structures is simply due to the difference in average gender size. Overall chronological age was most closely associated with the growth changes of the hyoid bone (Table 1 & 2). Age was moderate to highly correlated with the increasing length, width and distance from C₃ of hyoid bone ($p = 0.002$, $p < 0.0001$, $p < 0.0001$ respectively). Which is similar to study done by Jocelyne Shim¹⁴ but weakest correlation was observed between age and cervical vertebrae maturation stage ($p < 0.0001$).

The normal ossification of the hyoid bone on the basis of postpartum radiographs of 10 stillborn children and radiographs of the cervical spine or the lateral neck of 86 children ranging in age from newborn to 16 years old was studied by Reed M H in 1993.¹⁵ He determined that the

body of the hyoid bone was ossified in all infants older than 4 months, so it is clear visible to be traced on lateral cephalogram.

The size and shape of the hyoid bone are highly variable, with male having larger shape than female ($p < 0.005$) but no significant relationship has been found with the age as said by Papadopoulos et al 1989² is contrary to this study where there is significant age related changes in hyoid bone size and shape in males ($p < 0.002$, $p < 0.013$) then in females ($p = 0.583$, $p = 0.346$), but similar results with sex related changes with male having larger shape than female ($p < 0.001$). Koebke et al 1979,¹⁶ said though the ossification of junction of the body and the greater cornu is one of changes which occurs with aging, it is accurate for identification of age. Miller 1998⁵ based on analysis of sexual dimorphism show that the greatest length difference are in the greater cornua. There are also significant sex differences in hyoid shape.

Shimizu Yoshinaka³ done the analysis of the length, width and position of the hyoid bone revealed significant difference in males having longer bone than those of female ($p < 0.05$) and having more anterior position in male than in female ($p < 0.05$) which is similar to this study. Growth changes in hyoid bone in cone-beam computed tomography (CBCT) with conventional skeletal maturation methods to examine their potential implications in the development of a 3D method, was compared by Jocelyne Shim¹⁴ in 2013. Peripubertal hyoid bone maturation did not yield sufficient diagnostic information for consideration in the development of a 3D skeletal maturation method.

Seher Gunduz Arslan¹⁷ investigated hyoid bone position and C₁ (atlas) morphology in males and females and analysed with the goal of identifying cephalometric norms in his retrospective study. The result of his study shown that the hyoid was positioned more inferiorly and anteriorly and was prominent in males than in females in all groups. ($p < 0.001$). Numerous previous studies have shown that orthodontic treatments impacting mandibular position can also alter the position of the hyoid, given that it is attached to the mandible via the geniohyoid, anterior digastric, and mylohyoid muscles. Graber¹⁸ evaluated the position of the hyoid in 30 children (16 males and 14 females, mean age of 6 years) after orthopedic treatment for mandibular prognathism. Graber observed that the hyoid position had shifted posteriorly and inferiorly at 3 years after treatment.

Surucu¹⁹ examined 10 individuals with skeletal Class II division I malocclusions and found that, after the activator was applied and the bite was opened, the tongue shifted posteriorly and caused constriction of the upper airway. To compensate for this constriction, patients would need to alter their normal upright head posture by extending the head/jaw. The authors reported that, as a result of these changes, the mandible moved into a more anterior position, while the hyoid shifted anteriorly depending on the degree of head extension. It has been reported that the hyoid moves posteriorly and inferiorly in mandibular setback surgeries.²⁰ This subsequently results in the base of the tongue shifting

posteriorly and inferiorly, resulting in constriction of the upper airway and forcing the patient to further extend the head position to lengthen the upper airway. Posterior movement of the mandible can cause relaxation of the suprahyoid musculature, which may instigate balance disorders in the head and neck muscles and oropharyngeal complex. It has been postulated that if this relaxation continues for an extended period, it can alter the position of the hyoid as well as the length of the suprahyoid muscle, causing skeletal relapse.²¹

The hyoid bones were extensively polymorphic, although certain metric trends could be related to shape and sexual dimorphism Pollanen et al., 1997;²² Miller et al., 1998.⁵ Previous researchers noted the differences in the sizes of the male and female hyoid bones Hilloowala, 1975;²³ Reed, 1993.¹⁵ The width, length and height of the hyoid bone were significantly greater in males than in females.

Conclusion

Assessment of maturation status of a subject is important in the field of orthodontics especially when growth modification therapy is needed. Conventional method of growth assessment like hand wrist radiographs has been questioned because of additional radiographic exposure.

Statistically significant dimensional difference between male and female hyoid bone were noticed. Female hyoid bone on an average smaller than male hyoid bone. It has been seen that as cervical vertebrae undergo maturation with the advancing age, the hyoid bone also seems to be placed anteriorly. It has been concluded from the above data that the distance from C₃ vertebrae to the anterior most point on the hyoid bone can also be used for the assessment of growth status of an individual.

Conflict of Interest: None.

References

- O'Halloran RL, Lundy JK. Age and ossification of the hyoid bone: forensic implications. *J Forensic Sci* 1987;32(6):1655-1659.
- Papadopoulos, N., G. Lykaki - Anastopoulou, E.L. Alvanidou the shape and size of the human hyoid bone and a proposal for an alternative classification. *J Anat* 1989;163:249-260.
- Yoshinaka shimizu, Hiroyasu Kanetaka, Yeon-Hwan Kim, Keisuke Okayama, Mitushiro Kano, Massayoshi Kikuhi. Age-related morphology changes in the human hyoid bone. *Cells Tissues Organs* 2005;180:185-192.
- Carmine A. Durzo and Allan G. Brodie. Growth Behavior of the Hyoid Bone. *Angle Orthodontist* 1962;32(3):193-204.
- Miller KW, Walker PL, O'Halloran RL. Age and sex-related variation in hyoid bone morphology. *J Forensic Sci* 1998;43(6):1138-1143.
- Furmanik, F., Szczepinska, J. & Beegaz, R. Relation of some dimensions of the middle part of the laryngeal cavity to span of the greater horns of the hyoid bone. *Folia morphologica* 1976;35:123-131.
- Orban, B. J.: Oral Histology and Embryology, St. Louis, 1957, the C. V. Mosby Company, chap. 8, p. 205.
- Bosmn, J. F.: Maturation of Function of the Oral and Pharyngeal Region, *Am J Orthod Dentofacial Orthop* 1963;49: 94-104.
- Sahoo NK, Jayan B, Ramakrishna N, Chopra SS, Kochar G. Evaluation of upper airway dimensional changes and hyoid position following mandibular advancement in patients with skeletal class II malocclusion. *J Craniofac Surg* 2012;23:623-627
- Güven O, Saraçoğlu U. Changes in pharyngeal airway space and hyoid bone positions after body osteotomies and sagittal split ramus osteotomies. *J Craniofac Surg* 2005;16:23-30.
- Sahin Saglam AM, Uydaz NE. Relationship between head posture and hyoid position in adult females and males. *J Craniomaxillofac Surg* 2006;34:85-92.
- Micheal Stephovich. A cephalometric positional study of the hyoid bone. *Am J Orthod Dentofacial Orthop* 1965;51:882-900.
- Mortazavi S, Asghari-Moghaddam H, Dehghani M, Aboutorabzade M, Yaloodbardan B, Tohidi E, Hoseini-Zarch SH. Hyoid bone position in different facial skeletal patterns. *J Clin Exp Dent* 2018;10(4):e346-351.
- Jocelyne Shim, Giseon Heo, Manuel O. Lagravere. Correlation between three-dimensional morphological changes of the hyoid bone with other skeletal maturation methods in Adolescents. *Oral Surg Oral Med Oral Pathol Oral Radiol* 2013;116:511-517.
- Reed M H. Ossification of the hyoid bone during childhood. *Can Assoc Radiol J* 1993;44(4):273-276.
- Koebke J, Saternus KS. Morphology of the adult human hyoid bone. *Z Rechtsmed.* 1979;84:7-18.
- Seher Gündüz Arslan, Neval Dildeş, and Jalen Devecioglu Kama. Cephalometric Investigation of First Cervical Vertebrae Morphology and Hyoid Position in Young Adults with Different Sagittal Skeletal Patterns. *The Scientific World Journa* 2014;1(59):784-788.
- L. W. Graber, Hyoid changes following orthopedic treatment of mandibular prognathism, *Angle Orthodontist* 1978;48(1):33-38.
- R. Surucu, S. Aras, and A. Soytarhan, "Cephalometric evaluation of the immediate changes in cervical structures after the application of the activator," *Turkish J Orthodontics* 1990;3(2):44-49.
- N. Eggensperger, W. Smolka, and T. Iizuka. Long-term changes of hyoid bone position and pharyngeal airway size following mandibular setback by sagittal split ramus osteotomy, *J Cranio-Maxillofacial Surg* 2005;33(2):111-117.
- Gale, P. V. J. Kilpelainen, and M. T. Laine-Alava. Hyoid bone position after surgical mandibular advancement. *European Journal of Orthodontics* 2001;23(6):695-701.
- Pollanen, M.S., D.H. Ubelaker (1997) Forensic significance of the polymorphism of hyoid bone shape. *J Forensic Sci* 42:890-892.
- Hilloowala, R.A. (1975) Comparative anatomical study of the hyoid apparatus in selected primates. *Am J Anat* 142:367-384.

How to cite this article: Patel V, Barthunia N, Bhatia SS, Hada HS, Savaliya M, Sexual dimorphism of hyoid bone morphology and position from third cervical vertebrae. *Indian J Orthod Dentofacial Res* 2019;5(1):24-27