

Comparison of smile esthetics after extraction and non-extraction orthodontic treatment

Veerendra Prasad^{1*}, Pradeep Tandon², Gulshan Kumar Singh³, Amit Nagar⁴, Rana Pratap Maurya⁵

¹Associate Professor, ²Professor and HOD, ^{3,4}Professor, ⁵Reader, ¹Dept. of Plastic Surgery, ²Dept. of Orthodontics & Dentofacial Orthopaedics, King George's Medical University (Erstwhile K.G.M.C.) Lucknow, Uttar Pradesh, India

***Corresponding Author:**

Email: veerendrapd@yahoo.co.in

Abstract

Introduction: Smile esthetics is prime objective of modern orthodontic treatment. Effect of tooth extraction on esthetics is controversial. Thus, the aim of this study was to evaluate and compare the smile esthetics after extraction and non-extraction orthodontic treatment.

Materials and Methods: Frontal smiling photographs of 80 orthodontically treated subjects with age range of 18-25 years (mean age 20.16 years) were taken and divided into two groups each having 40 subjects. Group-I were treated with extraction of all first premolars and Group-II were treated without extraction of teeth. Both groups were further divided into two subgroups: Subgroup-A for male and Subgroup-B for female having 20 patients in each subgroup. Smile esthetics and esthetic scores were assessed on frontal photographs by using eight transverse and three vertical linear measurements, seven derived ratios and four other variables. The data so obtained were subjected to statistical analysis.

Results: Statistically non-significant difference for all seven ratios were found between Group I and Group II. On intergroup comparison of other variables, only visible maxillary first molar variable showed statistically significant differences ($p < 0.05$) in both males and females. For esthetic score, statistically non-significant difference was found for both males and female in both the groups. Lay persons rated higher mean values of esthetic score for all subgroups except subgroup IIa. On comparison of esthetic score rated by professionals and lay persons showed significant difference for only subgroup Ib ($p < 0.01$). No significant correlation of esthetic score with all seven ratios was found in the males and females of Group I and Group II.

Conclusion: No difference was found between smile esthetics of extraction and non-extraction subjects. Thus, decision regarding extraction of teeth in orthodontic patients should not be solely based on smile esthetics but other factors which determine extraction should be considered.

Keywords: Extraction orthodontic treatment, Non-extraction orthodontic treatment, Frontal facial photographs, Smile esthetics, Esthetic score.

Introduction

Smile plays a significant role in facial attractiveness and social interactions. It has become a main reason that patients seek orthodontic treatment. A proper alignment of teeth with good occlusion is thought to be a fundamental component of an attractive smile.¹ Therefore, the influence of orthodontic treatment on dental characteristics and smile aesthetics is of great concern. Stallards² stated that beauty being interrelated with the function of the lip and teeth was considered by comparing the smiles of subjects with normal occlusion with the smiles of orthodontically treated subjects. Angle popularized the belief that placing the teeth in normal occlusion would yield the ideal esthetic result. However, orthodontists soon noted that facial features of patient with corrected occlusion may not necessarily be beautiful. Even a well-treated orthodontic case, in which the plaster model fulfils every criterion of successful treatment, may not produce an esthetic smile. Mathews revealed that anatomy of the smile was an integral part of dentistry.³ To create a harmonious smile the dentist must maintain or create the normal curvatures of the lips, proper exposure of the red zone of lips, an undistorted philtrum and undisturbed nasolabial grooves.³

In orthodontics, extraction of teeth is a common treatment modality for correction of malocclusion. A debate arises concerning outcome of smile esthetics after extraction and non-extraction orthodontic therapy. It was presumed that extraction results in constricted dental arches, which in turn result in increased buccal corridors, thus making the smile less aesthetic.⁴ Hulsey⁵ compared the smile of untreated subjects having normal occlusion with subjects who had undergone orthodontic treatment and found that orthodontically treated subjects had significantly poorer smile scores than the subjects with normal occlusion. Johnson and Smith,⁶ compared smile esthetics after orthodontic treatment with and without extraction of all first premolar and found no significant difference in smile esthetics, esthetic scores and visible dentition during a smile. In literature, very few studies have been reported on outcome of smile esthetics after extraction and non-extraction orthodontic treatment. Thus, purpose of this study was to compare smile aesthetics after orthodontic treatment in subjects with and without extraction teeth.

Material and Methods

Material: This study was conducted on frontal smiling photographs of 80 orthodontically treated patients in the age group of 18–25 years with mean age of 20.16 years.

The subjects were divided into two groups. Group-I consisted of 40 patients, treated with extraction of all first premolars and Group-II also comprised of 40 patients, treated without extraction of teeth. Both groups were further divided into two subgroups Subgroup-A for male and Subgroup-B for female having 20 patients in each subgroup. All the treated subjects both extraction and non-extraction were collected from Department of Orthodontics and Dentofacial Orthopaedics, U.P. King George's University of Dental Sciences, Lucknow, who had received orthodontic treatment with standard edgewise 0.022"x 0.028" slot appliances and had been debonded recently. The criteria for sample selection were: 1. Patients with good occlusion, pleasing faces with class I molar and canine relationship were included.² Patients with obvious facial asymmetry, excessive gingival smile line, visible space, increased overjet and overbite, open bite and mid line discrepancy after treatment were excluded.

Method: Smiling frontal photograph of all the subjects were taken during a pleasing natural smile with a natural head posture and interpupillary line parallel to the floor. All photographs were taken by the same operator at a constant object to lens distance by using a digital camera (DSCW5 Sony, 5.1 mega-pixels, 3× optical zoom, 6× digital zoom Carl Zeiss lens). To standardize the photographs, camera was positioned on a stand at the same distance for each photograph, so that the line of the central lens to the eye was parallel to the horizontal plane and the lens was centered between both eyes. To avoid the shadow or darkness on face and ensure equal lighting on both sides of the face, two electronic flashes were placed on the stands at an angle of 45 degrees slightly above the patient.

Five frontal smiling photographs of each patient were taken and a single 'most pleasing smile' was selected. The selected photographs were cropped off to a size of 5 × 3.5 inches using Adobe Photoshop (version 9.0) and were developed on a Kodak glossy photo paper. The smile esthetic score was evaluated by a panel of two orthodontists, two general dentists, one plastic surgeon, one cosmetologist, and six lay persons. To rate the attractiveness of the smile, a smile rating chart were given a to all panel members and were asked to rate the attractiveness on the basis of a five-point scale with 5 as excellent 4 as very good 3 as good 2 as fair, and 1 as poor. Each panel member made their evaluation separately, without any knowledge of the subject's identity. The smile scores obtained for each subject were averaged and a mean were determined.

Photographic points used in present study are shown in Fig. 1 Linear measurements in the transverse and vertical planes are shown in Fig. 2-4. Various ratios derived from the above photographic points and measurements are shown in Fig. 5 and 6. Although the photographs were taken in a highly standardized manner and were developed identically, the

measurements of the photograph made may not highly precise. Therefore, the data reported and comparisons made between the subjects, for measurements, were limited to the seven mentioned ratios, which were not affected by the difference in magnification between the photographs.

Other variables used in the study were as follows:

The presence or absence of visible any portion of maxillary first molars during smiling was assigned as: absent = 0 or present = 1.

Presence or absence of visible any mandibular tooth during smile was assigned as: presence =1 or absence = 0.

Presence or absence of any visible maxillary marginal gingiva during smile was assigned as: presence =1 or absence = 0.

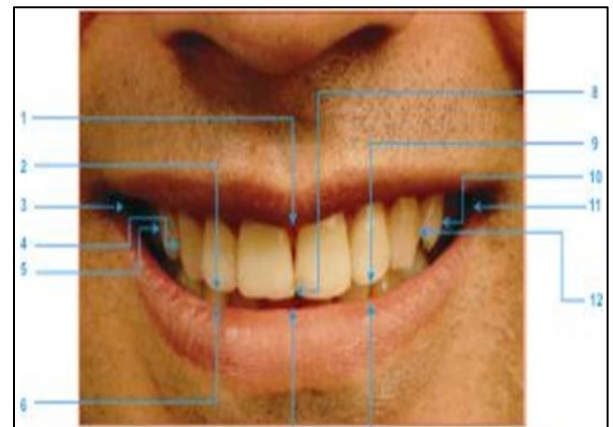


Fig. 1: Photographic points

1- The most inferior point on the inferior curvature of upper lip (C Low), 2- Point on incisal edge of upper right lateral incisor where the long axis of tooth intersects the incisal edge (RL), 3- The innermost corner of the lip on right side (Rch), 4- Point on most lateral surface of upper canine of right side (RCus), 5- Point on lateral surface of upper premolar of right side (R PM), 6- Point on upper curvature of lower lip directly inferior to point RL (R Lab), 7- The midmost point on upper curvature of lower lip directly inferior to point C (C lab), 8- The mid most and incisal-most point between the incisal edges of the upper central incisors (C), 9- Point on incisal edge of left lateral incisor where the long axis of tooth intersects the incisal edge (LL), 10- Point on lateral surface of upper premolar of left side (L PM), 11- The inner most corner of the lip on left side (LCh), 12- Point on most lateral surface of upper canine of left side (LCus), 13- Point on upper curvature of lower lip directly inferior to point LL (L Lab).

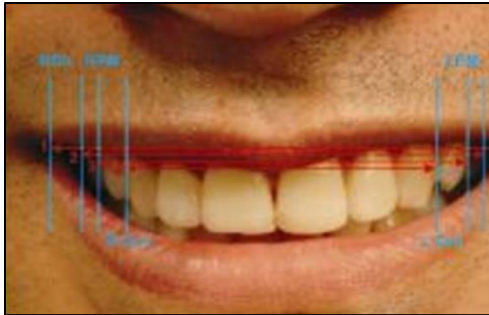


Fig. 2: Linear measurements in transverse plane

1. Smile width or Intercommissure width - Distance between most medial points on the lips at the angle of the mouth (left to right cheilion, RCh to LCh). 2. Visible dentition width- Distance between the most lateral left and right buccal points on maxillary dentition. 3. Interpremolar distance- Distance between the most distal visible points on the first premolar (in case of extraction second premolars) (RPM to LPM). 4. Maxillary intercanine width- Distance between the most distal visible points on the canines (R Cus to L Cus).

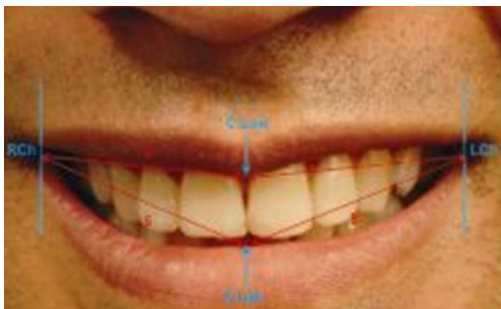


Fig. 3: Linear measurements in transverse plane

5. Distance between inner most corner of right side of lip to the most inferior point on the inferior curvature of the upper lip (RCh to C Low), 6. Distance between the inner most corner of right side of lip to the mid most point on the upper curvature of the lower lip, directly inferior to point C (RCh to C Lab), 7. Distance between the inner most corner of left side of lip to the inferior point on the inferior curvature of the upper lip (LCh to C Low), 8. Distance between the inner most corner of left side of lip to the mid most point on the upper curvature of the lower lip, directly inferior to point C (LCh to C Lab).

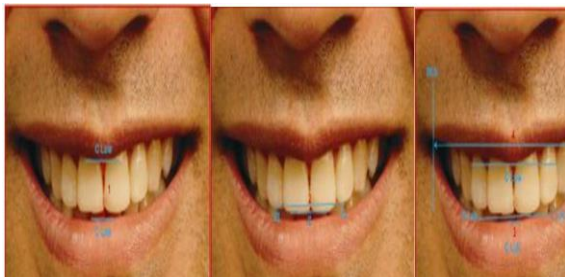

Fig. 4: Linear measurements in vertical plane plane

1. Smile height-Distance from the most inferior point on the upper lip between maxillary central incisors to

the most superior point on lower lip on a perpendicular vertical line from the upper point (C Low to C Lab), 2. Length of perpendicular for the arc of the upper incisor- Perpendicular distance from straightedge through points RL and LL to point C, 3. Length of perpendicular for the arc of lower lip - Perpendicular distance from straight edge through points R Lab and L Lab to point C Lab, 4. Upper lip curvature (Positive or Negative)- A straight edge was aligned through points RCh and LCh, and point C Low was observed to determine whether or not the point was inferior or superior to the line established, as positive if corners of the smile were superior to center of upper lip, as negative if corners of smiles were below the corner of upper lip.

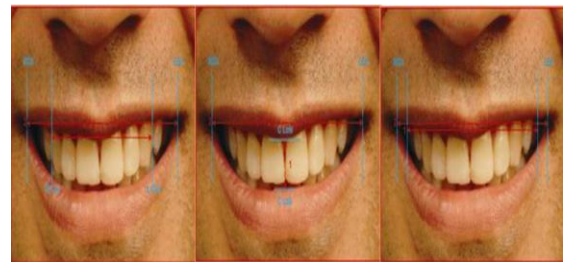


Fig. 5: Various ratios

1. Ratio 1 (Buccal corridor) = Maxillary inter canine width (R Cus to L Cus) / Smile width (RCh to LCh), 2. Ratio 2 = Maxillary smile height (C Low to C Lab) / Maxillary smile width (RCh to LCh), 3. Ratio 3 = Visible dentition width / Smile width (RCh to LCh).

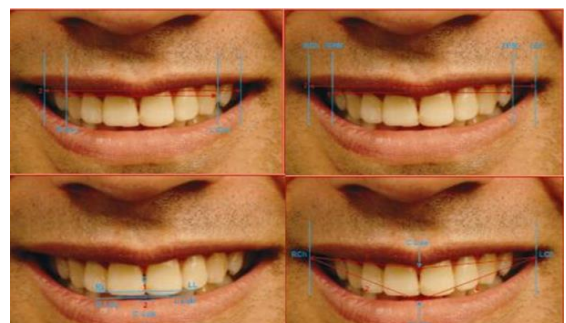


Fig. 6: Various ratios

Ratio 4 = Maxillary inter canine width (R Cus to L Cus) / Visible dentition width, Ratio 5 = Interpremolar distance (RPM to LPM) / Smile width (RCh to LCh), Ratio 6 (Smile line ratio) = Length of perpendicular for the arc of upper incisors / Length of perpendicular for the arc of lower lip, Ratio 7 (Smile symmetry ratio) = Distance from RCh to C Low+ Distance from RCh to C Lab / Distance from LCh to C Low+ Distance form LCh to C Lab

Statistical Analysis

Descriptive statistics included mean, standard deviation and standard errors were calculated for each group. To test the significance of change in groups, unpaired ‘t’ test was used. Chi square test was used to compare the distribution of discrepancies in different

groups. Karl Pearson's coefficient of correlation is used to measure the degree of linear relationship between two variables. $P < 0.05$ was considered to be a statistically significant difference. Analysis for determination of reliability for the measurements and esthetic score was done. No significant differences in the initial and second reading of variables were seen, showing a good reliability of the observation made.

Results

The Mean and SD values of transverse and vertical measurements for smile esthetics of males and females in Group I and Group II are shown in Table 1. When we compared the mean and SD values of various ratios for smile esthetics in subgroups of Group I and II [Table 2] statistically non-significant difference for all seven ratios were found. Evaluation of other variables for smile esthetics in subgroups of Group I and Group II are shown in Table 3. On intergroup comparison

[Table 4] of other variables for smile esthetics, only visible maxillary first molar variable showed statistically significant differences ($p < 0.05$) in both males and females. Table 5 showed the means and SD values of Esthetic Score which was found higher for females in both Group I and Group II. However, on intergroup comparison of Esthetic Score statistically non-significant difference was found for both males and female [Table 6]. Comparison of the mean values of the esthetic scores rated by professionals and lay persons among various groups and subgroups [Table 7] showed that lay persons rated higher mean values for all subgroups except subgroup IIa but the significant difference was found for subgroup Ib ($p < 0.01$). No significant correlation of esthetic score with all seven ratios was found in the males and females of Group I and Group II [Table 8].

Table 1: The Mean \pm SD values of linear measurements (transverse and vertical plane) in subgroup of Group I and Group II

Measurements (in mm)		Group Ia (Mean \pm SD)	Group IIa (Mean \pm SD)	Group Ib (Mean \pm SD)	Group IIb (Mean \pm SD)
Transverse plan					
1.	Smile width	87.81 \pm 5.82	87.43 \pm 5.18	89.47 \pm 4.39	89.15 \pm 4.87
2.	Visible dentition width	74.19 \pm 3.96	74.43 \pm 4.16	76.23 \pm 3.90	76.70 \pm 4.99
3.	Interpremolar distance (4-4)	67.3 \pm 3.03	67.07 \pm 4.38	72.80 \pm 3.84	73.75 \pm 5.38
4.	Maxillary intercanine width	57.75 \pm 2.36	57.14 \pm 3.42	62.50 \pm 3.34	63.85 \pm 5.14
5.	RCh to CLow	42.56 \pm 3.66	42.86 \pm 3.18	44.63 \pm 2.13	43.90 \pm 3.57
6.	RCh to Clab	46.06 \pm 4.28	45.29 \pm 3.73	47.90 \pm 2.48	47.20 \pm 3.12
7.	LCh to Clow	45.69 \pm 4.23	44.29 \pm 3.90	45.53 \pm 2.11	45.55 \pm 2.43
8.	LCh to Clab	48.19 \pm 5.24	47.43 \pm 4.20	48.70 \pm 3.14	48.90 \pm 2.73
Vertical plane					
9.	Smile height	16.69 \pm 3.08	16.57 \pm 2.94	17.20 \pm 3.52	15.80 \pm 1.80
10.	Length of perpendicular for the arc of the upper incisor	1.44 \pm 0.32	1.57 \pm 0.61	2.30 \pm 0.92	2.95 \pm 0.83
11.	Length of perpendicular for the arc of curvature for lower lip	2.06 \pm 1.15	1.92 \pm 0.53	3.30 \pm 1.25	2.40 \pm 0.91

Table 2: Intragroup comparison of Mean and SD values of various ratio in Group I and Group II

S. No.	Ratios	Group Ia (Mean \pm SD)	Group IIa (Mean \pm SD)	Group Ib (Mean \pm SD)	Group IIb (Mean \pm SD)	Ia Vs. IIa		Ib Vs. IIb	
						't'	'p'	't'	'p'
1.	Ratio1 : Maxillary intercanine width / smile width	0.6550 \pm 0.0366	0.6514 \pm 0.0615	0.6940 \pm 0.0508	0.7010 \pm 0.0306	0.14	0.9	0.72	0.45
2.	Ratio2 : Smile height / smile width	0.1850 \pm 0.036	0.1857 \pm 0.034	0.1860 \pm 0.0398	0.1750 \pm 0.024	0.04	0.99	0.78	0.45
3.	Ratio3 : Visible dentition width / smile width	0.8413 \pm 0.0429	0.8471 \pm 0.0475	0.8473 \pm 0.0337	0.8550 \pm 0.0217	0.25	0.8	0.64	0.50
4.	Ratio 4 : Maxillary intercanine width / visible dentition width	0.7638 \pm 0.0498	0.7643 \pm 0.0616	0.8127 \pm 0.041	0.8260 \pm 0.035	0.02	0.99	0.71	0.45
5.	Ratio 5 : Interpremolar distance/smile width	0.7638 \pm 0.0453	0.7643 \pm 0.070	0.8107 \pm 0.0524	0.8240 \pm 0.353	0.02	0.99	0.70	0.50
6.	Ratio 6 : Smile line ratio	0.8475 \pm 0.3564	0.9229 \pm 0.5186	0.8013 \pm 0.3706	0.7960 \pm 0.2916	0.33	0.7	0.04	0.98
7.	Ratio 7 : Smile symmetry ratio	0.9075 \pm 0.0902	0.9914 \pm 0.0963	0.9853 \pm 0.0600	0.9840 \pm 0.1035	1.74	0.15	0.04	0.98

Table 3: Evaluation of other variables in subgroups of Group I and Group II

S. N.	Other variables	Group Ia	Group IIa	Group IIa	Group IIb
1.	Upper Lip Curvature				
	Positive	75%	43%	60%	90%
	Negative	25%	57%	40%	10%
2.	Visible Maxillary 1st Molar				
	Presence	87.5%	28.6%	33.3%	0%
	Absence	12.5%	71.4%	66.7%	100%
3.	Visible Mandibular Teeth				
	Presence	87.5%	71.4%	73.3%	60%
	Absence	12.5%	28.6%	26.7%	40%
4.	Visible Maxillary Marginal Gingiva				
	Presence	62.5%	85.7%	80%	60%
	Absence	37.5%	14.3%	20%	40%

Table 4: Intergroup comparison of other variables in different Groups

	Group Ia Vs. Group IIa		Group Ib Vs. Group IIb	
	χ^2	'p'	χ^2	'p'
Upper Lip Curvature	1.50	0.22	2.57	0.11
Visible Maxillary 1 st Molar	5.04	0.024*	4.00	<0.05*
Visible Mandibular Teeth	0.56	0.45	0.47	0.49
Visible Maxillary Marginal Giviva	0.96	0.33	1.14	0.29

*‘p’ < 0.05 (Just Significant)

Table 5: Means and SD values of Esthetic Score of males and females in Group I and Group II

S. No.	Subgroup	Esthetic Score (Mean \pm SD)
1.	Group Ia (male)	2.44 \pm 0.56
2.	Group IIa (male)	2.68 \pm 0.23
3.	Group Ib (female)	2.76 \pm 0.43
4.	Group IIb (female)	2.88 \pm 0.71

Table 6: Intergroup comparison of Means of Esthetics Scores among subgroups of Group I and Group II

S. No.	Subgroup	't'	'p'
1.	Ia Vs. IIa	1.05	0.31
2.	Ib Vs. IIb	0.53	0.60

Table 7: Comparison of Means of Esthetics Scores rated by Professionals and Lay persons among subgroups of Group I and Group II

Subgroup	Professional (Mean \pm SD)	Lay Person (Mean \pm SD)	't'	'p'
Ia (males)	2.19 \pm 0.59	2.67 \pm 0.72	1.46	0.15
Ib (females)	2.49 \pm 0.59	2.90 \pm 0.763	2.88	<0.01**
IIa (males)	2.714 \pm 0.3431	2.571 \pm 0.345	0.77	0.50
IIb (females)	2.683 \pm 0.81	3.00 \pm 0.35	0.61	0.50

Table 8: Correlation of Esthetics score with different ratios in subgroups of Group I and Group II

S. No.	Ratios	Group Ia			Group IIa			Group Ib			Group IIb		
		'r'	't'	'p'	'r'	't'	'p'	'r'	't'	'p'	'r'	't'	'p'
1.	Ratio 1: Maxillary intercanine width/smile width	0.51	1.45	0.20	0.18	0.45	0.86	-0.021	0.07	0.95	-0.16	0.46	0.88
2.	Ratio 2: Smile height/smile width	0.11	0.27	0.80	0.40	0.98	0.71	-0.17	0.62	0.55	-0.29	0.86	0.78
3.	Ratio 3: Visible dentition width / smile width	0.67	2.21	0.07	0.37	0.89	0.73	-0.16	0.58	0.57	0.172	0.49	0.87
4.	Ratio 4: Maxillary intercanine width / visible dentition width	0.09	0.24	0.83	-0.03	0.07	0.98	0.18	0.66	0.52	-0.30	0.89	0.77
5.	Ratio 5: Interpremolar distance/smile width	0.65	2.10	0.08	0.26	0.60	0.81	0.08	0.29	0.78	-0.24	0.70	0.82
6.	Ratio 6: Smile line ratio	0.17	0.42	0.70	0.21	0.48	0.65	0.20	0.74	0.50	0.30	0.89	0.40
7.	Ratio 7: Smile symmetry ratio	0.16	0.40	0.70	-0.22	0.50	0.83	-0.19	0.70	0.50	-0.17	0.49	0.64

Discussion

Smile esthetics has become more important for orthodontists because orthodontic patients evaluate the outcome of treatment by their smiles and overall enhancement in their facial appearance. Although, treatment goal in orthodontics is based primarily to achieve good occlusal relationships, now greater attention is paid to enhancing dentofacial characteristics to produce optimal facial esthetics. The major challenge in orthodontics is to establish esthetics excellence and to create harmony of the components orofacial region. In orthodontics, literature contains many more studies of skeletal structure than of soft tissue structure, more studies of the profile of patients than of their frontal view, and more studies of structure in stable functional positions than during dynamic functional movements. One consequence of these biases and traditions is that there have been remarkably few investigations of the effects of orthodontic treatment on the esthetics of the smile.

Poor smile esthetics have become one of the critiques of premolar extraction treatment in the highly politicized and commercialized extraction-nonextraction debate. It has been suggested that extraction of premolars leads to constriction of dental arch resulting in decreased fullness of the dentition within the mouth during a smile.^{7,8} It is claimed that dark intraoral spaces, lateral to the buccal segments, result from this decreased dental arch width, and that these spaces are unesthetic. Some studies suggested that the arch width is not necessarily constricted in patients with tooth extraction.^{9,10} However, others reported that extraction may lead to constriction of the dental arches and reduced fullness of the dentition while smiling, resulting in an increased buccal corridor that can affect smile esthetics.^{7,8} Hence, the aim of this study was to assess smile aesthetics after orthodontic treatment in subjects with and without extraction of the four first premolars.

In the present study extraction and non-extraction groups were divided into male and female subgroups so that the smile esthetics can be evaluated separately in both, as the tooth shape, size and smile arc vary in male and female subjects. Frush and Fisher¹¹ had stated that the qualities of femininity, masculinity are important factors in the interpretation of smile. Peck et al.¹² had confirmed the smile line dimorphism between males and females and stated that at maximum smile, the upper-lip line, relative to the gingival margin of the maxillary central incisors, was positioned 1.5mm more superiorly in females than in males. The frontal view smiling photographs were used in the study because frontal smiling visualization permits the orthodontist to visualize any dental or skeletal asymmetry transversely and vertically. Sarver and Ackerman¹³ stated that frontal smile photograph either full face or close up is much better indicator of transverse dental asymmetry than any other view. According to Dustin et al.¹⁴ frontal

facial form dates back to the Egyptians, who depicted ideal facial esthetics as the “golden proportion.” In his study, only the young adult subjects were selected because this age group best describes the features of esthetic smile. Vig and Brundo¹⁵ reported that there is gradual decrease in maxillary incisor exposure for each increase in age group from under 30 to over 60. Ritter et al.¹⁶ had also reported similar findings. According to Frush and Fisher,¹⁷ “smile arc is determined by the age of the patient and decreases as the patient gets older” and age also has an effect on the architecture of a smile because, with age, the upper lip tends to conceal more of maxillary incisors, with a concomitant greater degree of mandibular incisor display.

In this study, Ratio 1 was the measure of the buccal corridor ratio, which is the space between the facial surfaces of the posterior teeth and the corners of the mouth during smiling. The results of our study showed that extraction of first premolar did not have predictable effect on buccal corridor ratio. Johnson and Smith¹⁶ in their study had also found similar findings that the maxillary intercanine width/smile width (buccal corridor ratio) did not change in extraction and non-extraction treated subjects. Kim and Gianelly¹⁸ found that constricted arch widths are not a usual outcome of extraction treatment.

This finding was contrary to Isiksal et al.¹⁹ who have argued that extraction causes arch-width reduction. Tikku et al.²⁰ have found that increased buccal corridor space causes lower esthetic score and has mild-to-moderate inverse correlation with the intercanine and intermolar width. Yang et al.²¹ concluded that the buccal corridor area ratio was not significantly different between extraction and non-extraction groups. In a meta-analysis conducted by Cheng et al.²² concluded that extraction did not significantly affect frontal smiling esthetics, in terms of both esthetic score and buccal corridor, which was similar to finding of Dai et al.²³ Prasad et al did not find statistically significant difference for ration 1 in extraction and normal subjects.²⁴ The Ratio 2 or smile height /smile width was the distances from inferior border of upper lip to superior border of lower lip/inter inner commissure width). Ackerman and Ackerman²⁵ also used same measurements to derived a ratio called smile index, which they used as a soft tissue determinant of display zone of the smile. We did not find statistically significant differences in means of ratio 2 on intra-group comparisons in male and female subjects. The Ratio 3 indicates the dental arch fullness in the buccal segments better than Ratio 1 Johnson and Smith.¹⁶ The subjects having higher ratio 3 expresses lesser buccal corridor space. We observed statistically non-significant difference in male and female subgroups of Group I and Group II. Similar findings were reported in earlier study of Johnson and Smith⁶ Prasad et al.²⁴ and Isikal et al.¹⁹ In present study, statistically non-significant difference was found for the

means of Ratio 4 in all groups. Similar finding was reported by Johnson and Smith⁶, Isikal et al.¹⁹ and Sarver and Ackerman¹³ who stated that in adolescents, it is often desirable to increase arch width with rapid maxillary expansion to create space for non-extraction treatment. For ratio 5, we did not find significant difference in males and females for both the groups. This showed that extraction and non-extraction subjects had same dental arches in relation to soft tissue. Sarver and Ackerman¹³ stated that non-extraction orthodontic treatment done by arch expansion and widening of collapsed arch form can dramatically improve the smile by decreasing the size of the buccal corridors and improving the transverse smile dimension. Ratio 6 or smile line ratio describes the corresponding harmony between arcs of curvature for the lower lip and for the maxillary incisor teeth. A ratio of 1:0 demonstrated the perfect harmony because the arcs should have equal depth.⁵ In this study, the ratio 6 was found less than 1.0 in both the groups. On comparison of mean values of ratio 6 non-significant difference was found which showed that smile line ratio did not differ in extraction and non-extraction orthodontic treatment. Similar findings were observed by Hulsey.⁵ Ratio 7 (smile symmetry ratio) depicted the symmetry of facial musculature of one side to other. No significant difference was found for ratio 7 in both groups indicated that extraction of teeth did not change smile symmetry ratio.

In the present study, intergroup comparison of other variables in males and females showed statistically non-significant differences in distribution of the all the variables except visible maxillary first molar which showed a significant difference ($p < 0.05$) for males and females in both groups. The upper lip curvature was expressed as positive if the corners of smile was superior to centre of the upper lip and as negative if the corners of smile was below the centre of upper lip. According to the mean smile score, smiles with the upper lip curving upwards were quite attractive. This fact is also suggested by Hulsey.⁵ In this study, the visible maxillary 1st molar was found to be higher in extraction group which may be due to some mesial migration of molars in extraction cases leading to their increased visibility. We did not observe significant difference for visible maxillary gingiva indicated that extraction treatment does not have a predictable effect on this feature, although several authors have pointed out that detrimental increases in gingival display occurs frequently from orthodontic treatment with excessive use of intermaxillary Class II elastics Johnson and Smith.⁶ Isikal et al.¹⁹ stated that upper lip should be at height of gingival margin of the maxillary central incisors in an attractive smile. Chinche and Pinault²⁶ stated that esthetically ideal amount of visible gingiva was about 1mm, although 2-3 mm of gingiva might be esthetically acceptable.

On intergroup comparison of mean and SD values of esthetic score, it was found higher in non-extraction group for both male and females but was statistically non-significant. Kim and Gianelly reported neither extraction nor nonextraction treatment has a preferential effect on smile esthetics.¹⁸ Results of meta-analysis conducted by Cheng et al revealed no significant differences in the esthetic score of extraction and non-extraction group.²² Prasad et al and Hulsey also reported lower smile esthetic score in orthodontic patients who were treated after extraction of all first premolar than subjects with normal esthetic score.

We found that lay person rated higher esthetic scores than by professionals except non-extraction male group. It was also found that lay persons gave higher esthetic scores to extraction males and non-extraction female group in contrary to professionals. Similar findings were reported by Prasad et al who noted that lay person generally rated higher esthetic scores than by professionals This finding was also supported by previous studies^{6,27,28} where professionals were sensitized to observe and evaluate the features that did not seem to influence the general public. According to Isikal et al.¹⁹ orthodontists on average were found to be more critical of dental esthetics than Lay peoples in detecting minor discrepancies. In present study, no significant correlations were found between the esthetic score and seven ratios in males and females of both Group I and Group II. Johnson and Smith⁶ found no relationship between the dental arch width/mouth width ratio during smiling and the esthetic score of the patient.

Results of present study showed that there was no difference between smile aesthetics in the extraction and non-extraction groups. Thus, the decision regarding extraction of all first premolars in treatment planning of orthodontic patients should not be solely based on smile aesthetics but other factors such as overjet, overbite, crowding, and soft tissue characteristics should be taken into consideration. This study examined certain characteristics of smile on standardized frontal smiling photographs. Additional data can be obtained from lateral cephalograms, direct biometric measurements which reveal the amount of vertical lip drape and amount of lip contraction over dentition at rest and during smiling. Digital videography can be a very useful in dynamic visualization and quantification of smile.

Conclusion

Statistically non-significant differences were found in smile esthetics and esthetic scores of orthodontic patients treated with and without extraction of all first premolars. Thus, decision regarding extraction of teeth in orthodontic patients should not be solely based on smile esthetics but other factors which determine extraction should be considered.

Lay person rated higher esthetic scores than by professionals except non-extraction male group.

No significant correlations were found between the esthetic score and seven ratios in males and females of both extraction and non-extraction group.

References

- Janson G, Branco NC, Fernandes TM, Sathler R, Garib D, Lauris JR. Influence of orthodontic treatment, midline position, buccal corridor and smile arc on smile attractiveness. *Angle Orthod.* 2011; 81:153-61.
- Stallard, H. Survival of the periodontium during and after orthodontic treatment. *Am J. Orthodontics.* 1964; 50:584-592.
- Mathews TG. The anatomy of smile. *J Prosthet Dent.* 1978; 39:128-34.
- Spahl T J, Witzig J W. The clinical management of basic maxillofacial orthopedic appliances. *PSG Publishing Co, Littleton.* 1987.
- Hulsey, C.M.: An esthetic evaluation of lip-teeth relationships present in the smile. *Am. J. Orthod.* 1970; 57:137-144.
- Johnson K. Darryl and Smith J Richard. Smile esthetic treatment with and without extraction of four first premolars. *Am J Orthod Dentofac Orthop.* 1995;108:162-67.
- Spahl TJ, Witzing JW. The clinical management of basic maxillofacial orthopedic appliances. Vol. 1. Mechanics. Littleton, Massachusetts : *PSG Publishing Co.* 1987.
- Dierkes JM. The beauty of the face: an orthodontic perspective. *J Am Dent Assoc.* 1987;89-95.
- Paquette DE, Beattie JR, Johnston Jr LE. A long-term comparison of non-extraction and premolar extraction edgewise therapy in "borderline" Class II patients. *Am J Orthod Dentofacial Orthop.* 1992;102:1-14.
- Luppanapornlarp S, Johnston Jr LE. The effects of premolar extraction: a long-term comparison of outcomes in "clearcut" extraction and non-extraction Class II patients. *Angle Orthod.* 1993;64:257-72.
- Frush, J.P., and Fisher, R.D.: The dynesthetic interpretation of the dentogenic concept. *J. Pros. Dent.* 1958;8: 558-81.
- Peck S, Peck L, Kataja. Some vertical lineaments of lip position. *Am J Orthod. Dentofac Orthop.* 1992; 101:519-24.
- Sarver M. David, and Ackerman, B. Marc. Dynamic smile visualization and quantification: Part I and II. Evolution of the concept and dynamic records for smile capture. *Am J Orthod Dentofacial Orthop.* 2003;124:4-12.
- Dustin R.J. Ronald G. and Jeryl English. The effects of buccal corridor spaces and arch form on smile esthetics. *Am J Orthod Dentofacial Orthop.* 2005; 127:343-50.
- Vig G.R., Brundo G.C.. The kinetics of anterior tooth display. *The J of prosthetic dent.* 1978;39(5):502-504.
- Ritter D.E, Gadine L.G. Santos Pinto A.D. Esthetic influence of negative space in buccal corridor during smiling. *Angle Ortho.* 2006;76:198-203.
- Frush, J.P., and Fisher, R.D. How Dentogenics interprets the personality factors? *J. Pros. Dent.* 1965;6(1):441-49.
- Cheng HC, WangYC, Tam KW, Yen MF. Effects of tooth extraction on smile esthetics and the buccal corridor: A meta-analysis. *Journal of Dental Sciences.* 2016;11,387-93.
- Isiksal E. Hazar S. and Akyalcin S. Smile esthetics: Perception and comparison of treated and untreated smiles. *Am J Orthod Dentofacial Orthop.* 2006;129:8.
- Tikku T, Khanna R, Maurya RP, Ahmad N. Role of buccal corridor in smile esthetics and its correlation with underlying dental and skeletal structures. *Indian J Dent Res.* 2012;23:187-94.
- Yang IH, Nahm DS, Baek SH. Which hard and soft tissue factors relate with the amount of buccal corridor space during smiling. *Angle Orthod.* 2008;78:5-11.
- Cheng HC, WangYC, Tam KW, Yen MF. Effects of tooth extraction on smile esthetics and the buccal corridor: A meta-analysis. *Journal of Dental Sciences.* 2016;11:387-93.
- Dai ML, Xiao M, Yu Z, Liu DX. Effect of extraction and nonextraction treatment on frontal smiling esthetics: a metaanalysis. *Shanghai Kou Qiang Yi Xue.* 2015;24:499-504.
- Prasad V, Tandon P, Sharma VP, Singh GK, Maurya RP, Chugh V. Photographical evaluation of smile esthetics after extraction orthodontic treatment. *J Orthod Res.* 2015;3:49-56.
- Ackerman JL, Ackerman MB, Bresinger CM, Landis JR. A morphometric analysis of the posed smile. *Clin Orthod Res.* 1998;1:2-11.
- Chin Che G.J. Pinault A. esthetics of anterior fixed prosthodontics. Chicago: *Quintessence.* 1994.