

Effects of functional therapy on hyoid bone, pharyngeal airway and tongue position in class II patients

Anuj Asem^{1,*}, Preeti Bhattacharya², Juhi Ansar³, Deepak Kumar Agarwal⁴, Ravi Bhandari⁵

¹Post Graduate, ²Professor, ³Reader, ⁴Professor, ⁵Senior Lecturer, Dept. of Orthodontics, Institute of Dental Sciences, Bareilly, Uttar Pradesh, India

***Corresponding Author:**

Email: asemanuj121@gmail.com

Abstract

Aim: The aim of this study is to evaluate the change in the position of hyoid bone, pharyngeal airway, and tongue position in subjects with skeletal Class II malocclusion treated with Twin block therapy.

Materials and Methods: This study was performed on pre and post treatment lateral cephalograms of 21 patients with class II malocclusion treated with Twin block appliance, (mean age of (12.24± 1.22). Paired-t test was used to compare the amount of differences of mean value before and after treatment. A value of P<0.05 was considered as significant.

Result: Hard tissue result showed significant difference between pre-and post-treatment values of ANB, Hy-B, Hy-Me & Hy-CL. But no significant difference was seen between the pre-and post-treatment values of Hy-SN' & Hy-FHP. Soft tissue examination also found significant difference between pre-and post-treatment values of SPAS, but no significant difference was observed between the pre-and post-treatment values of MAS, IAS, PT-CL & PT-SN'.

Conclusion: ANB angle was found to be significantly improved after functional treatment in skeletal class II group. The mandible has showed forward movement with respect to hyoid bone and the hyoid bone has been found to be shifted anteriorly and downward. Superior pharyngeal space was found to be significantly improved after functional therapy whereas there was no significant change with respect to tongue.

Keywords: Hyoid bone, Pharyngeal airway, Tongue, Twin block, Lateral cephalogram.

Introduction

The hyoid bone is located in the anterior portion of the neck and has no bony articulation.¹ It is connected to the pharynx, mandible, and cranium through muscles and ligaments and act as an anchoring structure for the tongue. Through their muscle attachment, the hyoid bone plays an important role in maintaining an airway, regulating deglutition and mandibular movement.²

The effect of the change in anteroposterior position of the mandible on hyoid bone position and the pharyngeal airway space is well documented.³⁻⁵ Studies have shown that changes in hyoid bone position tend to be related to changes in mandibular position.⁶ It has also been suggested that mandibular advancement with protrusion splint or orthognatic surgery is associated with a proportionate increase in oropharyngeal dimensions.⁴

The aim of functional therapy in young adults is to achieve maximum skeletal correction. As the hyoid bone is attached to the mandible through the muscle, Orthodontic myofunctional therapy can effect the position of hyoid bone by altering the mandibular position. These changes can be assessed with the use of radiographs such as lateral cephalograms, which are routinely used in orthodontic diagnosis and treatment planning

Skeletal Class II discrepancy with mandibular deficiency is considered as a risk factor for upper airway disorders and oropharyngeal airway deficiencies.⁷⁻¹⁰ In order to prevent the potential respiratory problems early orthodontic treatment of

mandibular deficiencies in skeletal class II patients would be beneficial.¹¹ Numerous types of functional appliances for correction of Class II relationship results in sagittal mandibular growth during adolescence. These appliances are also used to prevent apneas or airway problems by forcing the mandible, hyoid bone, tongue and soft palate forward, thus causing an increase in oropharyngeal dimensions.^{12,13}

This study was done to evaluate the changes in hyoid bone position, pharyngeal airway and tongue position after treatment with twin block functional appliance in patients with class II div I malocclusion.

Materials and Methods

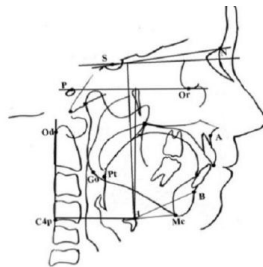
Pre-and post-treatment lateral cephalograms of 21 class II div 1 subjects treated with twin block were obtained from the orthodontic record files from the Department of Orthodontics and Dentofacial Orthopaedics and from the outpatient Department of Institute of Dental Sciences, Bareilly.

All cephalograms used in the study were obtained in natural head position as recommended by (Broadbent et al. 1975), on a digital x-ray machine (Allengers Smart PAN 2K15030009-D9). The subjects were positioned in the cephalostat with the sagittal plane at a right angle to the path of the X-rays, Frankfort plane parallel to the horizontal plane, teeth in centric occlusion, and the lips relaxed. During exposure of the X-ray, subjects were guided to stand still with the mandible in relaxed position to ensure that no strain or change in head posture occurred while the head was

fixed in the cephalostat. Kodak X-ray films (8" × 10") were exposed at 80 kVp, 10 mA for 0.8 s from a fixed distance of 60 inches by following the standard technique employed. The lateral head cephalograms were traced on acetate tracing sheets 0.5 μm in thickness using a sharp pencil on a view box using transilluminated light in a dark room.

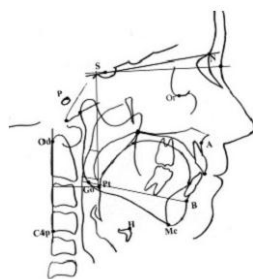
Measurement analysed were related to horizontal and vertical change in hyoid bone position, tongue position and also change in the air way dimensions. Measurements used to determine the horizontal change in hyoid bone position were Hy-B, HY-Me, Hy-CL. Out of which Hy-B & Hy-Me represent the hyoid bone movement with respect to the mandible. Hy-CL represent the movement of hyoid bone with respect to cervical vertebrae. Vertical changes in hyoid bone position were determined by Hy-FHP & Hy-SN'. (Fig. 1)

The change in the upper airway space (SPAS), middle airway space (MAS) & inferior airway space (IAS) were evaluated after functional appliance treatment. Change of tongue in horizontal and vertical position is determined by Pt-CL & Pt-SN'. (Fig 2)



H-SN perpendicular: Linear distance along a perpendicular from H to the S-N plane.
H-FH perpendicular: Linear distance along a perpendicular from H to the Frankfort plane.
H-CL: Perpendicular distance form H to the cervical line.
H-B: Line connecting hyoid to point B.
H-Me: Line connecting hyoid to Menton.

Fig. 1: Hard tissue parameters



SPAS: Superior posterior airway space (width of airway behind soft palate along parallel line to

Go-B line)

MAS: Middle airway space (width of airway along parallel line to Go-B line through P).

IAS: Inferior airway space (width of airway space along Go-B line)

Pt-CL: Perpendicular distance from Pt to the cervical line.

Pt-SN: Perpendicular distance form Pt to sella-nasion plane.

Fig. 2: Soft tissue parameters

Result

Statistical analysis of the data was done using the statistical package for the social science (SPSS 22.0). Paired-t test was used to compare the amount of differences of mean value before and after treatment. A value of $P < 0.05$ was considered as significant. Pearson correlation was used to find correlation between hard tissue and soft tissue, $P < 0.05$ consider statistically significant. The data was compiled using Microsoft excel sheet (windows 2007).

The pre- treatment & post-treatment hard and soft tissue measurements of subjects and their comparison have been displayed in Table 1 and 2. A highly significant difference was observed between pre-and post-treatment values of ANB ($p < .001$) with mean difference of 2.32° . A highly significant difference was observed between pre-and post-treatment values of Hy-B and Hy-Me ($p < .001$). It means that there was significant increase in distance between hyoid to point B (2.30mm) and hyoid to menton (2.73mm). A significant difference was observed between pre-and post-treatment values of Hy-CL ($p < .015$). It means that there was significant increase in distance between hyoid to CL (1.47 mm). However, there was no significant difference seen between the pre-and post-treatment values of Hy-SN' & Hy-FHP. It shows that there was no significant difference in the position of hyoid bone in vertical plane.

A significant difference was observed between pre-and post-treatment values of SPAS ($p < .007$). It means that there was significant increase in SPAS (1.23 mm), but no significant difference was observed between the pre-and post-treatment values of MAS & IAS. Also, there was no significant difference between pre-and post-treatment values of PT-CL & PT-SN' Showing that there was no significant difference in tongue position in both sagittal and vertical plane following functional appliance therapy.

Table 1: Comparison of pre-treatment and post treatment values of various hard tissue measurements in class ii group

Measurements (n=21)	Pre-treatment		Post-treatment		T/t Change	t-Value	p-Value
	Mean	S. D	Mean	S. D			
ANB (°)	5.61	2.27	2.78	1.92	2.329	4.132	<.001***
Hy-B(mm)	45.88	7.28	48.19	7.26	-2.30952	-5.860	<.001***
Hy-Me(mm)	37.29	6.84	40.02	6.18	-2.73810	-5.954	<.001***
Hy-CL(mm)	46.33	6.00	47.81	6.81	-1.47619	-2.666	<.015**
Hy-SN' (mm)	95.33	11.48	95.74	11.47	-.40476	-.672	.509
Hy-FHP(mm)	75.57	9.21	75.76	9.36	-.19048	-.304	.764

ns-p>0.05, *-p<0.05, **-p<0.01, ***-p<0.001

Table 2: Comparison of pre-treatment and post treatment values of various soft tissue measurements in class ii group

Measurements (n=21)	Pre-treatment		Post-treatment		T/t Change	t-Value	p-Value
	Mean	S. D	Mean	S. D			
PNS-P(mm)	31.31	4.06	31.67	4.40	-.35714	-.497	.624
SPAS(mm)	12.88	4.45	14.12	4.48	-1.23810	-3.026	.007*
MAS(mm)	10.69	3.90	11.14	3.90	-.45238	-1.116	.277
IAS(mm)	9.86	3.20	10.02	3.28	-.16667	-.471	.643
PT-CL(mm)	27.55	4.76	28.45	4.50	-.90476	-1.851	.079
PT-SN'(mm)	80.29	11.74	80.90	11.54	-.61905	-.911	.373

ns-p>0.05, *-p<0.05, **-p<0.01, ***-p<0.001

Discussion

Pre and post-treatment values after functional appliance treatment in class II subjects shows significant difference. In the present study the ANB angle was found to be significantly reduced ($p<.001$) after functional appliance therapy. Study by Toth and McNamara¹⁴ also found reduction in ANB angle by 1.8° in patients treated with the twin block appliance. Likewise, Illing et al¹⁵ also found statistically significant reduction in ANB angle when compared to controls after twin block appliance therapy.

Anteroposterior movement of the hyoid bone with respect to the mandible is represented by Hy-Me and Hy-B and with respect to cervical vertebrae by Hy-CL. In the present study, Hy-Me and Hy-B were found to be significantly increased ($p<.001$) which means that either the mandible moved forward or the hyoid bone moved posteriorly. However HY-CL distance was also found to be significantly increased ($p<.015$) showing that hyoid bone moved forward with functional appliance treatment. Study by Geeta Verma et al⁶ also showed increased in Hy-B, Hy-Me and Hy-CL following functional treatment.

Vertical position of hyoid is represented by HY-SN ($p>.509$) and HY-FHP ($p>.764$). Our study showed, hyoid bone moved non-significantly in an inferior direction after twin block therapy. Study by Zhou's et al¹⁶ also showed a downward displacement of the hyoid bone after functional treatment. In contrast to the present study Robertson CJ¹⁷ reported that hyoid bone moved upwards following functional mandibular advancement in the short-term; however, it moved

downwards towards its original position in the long-term as a compensatory action.

The mean value of the various soft tissue parameters have been summarized in Table 2. The results of this study indicate that following treatment with functional appliance, the tongue move forward (PT-CL) but, change was not significant ($p>.079$). However in a study done by S Yassaei et al¹⁸ following treatment with functional appliance tongue showed significantly forward movement. Also in our study tongue shows non-significant ($p>.373$) downward displacement in vertical plane (PT-SN') after functional therapy. Similar result were obtained by S Yassaei et al¹⁸ in which they reported non-significant downward displacement of tongue following functional appliance.

Increased in upper airway width SPAS was found to be significantly increased ($p<.007$) after treatment with functional appliance in the present study, whereas the middle pharyngeal airway space (MAS) ($p>.277$) and lower pharyngeal airway space (IAS) ($p>.643$) increased but the change was not significant. Batool Ali et al¹⁹ in their study reported, that the upper airway width, upper airway thickness and nasopharyngeal depth considerably improved after twin block treatment whereas middle and lower pharyngeal dimensions were not affected with functional appliances.

In this study upper airway width was increased by 1.24 mm. The increased in upper airway width found in the study was comparable with the study conducted by Han et al²⁰ in which an increase of 2 mm in upper airway width was found in skeletal class-II subjects who had undergone treatment with Bionator. In contrast to our findings, study by Ozbek et al¹² reported an

increase in upper, middle and lower airway dimensions whereas few other studies found an increase only in the superior and inferior pharyngeal dimensions.^{21,22}

The present study was conducted to find out any variation in the position of hyoid bone, position of tongue and pharyngeal airway in skeletal class II group and to find out if the upper mentioned structures shows any change after the functional appliance therapy. The result revealed that the position of hyoid bone shifted significantly anteriorly and non significantly downward after the functional appliance therapy in skeletal class II malocclusion. Pharyngeal airway space and tongue position also changed.

Conclusion

After functional appliance treatment in skeletal class II subjects. The hyoid bone has been found to be shifted anteriorly and downward. Superior pharyngeal space was found to be significantly improved after functional therapy whereas there was no significant change with respect to tongue.

Reference

1. Yassaei S, Soroush M: Changes in hyoid position following treatment of Class II division I malocclusions with a functional appliance. *Journal of Clinical Pediatric Dentistry* 2008;33:81-4.
2. Lin Y-C, Lin H-C, Tsai H-H: Changes in the pharyngeal airway and position of the hyoid bone after treatment with a modified bionator in growing patients with retrognathia. *Journal of Experimental & Clinical Medicine* 2011;3:93-8.
3. Kerr WJS: The nasopharynx, face height, and overbite. *The Angle orthodontist* 1985;55:31-6.
4. Battagel J, Johal A, L'Estrange P, Croft C, Kotecha B: Changes in airway and hyoid position in response to mandibular protrusion in subjects with obstructive sleep apnoea (OSA). *The European Journal of Orthodontics* 1999;21:363-76.
5. Achilleos S, Krogstad O, Lyberg T: Surgical mandibular setback and changes in uvuloglossopharyngeal morphology and head posture: a short-and long-term cephalometric study in males. *The European Journal of Orthodontics* 2000;22:383-94.
6. Verma G, Tandon P, Nagar A, Singh GP, Singh A: Cephalometric evaluation of hyoid bone position and pharyngeal spaces following treatment with Twin block appliance. *Journal of orthodontic science* 2012;1:77.
7. Sahoo NK, Jayan B, Ramakrishna N, Chopra SS, Kochar G: Evaluation of upper airway dimensional changes and hyoid position following mandibular advancement in patients with skeletal class II malocclusion. *Journal of Craniofacial Surgery* 2012;23:e623-e7.
8. Battagel JM, Johal A, Kotecha B: A cephalometric comparison of subjects with snoring and obstructive sleep apnoea. *The European Journal of Orthodontics* 2000;22:353-65.
9. Kim Y-J, Hong J-S, Hwang Y-I, Park Y-H: Three-dimensional analysis of pharyngeal airway in preadolescent children with different anteroposterior skeletal patterns. *American Journal of Orthodontics and Dentofacial Orthopedics* 2010;137:306. e1-. e11.
10. Oh K-M, Hong J-S, Kim Y-J, Cevidanes LS, Park Y-H: Three-dimensional analysis of pharyngeal airway form in children with anteroposterior facial patterns. *The Angle Orthodontist* 2011;81:1075-82.
11. Li Y: Early orthodontic treatment of skeletal Class II malocclusion may be effective to prevent the potential for OSAHS and snoring. *Medical hypotheses* 2009;73:594-5.
12. Murat Özbek M, Ufuk Toygar Memikoglu T, Gögen H, Lowe AA, Baspinar E: Oropharyngeal airway dimensions and functional-orthopedic treatment in skeletal Class II cases. *The Angle orthodontist* 1998;68:327-36.
13. Restrepo C: Oropharyngeal airway dimensions after treatment with functional appliances in class II retrognathic children. *Journal of oral rehab*, 2011;588-94.
14. Toth LR, McNamara JA: Treatment effects produced by the Twin-block appliance and the FR-2 appliance of Fränkel compared with an untreated Class II sample. *American Journal of Orthodontics and Dentofacial Orthopedics* 1999;116:597-609.
15. Illing HM, Morris DO, Lee RT: A prospective evaluation of bass, bionator and twin block appliances. Part I-the hard tissues. *The European Journal of Orthodontics* 1998;20:501-16.
16. Zhou L, Zhao Z, Lu D: The analysis of the changes of tongue shape and position, hyoid position in Class II, division 1 malocclusion treated with functional appliances (FR-I). *Hua xi kou qiang yi xue za zhi= Huaxi kouqiang yixue zazhi= West China journal of stomatology* 2000;18:123-5.
17. Robertson CJ: The effect of long-term mandibular advancement on the hyoid bone and pharynx as it relates to the treatment of obstructive sleep apnoea. *Australian orthodontic journal* 2000;16:157.
18. Yassaei S, Bahrololoomi Z, Soroush M: Changes of tongue position and oropharynx following treatment with functional appliance. *Journal of Clinical Pediatric Dentistry* 2007;31:287-90.
19. Ali B, Shaikh A, Fida M: Changes in oro-pharyngeal airway dimensions after treatment with functional appliance in class II skeletal pattern. *Journal of Ayub Medical College Abbottabad* 2015;27:759-63.
20. Han S, Choi YJ, Chung CJ, Kim JY, Kim K-H: Long-term pharyngeal airway changes after bionator treatment in adolescents with skeletal Class II malocclusions. *The Korean Journal of Orthodontics* 2014;44:13-9.
21. Vinoth SK, Thomas AV, Nethravathy R: Cephalometric changes in airway dimensions with twin block therapy in growing Class II patients. *Journal of pharmacy & bioallied sciences* 2013;5:S25.
22. Liu Y, Park Y-C, Lowe AA, Fleetham JA: Supine cephalometric analyses of an adjustable oral appliance used in the treatment of obstructive sleep apnea. *Sleep and Breathing* 2000;4:059-66.