

## Soft tissue profile changes in growing patients having Class II Division 1 Malocclusion treated by Modified Activator with lip bumper

Maher Fouda<sup>1</sup>, Ahmed Hafez<sup>2</sup>, Mohammed Al-Awdi<sup>3,\*</sup>

<sup>1</sup>Professor, <sup>2</sup>Lecturer, <sup>3</sup>PG Student, Dept. of Orthodontics, Mansoura University, Egypt

**\*Corresponding Author:**

Email: altabeeb2006@yahoo.com

### Abstract

**Objective:** to evaluate the soft tissue profile changes induced by modified Teuscher activator with lip bumper on growing patients.

**Materials and Method:** the present prospective clinical study consisted of fifteen subjects (8 girls and 7 boys) with skeletal class II division 1 malocclusion due to retrognathism of the mandible with mean age of (10.4 ± 0.6 years) years. Cases were selected to be treated for 14 months.

**Results:** A significant difference of all soft tissue variables from T0-T1 was found for both angular and linear measurements on the cephalometric radiographs analysis.

**Conclusion:** Treatment of Growing patients with Class II division 1 by Teuscher activator with lip bumper showed esthetic improvements due to significant changes in soft tissue profile, as a result of mandibular advancement.

**Keywords:** Soft tissue, Class II division 1 malocclusion, Modified activator, Lip bumper, Growing patients.

### Introduction

Class II malocclusion is considered as one of the most prevalent types of malocclusion encountered in routine orthodontic practice and described by an improper relationship among the upper and lower jaws caused by dental or skeletal problems or a combination of both.<sup>(1)</sup> Class II malocclusion is frequently observed, especially Class II division 1 which represents about 21% of Egyptian population.<sup>(2)</sup> According to McNamara Class II malocclusions result mostly from a relative mandibular retrognathism rather than from a maxillary prognathism. As a consequence, the treatment of choice for Class II malocclusion frequently requires mandibular advancement rather than maxillary retraction. In this respect, and in a historical sense, functional appliances of different designs have frequently been used in attempts to enhance mandibular growth.<sup>(3)</sup> The orthodontic profession is challenged with the treatment of malocclusions. Many perceived dental malocclusions have an underlying dentofacial orthopedic component.<sup>(4)</sup>

There are several important benefits which have been referred to the early management of class II division 1 malocclusion; prevention the development of dysfunction, avoidance of upper incisors trauma as a result of large overjet, aesthetic improvement, psychosocial advantages for the child during an important formative period of life, and better prediction for the adolescent phase of treatment.<sup>(5)</sup>

Aesthetic improvement is extremely appreciated by individuals whom seeking for orthodontic management. Class II malocclusion Cases are a respectable sample of subjects who are stated primarily for aesthetic enhancement by orthodontists.<sup>(6)</sup>

This study was aimed to evaluate the changes on soft tissue profile induced by Teuscher activator functional appliance on growing patients.

### Materials and Method

The sample in this study was conducted from Orthodontic Department, Faculty of Dentistry, Mansoura University, Egypt. The study consisted of fifteen subjects (8 girls and 7 boys) with skeletal class II division 1 malocclusion due to retrognathism of the mandible with mean age of (10.4 ± 0.6 years) years. The cases were selected to treat with modified Teuscher activator with lip bumper figure (1) and were followed for 14 months. Parent's of all subjects were allowed the study and provided informed consents.

The criteria for treatment were:

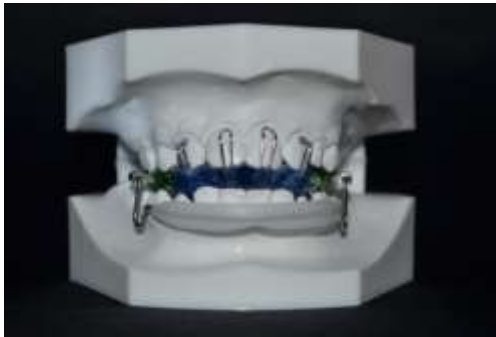- skeletal class II division 1 malocclusion
- dental class II division 1 malocclusion
- overjet (>5 mm)
- Upright or retroclined lower anterior teeth

Exclusion criteria were:

- Abnormal oral habits.
- High mandibular plane angle
- History of previous orthodontic treatment or orthognathic surgery.
- Systemic disease that may influence orthodontic treatment.

The activator appliance was fabricated according to the original design of Teuscher, with modification in the capping of the mandibular front teeth. In addition a lip bumper inserted into the headgear tube placed between the maxillary and mandibular teeth in the premolars area. Constriction bite was obtained by the aid of exactobite with 4-5 mm symmetrical advancement of the mandible every single activation and 3-4mm bite opening in the anterior region. After insertion and fitting of the appliance, at every visit the fit of the appliance was checked and the progress of the treatment was assessed by measuring the overjet. Trimming on the occlusal

aspect was performed to encourage the eruption of teeth. Patients and their parents were instructed to wear the activator at least 12 per day. When the treatment goals had been met and stability seem secured, patients were informed to wear the activator at night as a retainer and gradual reduction in the wearing hours was done Fig. 3 and 4.

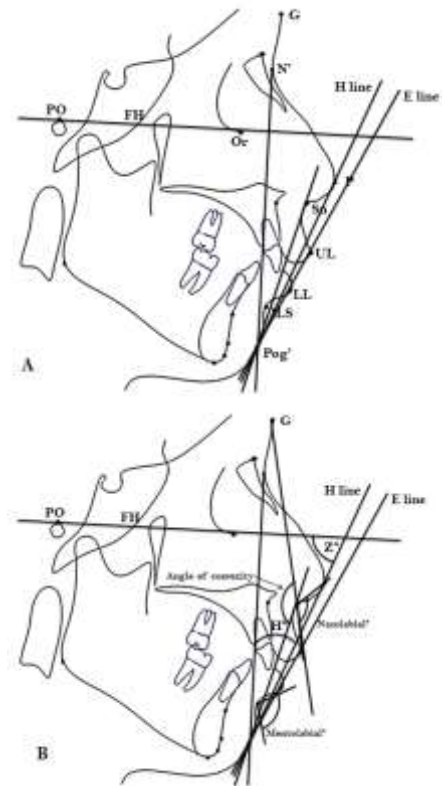


**Fig. 1: Teuscher activator with lip bumper**

Lateral cephalometric radiographs were obtained before (T0) and after (T1) treatment. All patients were informed to bite until the maximum intercuspation was achieved and their lips in a relaxed position during the capture.

The landmarks and measurements used are shown in Fig. 2 A and B. The following variables were used to investigate the pre and post-treatment changes:

1. **Nasolabial angle:** Angle formed by the intersection of a line originating from subnasale, tangent to the lower margin of the nose and a line between Sn and labrale superior.
2. **Z angle:** Inner inferior angle formed by the intersection of the Frankfort horizontal plane and profile line.
3. **Labiomental angle:** an angle forms between the lower lip and a line tangent to the superior convexity of the chin.
4. **The H angle:** is the angle formed between H-line and the soft-tissue nasion-pogonion line.
5. **Angle of convexity:** It is formed by the (G-Sn) line and the (Sn-Pog') line.
6. **Upper Lip –E.Line (mm):** The distance between upper lip and E-line.
7. **Lower Lip –E.Line (mm):** The distance between lower lip and E-line.



**Fig. 2A: lateral cephalometric radiographs**  
**Reference points:** porion (Po), Soft tissue glabella (G), orbitale (Or), soft tissue nasion (N'), Pronasale (P) Subnasale (Sn), labrale superior (Ls), Labrale inferior (Li), soft tissue pogonion (Pog').  
**Reference lines:** Frankfort horizontal plane (FH). E- line: is drawn from the tip of the nose to soft tissue pogonion. H-Line: is tangent to the chin point and the upper lip.

**Fig. 2B: lateral cephalometric measurements**

**Statistical Analysis:** The statistical analysis was achieved using SPSS software version 21.0 (SPSS, Chicago, IL, USA). Data were explored for normality using Shapiro-wilk test that shows it was normally distributed. A descriptive statistical analysis was used to present the data as mean and standard deviation (SD). Paired sample t- test was used to evaluate the significance of the difference in the pre and post treatment data.

## Results

All included cases had a class II division 1 malocclusion and increased overjet more than 5 mm. The management time was extended to 12 months. Mean and standard deviation values for every pre-treatment and post-treatment soft tissue variables were calculated as shown in (Table 2). Favorable treatment outcomes on the soft tissue profile were confirmed by an increased in the angle of convexity (3.2°, SD 1.2°). A significant increase in the Nasolabial (3.7°, SD 3.6°) and Labiomental (15.5°, SD 9.1°) angles. The H angle significantly increased by

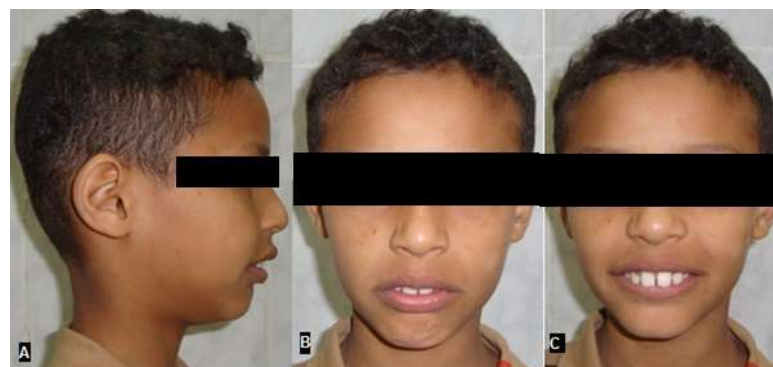(1.5°, SD 0.9°). Z angle also showed (3.1°, SD 2.4°) of significant increase. Linear variables of the upper and lower lip also presented significant differences (UL –E.

Line –; 1.7, SD 1.1mm) and (LL –E. Line; 2.8, SD 1.7 mm,) respectively.

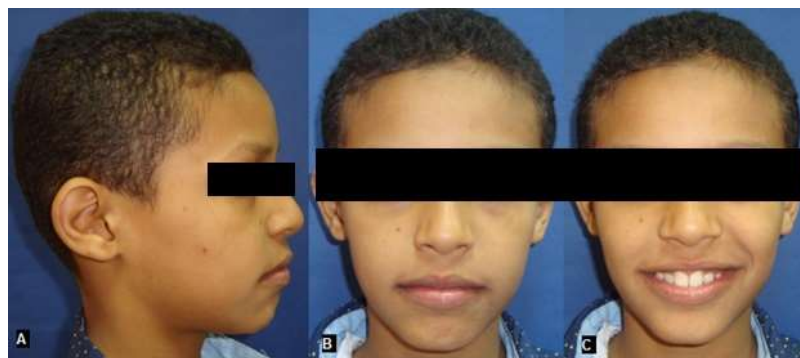**Table 1: Before and after treatment soft tissue changes resulted by Teuscher activator**

Variable	T0		T1		Mean	SD	P value	Sig
	Mean	SD	Mean	SD				
Nasolabial angle	123.750	8.7093	127.538	8.6043	3.7875	3.6899	.023*	*
Labiomental angle	120.313		135.813	11.1980	15.5000	9.1042	.002**	**
H angle	19.775	1.3058	18.188	.7736	1.5875	.9862	.003**	**
Angle of convexity	23.38	1.768	20.13	2.357	3.250	1.282	.000***	***
Z angle	67.013	4.7288	70.163	3.2487	3.1500	2.4255	.008**	**
Upper Lip – E.Line (mm)	.3913	1.92578	1.3813	.90844	1.77250	1.12256	.003**	**
Lower Lip – E.Line (mm)	1.0950	2.23967	1.7688	.91766	2.86375	1.71252	.002**	**

\*P < 0.05; \*\* P < 0.01; \*\*\*P < 0.001



**Fig. 3: Pre-treatment extraoral photographs A) lateral view B) frontal view C) smile view**



**Fig. 4: Post-treatment extraoral photographs A) lateral view B) frontal view C) smile view**

**Discussion**

Esthetic improvement is the leading purpose of orthodontic treatment. In patients with Class II division 1 due to retrognathism of the mandible and increased overjet, the convex profile may cause an undesirable feelings.

The soft tissues reveal the changes that have happened essentially in the underlying skeletal components. However, functional appliances, also

modify the soft tissue profile, besides improving the hard tissue relationship.<sup>(7,8)</sup>

Up to our knowledge there are a few studies that evaluated the changes of the soft tissue profile on class II division 1cases treated with activator appliance. So, the present study was attempted to evaluate the soft tissue alterations occurring in subjects treated with modified Teuscher activator with lip bumper.

In this study, the nasolabial angle was increased by (3.7°, SD 3.6 °) and became close to normal. Palatal movement of the maxillary incisors played an important role in retrusion of upper lip. This result was in harmony with.<sup>(9)</sup> Pretreatment measurements of the labiomental angle were low, lower lip trapping and eversion beneath the upper incisors. Decrease of the overjet produced uncurling of the lower lip. Labial movement of the mandibular incisors, which sequentially directed to an increase the labiomental angle significantly. This results agree with.<sup>(10)</sup> The advanced treatment changes on the facial profile were escorted by an increased the angle of convexity (3.2°, SD 1.2°) that was in agreement with.<sup>(11,12)</sup>

The E.Line in relation to lower and upper Lips showed positive changes leading to desirable lip relationship as a result of forward positioning of soft tissue Pogonion. Both<sup>(13,14)</sup> also showed the same changes. On the other hand, the effect of anterior movement of soft tissue Pogonion was reflected on significant changes in the Z angle. This finding was the same that obtained with.<sup>(15,16)</sup>

The value of the ANB angle is in association with Holdaway angle (H°). The decrease in the value of ANB angle led in order to decrease in the H° value. These results were supported by.<sup>(13)</sup>

### Conclusions

1. The improvement in facial appearance follows the alteration in the underlying hard tissue structures.
2. Treatment of Growing patients with Class II division 1 by Teuscher activator showed significant profile changes.
3. The most pronounced effects of the appliance were advancement of the soft tissue landmarks of the mandibular.
4. Further studies are required to assess the long-term significance and ultimate stability of the observed soft tissue changes must be considered.

### References

1. Proffit WR, Fields HW Jr ML. prevalence of malocclusion and orthodontic treatment need in the united states. *Int J Adult Orthodon Orthognath Surg.* 1998;13:97:106.
2. Fouda M.A. Disturbance of the accepted occlusion by extraction. *AL-Azhar D. J* 1987;2(5):453–67.
3. MCNAMARA JR JA. Components of Class II malocclusion in children 8-10 years of age. *Angle Orthod* 1981;51(3):177–202.
4. Bjork A. Facial growth in man, studied with the aid of metallic implants. *Acta Odontol. Scand.* 1955;13(1):9.
5. Basciftci FA, Uysal T, Buyukerkmen A, Sari Z. The effects of activator treatment on the craniofacial structures of Class II division 1 patients. *Eur J Orthod* 2003;25(1):87–93.
6. Dann C, Phillips C, Broder HL, Tulloch JF. Self-concept, Class II malocclusion, and early treatment. *Angle Orthod* 1995;65(6):411–6.
7. Lange DW, Kalra V, Broadbent BH, Powers M, Nelson S. Changes in soft tissue profile following treatment with the bionator. *Angle orthod* 1995;65(6):423–30.
8. Morris DO, Illing HM, Lee RT. A prospective evaluation of Bass , Bionator and Twin Block appliances . Part II — the soft tissues. *Eur J Orthod* 1998;20:663–84.
9. Varlik SK, Gültan A, Tümer N. Comparison of the effects of Twin Block and activator treatment on the soft tissue profile. *Eur J Orthod* 2008;30(2):128–34.
10. Nanda RS, Meng H, Kapila S, Goorhuis J. Growth changes in the soft tissue facial profile. *An* 1990;60(3):177–90.
11. Singh GD, Thind BS. Effects of the headgear-activator Teuscher appliance in the treatment of class II division 1 malocclusion: a geometric morphometric study. *Orthod Craniofac Res* 2003;6(2):88–95.
12. Marşan G. Effects of activator and high-pull headgear combination therapy: Skeletal, dentoalveolar, and soft tissue profile changes. *Eur. J. Orthod.* 2007;29(2):140–8.
13. McDonagh S, Moss JP, Goodwin P, Lee RT. A prospective optical surface scanning and cephalometric assessment of the effect of functional appliances on the soft tissues. *Eur J Orthod* 2001;23(2):115–26.
14. Akin M, Polat O, Ileri Z, Basciftci FA. Effects of the Activator and Twin Block on Facial Soft Tissue Thickness in Class II Division 1 Patients. *Turkish J orthod* 2015;27(3):128–35.
15. Bishara SE, Hession TJ, Peterson LC. Longitudinal soft-tissue profile changes: A study of three analyses. *Am J Orthod* 1985;88(3):209–23.
16. Kasai K. Soft tissue adaptability to hard tissues in facial profiles. *Am J Orthod Dentofac. Orthop* 1998;113(6):674–84.