

Effect of premolar extractions on facial vertical dimension- A cephalometric study

Saumil Dwivedi^{1,*}, Siddharta Sonwane², Heeralal Chokotiya³, Priyanka Patel⁴, Gaurav Gupta⁵

^{1,3}Senior Lecturer, ²Reader, Mansarovar Dental College, Bhopal, ⁴Private Practitioner, Surat, Gujarat, ⁵Private Practitioner, Lucknow, UP, Dept. Of Orthodontics & Dentofacial Orthopaedics

***Corresponding Author:**

Email: saumildwivedi@gmail.com

Abstract

Background: The purpose of this study was to compare changes in the facial vertical dimension in patients after the extraction of maxillary and mandibular premolars.

Materials and methods: The pre and post treatment records of 20 patients of age range 18-25 years who had skeletal class II with hyperdivergent facial form and have undergone maxillary and mandibular first premolar extractions for orthodontic treatment under Roth prescription were taken.

Results: There was significant increase seen in the maxillo-mandibular plane (MM angle) and Steiner's SN (Go-Gn) angle of pre and post treatment cephalometric records.

Conclusion: The results of this study showed that stress should be given on incisor intrusion and extrusion of molars should be avoided to prevent further increase in vertical dimensions in vertical growers.

Keywords: Vertical dimension, Premolar extractions.

Introduction

The extraction of premolars as a practical form of orthodontic therapy has been accepted for many years, but there remains a controversy regarding the effect of premolar extraction on the facial vertical dimension.

Some believe that premolar extraction permits the posterior teeth to move forward resulting in decrease in the vertical dimension of occlusion.

Few authors have reported an average increase in lower anterior facial height (LAFH) and total anterior facial height (TAFH) values in a group of untreated subjects with class II div 1 malocclusion between ages of 10-14 years.

The purpose of this study was to evaluate changes in vertical dimensions in patients with hyperdivergent facial form who have undergone maxillary and mandibular first premolar extractions for orthodontic treatment.

Materials and Methods

The pre and post treatment cephalometric tracings of 20 patients within the age range of 18 to 25 years who have undergone orthodontic treatment under Roth prescription were taken. All the patients selected had a skeletal class II with vertical growth pattern and indicated for all first premolar extraction. Tracings were done by the same investigator. Cephalometric measurements taken were:

- 1) SNA- Angle formed by the intersection of nasion-sella and nasion- A point lines
- 2) SNB- Angle formed by the intersection of nasion-sella and nasion- B point lines.
- 3) ANB- Angle formed by the intersection of nasion-A point and nasion- B point lines.

- 4) Maxillo-mandibular plane (MM angle) - Angle formed by the intersection of anterior nasal spine-posterior nasal spine and menton-pogonion lines.
- 5) Mandibular plane(MP angle)- Angle formed by the intersection of menton-gonion and orbital-porion lines
- 6) Total anterior facial height (TAFH)- The distance between nasion and menton.
- 7) Lower anterior facial height (LAFH) - The distance between anterior nasal spine and menton.
- 8) Posterior facial height (PFH) - The distance between sella and gonion.
- 9) LAFH/TAFH- Ratio of the distance between anterior nasal spine and menton to the distance between nasion and menton.
- 10) PFH/TAFH- Ratio of the distance between sella and gonion to the distance between nasion and menton.

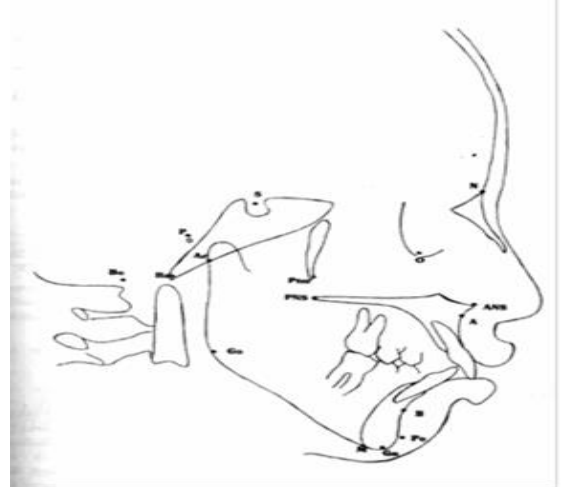


Fig. 1: Hard tissue landmarks

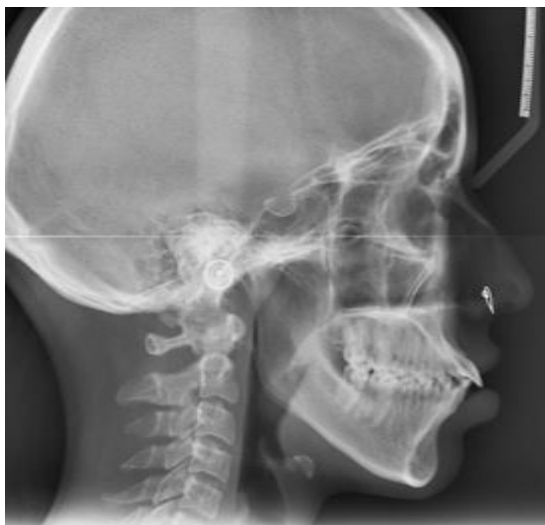

Fig. 2: Lateral cephalogram

Table 1: Comparison of parameters

Parameters	Pre (n=20)	Post (n=20)	Mean change	t and p-value ¹
MM angle	37.90±0.88	40.50±.56	2.6	3.47, 0.007*
MP angle	25.10±0.45	25.90±.52	0.80	1.07, 0.30
TAFH	113.00±2.92	113.30±2.48	0.30	0.34, 0.73
LAFH	64.20±3.75	65.30±3.51	1.10	1.31, 0.22
PFH	72.00±3.57	72.95±3.58	0.05	0.09, 0.92
LAFH/TAFH	0.57±0.01	0.58±0.01	0.01	0.42, 0.67
PFH/TAFH	0.63±0.06	0.63±0.07	0.00	NA
SN (Go-Gn)	34.40±0.78	35.60±0.98	1.20	3.08, 0.01*

¹Paired t-test, *Significant, Values are in Mean±SD

Results

Table 1 shows Means and Standard deviations for the 7 variables that represent vertical dimensions were calculated. Difference between the two records was determined with Paired t-test. P values less than .05 were considered significant.

The mean changes resulting from treatment reflected a significant increase in MM angle and SN (Go-Gn) which showed that there was opening up of MP angle.

There was also increase in the mean values of LAFH, TAFH and PFH after treatment but the increase was statistically insignificant.

The change in ratios LAFH/TAFH and PFH/TAFH between pre and post treatment cephalograms was also found to be insignificant.

Discussion

In a patient presenting a dolichofacial growth pattern, every care should be taken not to promote undue extrusions, which, in turn, are associated with an increase in the vertical dimensions and worsening of the relationship among lips, teeth and bony structures. In many previous studies, there was increase in the vertical facial dimensions of patients after the treatment. As

most of these patients were in their growing age, hence increase in vertical dimension was because of growth or mechanics involved cannot be ascertained. (Kazem S. Al-Nimri,⁽¹²⁾ Chua et al⁽⁶⁾ and Staggers⁽⁷⁾ and Kocadereli,⁽⁸⁾ Rothstein and Phan⁽¹⁴⁾). Sivakumar and Valiathan⁽¹³⁾ similarly showed that linear vertical dimensions increased in both the extraction and the non-extraction groups and the changes were comparatively greater in the extraction group.

The present study showed opening up of mandibular plane angle which suggests that vertical changes were observed in patients with hyper divergent facial form which were not desirable. In another study by M.S. A. Akhouni, M. Noori Sari F. Mojtahedzadeh,⁽¹¹⁾ insignificant decrease in vertical dimensions could be attributed to the mechanics employed during fixed orthodontic treatment (MBT technique) as the growth was complete in the selected subjects.

Chua⁽⁶⁾ et al found that premolar extraction was not associated with any significant change of the lower anterior facial height (LAFH), whereas non-extraction treatment was associated with a significant increase in LAFH. On the other hand, Staggers⁽⁷⁾ and Kocadereli⁽⁸⁾ found that the vertical changes that occurred after the extraction of first premolars were not different from

those that occurred in the nonextraction cases. However, in these two studies, it was pointed out that there was minimal need for protraction of posterior teeth because most of the extraction space was used to relieve crowding or to retract the anterior teeth. It could be suggested that in vertical growers stress should be on incisor intrusion and prevention of molar extrusion.

As per Roth^(9,10) mechanics used in our study, intrusion was achieved by alteration in bracket placement or using long Class II elastics from second molars. In vertical growers intrusion arches to achieve incisor intrusion should be employed as well.

Conclusion

- The study showed significant increase in the MM angle and SN (Go-Gn) angle. Increase in the other vertical facial dimensions was insignificant.
- This study suggested suggested that in vertical growers, stress should be on incisor intrusion and extrusion of molars should be avoided.

References

1. Schudy FF. Vertical growth versus anteroposterior growth as related to function and treatment. *Angle Orthod.* 1964;34:75-93.
2. Schudy FF. The rotation of the mandible resulting from growth: its implication in orthodontic treatment. *Angle Orthod.* 1965;35:36-50.
3. Kim TK, Kim JT, Mah J, Yang WS, Baek SH. First or Second Premolar Extraction Effects on Facial Vertical Dimension. *Angle Orthod* 2005(2);75:177-182.
4. Hans MG, Grossier G, Damon C, Amberman D, Nelson S, Palomo JM. Cephalometric changes in overbite and vertical facial height after removal of 4 first molars or first premolars. *Am J Orthod Dentofacial Orthop* 2006 Aug.; 130(2):183-8.
5. Hayashi RK, Chaconas SJ, Caputo AA. Effects of force direction on supporting bone during tooth movement. *J Am Dent Assoc* 1975 May; 90(5):1012-7.
6. Chua A, Lim JYS, Lubit EC. The effect of extraction versus non-extraction orthodontic treatment on the growth of the lower anterior face height. *Am J Orthod Dentofacial Orthop.*1993;104:361-368.
7. Staggers JA. Vertical changes following first premolar extractions. *Am J Orthod Dentofacial Orthop.* 1994;105:19-24.
8. Kocadereli I. The effect of first premolar extraction on vertical dimension. *Am J Orthod Dentofacial Orthop.* 1999;116:41-45.
9. Roth RH. The straight-wire appliance 17 years later. *J Clin Orthod* 1987;21(9):632-42.
10. Roth RH Treatment concepts using the fully pre-adjusted three-dimensional appliance. In: Graber TM, Vanarsdall RL. *Orthodontics; current principles and techniques*, 3rd ed. St. Louis: Mosby Yearbook; 2000.
11. Akhouni M, Noori Sari M, Mojtahedzadeh F. Cephalometric Evaluation of Dental and Skeletal Changes in the Vertical Dimension During the First Stage of Treatment using Preadjusted Brackets and the MBT Technique. *Journal of Dentistry, Tehran University of Medical Sciences* 2005;86(2):86-90.
12. Al-Nimri KS. Vertical changes in class II division 1 malocclusion after premolar extractions. *Angle Orthod* 2006;76:52-8.
13. Sivakumar A, Valiathan A. Cephalometric assessment of dentofacial vertical changes in class I subjects with and without extraction. *Am J Orthod Dentofacial Orthop* 2008;133:869-75.
14. Rothstein T, Phan XL. Dental and skeletal characteristics and growth of females and males with Class II division 1 malocclusion between the ages of 10 and 14 (revisited). Part II. Anteroposterior and vertical circumpubertal growth. *Am J Orthod Dentofacial Orthop.* 2001;120:542-555.