

Methods of cephalometric superimposition - A review

Sara Asif¹, Mohammad Tariq^{2,*}

¹JR – III, ²Professor department of orthodontics Dr. Z. A. Dental College AMU, Aligarh

Corresponding Author:

Email: jmi786jmi@gmail.com

Abstract

In 1931, Broadbent^(7,8) and Hofrath⁽¹²⁾ introduced the technique of radiographic cephalometry. Since then, clinicians and researchers have adopted and routinely used this valuable tool on orthodontic patients in order to analyse underlying dentofacial relationships. Cephalometrics Superimposition is used to gain a better understanding of the facial changes that accompany growth and/or orthodontic treatment.

Keywords: Cephalometrics, Superimposition.

Introduction

A cephalometric superimposition is an analysis of lateral cephalograms of the same patient taken at different times. It is used to evaluate a patient's growth pattern between different ages and to evaluate changes in the dentoalveolar and basal relationships after a course of orthodontic or surgical treatment. Cephalometric procedures and evaluations are considered in the light of; pretreatment objectives, orthodontic treatment modalities used, long-term follow-up of the treatment results and during the retention and post-retention periods.

Over the time various methods of superimposition have been developed. The aim of this article is to provide an overview of the various cephalometric techniques.

Methods of superimposition of cranial base structures

Decoster method: According to Decoster, the bony anatomy of the anterior contour of the cranial base i.e. the anterior half of the sella turcica to the foramen caecum and the internal outline of the frontal bone are stable support for superimposition. Later Richardson found that DeCosters cribriform plane was only moderately successful as far as reproducibility was concerned. Its applicability did not favor the usage of this line.⁽¹¹⁾

Broadbent triangle: The Broadbent triangle (Na-S-Bo) and its registration point R were among the first structures used for superimpositions to determine overall changes. With this method, the two tracings are oriented so that the R points are registered and the Bolton planes (Bo-Na) are parallel.^(7,8)

Sella –nasion line: Orients the two tracings on the Sella-nasion line with registration at Sella. Provides composite view of the amount of growth change. It is accurate as long as the growth change at nasion

follows the linear extension of the original sella-nasion line.⁽²¹⁾

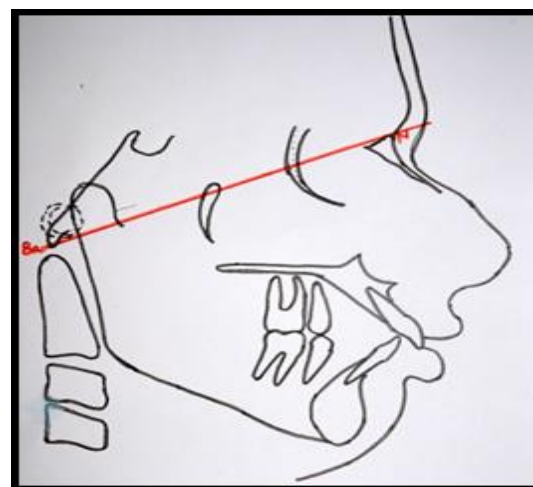


Fig. 1

Basion horizontal by Coben: Basion is used as the point of reference. The line from Basion drawn parallel to the original FH, of the several radiographs, establishes the constant SN-FH relationship and the Basion Horizontal plane of the series. Each subsequent coordinate tracing film may be superimposed by simply aligning the co-ordinate grids that have been especially designed for this purpose.^(9,10)

Basion-nasion plane Ricketts

Rickett's proposed the Basion-Nasion plane as an area of registration for overall evaluation of the dentofacial changes. The superimposition area as the Ba-Na line with registration at CC point helps to evaluate changes in facial axis, direction of chin growth, and upper molar position.⁽¹⁴⁻¹⁶⁾

Bjork's structural method

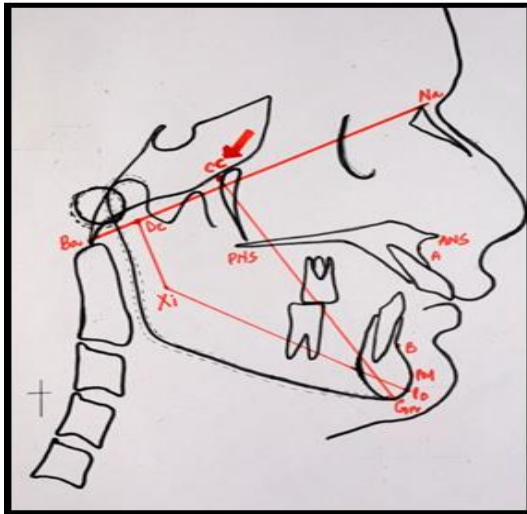


Fig. 2

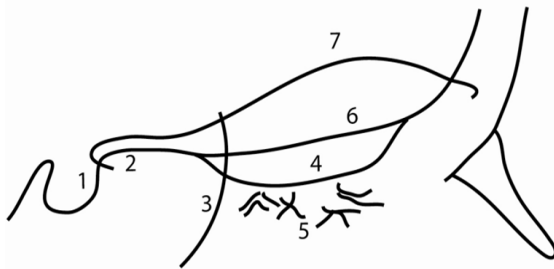


Fig. 3

Longitudinal growth studies by Björk using metallic bone markers shown that certain structures in the anterior cranial base are stable after a certain age. These stable anatomical structures in the anterior cranial base are used as reference structures when radiographs from different age stages are superimposed.⁽¹⁻⁶⁾

Methods of maxillary superimposition

The maxillary base superimposition involves superimposing along the various structures mentioned below.⁽²⁰⁾

- Palatal plane registered at anterior nasal spine (ANS.)
- Nasal floors with the films registered at the anterior surface of the maxilla.
- Palatal plane registered at the pterygomaxillary fissure.
- Outline of the infratemporal fossa and the posterior portion of the hard palate.
- Registering the maxilla on the common Ptm coordinate, maintaining the Basion Horizontal relationship.
- Best fit of the internal palatal structures.
- Superimposition on metallic implants.

- The structural superimposition on the anterior surface of the zygomatic process of the maxilla.

Methods of mandibular superimposition

A number of areas have been suggested for superimpositions, including: Lower border of the mandible; Tangent to the lower border of the mandible; and Constructed mandibular plane between Menton and Gonion. However, these methods are not very accurate and significant remodelling occurs at mandibular border.

From their implant studies, Bjork⁽¹⁾ and Bjork and Skieller⁽⁴⁾ have indicated that the following structures are relatively stable and could be used; The anterior contour of the chin, Inner contour of the cortical plates at the inferior border of the symphysis and any distinct trabecular structure in the lower part of the symphysis, Posteriorly, the contours of the mandibular canal, Lower contour of a mineralized molar germ.

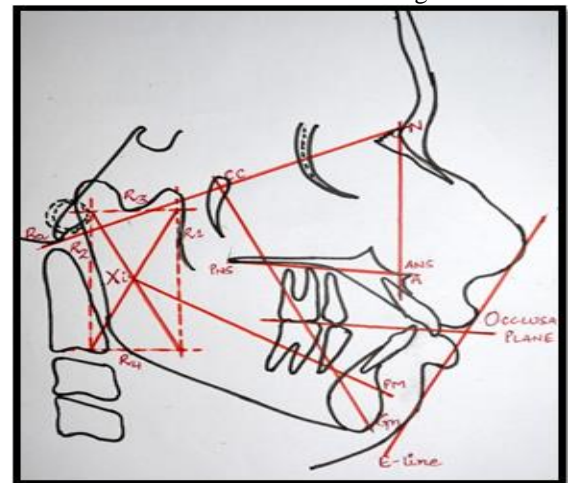


Fig. 4

Ricketts superimposition method-

It is used to differentiate the changes in normal growth and those due to treatment mechanics. This technique involves five superimposition areas; the chin, the maxilla, the teeth in the maxilla, the teeth in the mandible, the facial profile.⁽¹⁵⁻¹⁸⁾

Pitchfork analysis

Johnston in 1985, described the different treatment strategies to correct Class II malocclusion where the data is recorded in a pitch fork manner. All measurements are executed parallel to the mean functional occlusal plane and are given signs appropriate to the nature of their contribution to the molar and overjet changes or correction.⁽¹³⁾

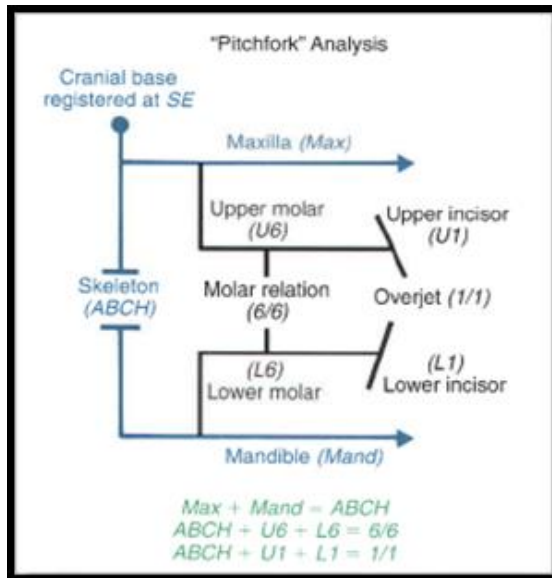


Fig. 5

American board of orthodontics superimposition method

The purpose of superimpositions is to aid the orthodontist in determining the skeletal and dental changes that occur over time. Three superimpositions are required by the American Board of Orthodontics: Cranial Base, Maxillary, and Mandibular Superimpositions. These superimpositions must be performed using the structural method, which is based on the use of stable structures described in Melsen's research of cranial base growth, Bjork and Skieller's implant research, as well as Enlow's investigation of remodeling. The structural method has been shown to be reliable and valid.⁽¹⁹⁾

3D superimposition technique

Generally, there are two approaches. Registration point approach uses a number of reference points that are registered on two volumetric images and these points are made to coincide when superimposing two images. E.g.: Dolphin 3D and In Vivo Dental.^(22,23)

The second approach uses the mathematical algorithm method, in which a certain volume of interest is first defined for use as the reference volume. Then, a particular mathematical algorithm, based on the probability and information theory, calculates the best fit of the two VOIs and automatically superimposes the two volumetric images.

Conclusion

To perform an accurate superimposition, one has to have an excellent knowledge of the anatomy of the dentofacial and cranial structures as well as of the radiographic interpretation of these structures. This is essential, since the radiograph is a two-dimensional image of three-dimensional structures. Without such knowledge and understanding, radiographic

interpretations become a guessing game rather than the science that cephalometrics is supposed to be. Though now a days the quest for the development of a better and more accurate 3D technique is captivating the interest of many clinicians, conventional cephalometric superimposition methods are still considered to be the gold standard.

References

1. Bjork A (1963) Variations in the growth pattern of the human mandible: Longitudinal radiographic study by the implant method. / Dent Res 12:400-11.
2. Bjork A, Skieller V (1977a) Growth of the maxilla in three dimensions as revealed radiographically by the implant method. Br J Orthod 4:53-64.
3. Bjork A, Skieller V (1977b) Roentgencephalometric growth analysis of the maxilla. Trans Eur Orthod Soc 7:209-33.
4. Bjork A, Skieller V (1983) Superimposition of profile radiographs by the structural method. In: Normal and Abnormal Growth of the Mandible. Eur J Orthod 5:40-6.
5. Bjork A, Skieller V (1976) Postnatal growth and development of the maxillary complex. In: McNamara JA Jr (ed) Factors Affecting the Growth of the Midface. Monograph No. 6. (University of Michigan: Ann Arbor) 61-99.
6. Bjork A, Skieller V (1983) Superimposition of profile radiographs by the structural method. In: Normal and Abnormal Growth of the Mandible. Eur J Orthod 5:40-6.
7. Broadbent BH (1931) A new X-ray technique and its application to Orthodontia. Angle Orthod 1:45-66.
8. Broadbent BH (1937) Bolton standards and technique in orthodontic practice. Angle Orthod 7:209-33.
9. Coben SE (1979) Basion Horizontal coordinate tracing films. J Clin Orthod 13:598-605.
10. Coben SE (1986) Basion Horizontal: An integrated Concept of Craniofacial Growth and Cephalometric Analysis. (Computer Cephalometric Associated: Jenkintown, Pennsylvania.)
11. DeCoster L.A new line of reference for the study of lateral facial telerradiographs. Am J Orthod 1953;39:304-6.
12. Hofrath H (1931) Die Bedeutung der Rontgenfern und Abstandsaufnahme für die Diagnostik der Kieferanomalien. Fortschr Orthodont 1:232-57.
13. Johnston LE Jr. An objective evaluation of the pitchfork analysis Eur J Orthod. 2002 Feb;24(1):121-2.
14. Ricketts RM (1960) The influence of orthodontic treatment on facial growth and development. Angle Orthod 30:103-32.
15. Ricketts RM (1972) An overview of computerized cephalometrics. Am J Orthod 61:1-28.
16. Ricketts RM (1975) New perspectives on orientation and their benefits of clinical orthodontics – Part I. Angle Orthod 45:238-48.
17. Ricketts RM (1981) Perspectives in the clinical application of cephalometrics. Angle Orthod 51:115-50.
18. Ricketts RM, Bench RW, Gugino CF, Hilgers JJ, Schulhof RJ (1979) Bioprogressive Therapy. (Rocky Mountain Orthodontics: Denver, Colorado.)
19. <https://www.americanboardortho.com>.
20. Orthodontic Cephalometry by Athanasios E. Athanasios.
21. Steiners CC .Cephalometrics in clinical practice Angle Orthod 1959;29:8-29.

22. Cho HJ. A three-dimensional cephalometric analysis. J Clin Orthod. 2009 Apr;43(4):235-52.
23. Cho HJ. Three dimensional Imaging. 2010. Faculty files: P C S O Bulettein 23-27.