

## Overview of diagnostic tools in maxillary canine impaction

Devanshi Yadav Anand<sup>1,\*</sup>, MS Rani<sup>2</sup>, Dhruv Anand<sup>3</sup>, Anadha Gujar<sup>4</sup>, Shailaja AM<sup>5</sup>

<sup>1</sup>Orthodontist, Dental Square, Noida, Uttar Pradesh, <sup>3,5</sup>Professor, VS Dental College, Bangalore, <sup>4</sup>Senior Lecturer, Dept. of Orthodontics, KLE Institute of Dental Sciences, Bangalore, <sup>2</sup>Senior Lecturer, Dept. of Prosthodontics, School of Dental Sciences, Sharda University, Greater Noida, Uttar Pradesh

**\*Corresponding Author:**

Email: devanshiyadav@gmail.com

---

### Abstract

Permanent maxillary canines are the second most frequently impacted teeth. The prevalence of their impaction is 1-2% in the general population. This is most likely due to an extended development period and the long, tortuous path of eruption before the canine emerges into full occlusion. Methods of diagnosis that may allow for early detection and prevention should include a family history, visual and tactile clinical examinations by the age of 9-10 years and a thorough radiographic assessment. When the condition is identified early, extraction of the maxillary deciduous canines may, in specific cases, allow the impacted canines to correct their paths of eruption and erupt into the mouth in relatively good alignment. The aim of this article is to summarize current literature about the localization of the impacted canines and the various analysis applicable, also to introduce transtomography as a diagnostic tool.

**Keywords:** Canine impaction, Inspection, Palpation, Radiographs, CT, CBCT, Transtomography

---

### Introduction

Impaction is a pathological condition defined by the lack of eruption of a tooth in the oral cavity within the time and physiological limits of the normal eruption process<sup>1</sup>.

Permanent maxillary canines are the second most frequently impacted teeth; the prevalence of their impaction is 1-2% in the general population.<sup>2</sup> Methods of diagnosis that may allow for early detection and prevention should include a family history, visual and tactile clinical examinations by the age of 9-10 years and a thorough radiographic assessment<sup>2</sup>.

### Etiology of Impaction

Eighty-five per cent of impacted maxillary permanent cuspids are palatal, and 15% are labial. Inadequate arch space and a vertical developmental position are often associated with buccal canine impactions. If buccally impacted cuspids erupt they do so vertically, buccally and higher in the alveolus. Due to denser palatal bone and thicker palatal mucosa, as well as a more horizontal position, palatally displaced cuspids rarely erupt without requiring complex orthodontic treatment. It is not unusual for maxillary canine impaction to occur bilaterally, although unilateral ectopic eruptions are more frequent.<sup>2</sup>

The main hypotheses proposed to explain the etiology of impacted canines according to Peck and Peck tend to favour a genetic origin<sup>3</sup>, as also by Baccetti<sup>4</sup>. Becker leans towards the guidance theory, i.e. obstruction of the path of eruption of the canine by the lateral incisor<sup>5,6</sup>. Bishara gives an explanation based on the existence of general (endocrine pathology, fever, irradiation) and local (dentoalveolar discrepancies, retention or early loss of deciduous canines, anomalous position of the permanent tooth bud, presence of cleft

palate, dental ankylosis, factors cystic or neoplastic formations, dilaceration, iatrogenous causes) factors<sup>7</sup>, Jacoby also adheres to the guidance theory and sustains that agenesis of the lateral incisor, or root malformations of form and dimension or timing of root development could be determining factors in canine displacement.<sup>8</sup>

### Why localization is important?

Localization is vital, as it is a sound principle to never extract a well-placed tooth in order to make a space for a poorly positioned one. If a well-placed tooth is preserved, treatment time may be shortened considerably, and the result will be more certain. The reverse also holds true. If a poorly placed canine is kept and a well-aligned tooth extracted, then treatment time will be prolonged and the result will be less sure. Due to an error in localization, a flap could be raised and an uncovering or a removal attempted in the wrong area.

The clinician must be able to estimate the difficulty involved in uncovering a displaced canine. Uncovering a malpositioned canine may be more hazardous to the adjacent teeth than extracting it. If suitable clinical conditions exist, a palatally impacted maxillary canine may be induced to erupt in the line of the arch, and the only treatment is extraction of the deciduous canine. This procedure may also reduce the incidence of resorbed adjacent incisor roots by palatally impacted maxillary canine<sup>9</sup>.

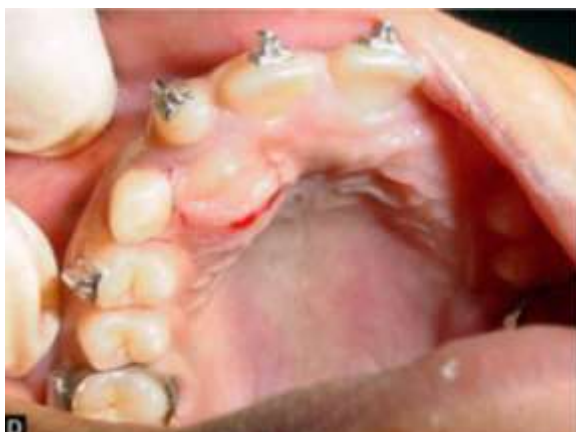Early detection will thus reduce treatment time, complexity, cost and complications.

There are three methods of localization: Inspection, Palpation and Radiography

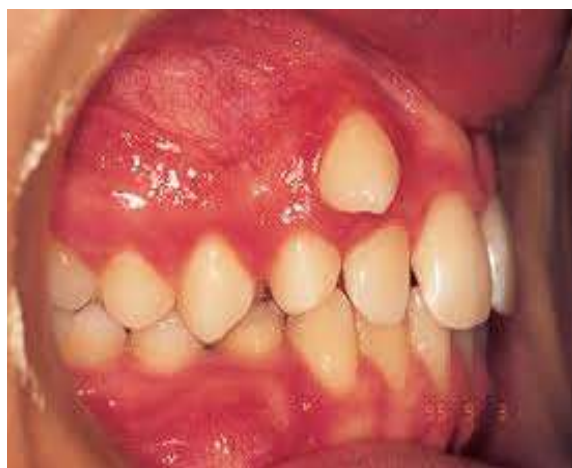### Inspection

The clinician may see the bulge of the unerupted canine and/or observe that the position of the adjacent

lateral incisor is being influenced by the impacted canine. If the impacted canine is palatally placed, it may press on the root of the lateral incisor and push the root labially, and the crown moves palatally. Therefore, the lateral incisor is retroclined in relation to the central incisor. If the impacted tooth is labially placed it may press on the root of the lateral incisor and push the root palatally, and the crown moves labially. Therefore, the lateral incisor is proclined in relation to the central incisor. Lateral incisors are much more commonly affected than first premolars because most impactions are mesio-angular impactions and have migrated mesially as well. Occasionally the position of a central incisor is affected by an impacted canine<sup>9</sup>.



**Fig. 1: Palatally impacted canine**



**Fig. 2: Buccally impacted canine**

### Palpation

The next step in localizing is palpation. Palpation of the buccal and lingual mucosa, using the index fingers of both hands simultaneously, is recommended to assess the position of the erupting maxillary canines<sup>2</sup>.

Eruption time of a maxillary canine varies from 9.3 to 13.1 years. Canines are palpable from 1 to 1.5 years before they emerge, the absence of the canine bulge after the age of 10 years is a good indication that the tooth is displaced from its normal position, and ectopic eruption

or impaction of the maxillary cuspids is possible. Asymmetries in the alveolar process are not considered significant in children younger than 10 years, and differences in bilateral palpation could be due to vertical differences in eruption rates at young ages. However, in patients older than 10 years, an obvious palpable bilateral asymmetry could indicate that one of the permanent cuspids is impacted or erupting ectopically.<sup>2</sup>

However, occasionally the bony canine eminence has been confused with the tooth, and the fact that a canine is impacted has been missed. The clinician should also manipulate the deciduous canine to determine if it is mobile. If it is, this indicates that its root has undergone significant resorption. However, this mobility does not guarantee that the permanent canine is erupting normally. If a canine is palpable in an abnormal position or cannot be palpated, radiographs are required for its localization.<sup>1</sup>

### Radiography

Radiographs are indicated when canine bulges are not present, right and left canine development and eruption is asymmetrical, occlusal development is advanced and there are no palpable bulges indicating the presence of the cuspids in the alveolar process and the lateral incisor is delayed in eruption, malpositioned, or has a pronounced labial or palatal inclination in relation to the adjacent central incisor.<sup>2</sup>

Accurate radiographs are critical for determining the position of impacted canines and their relation to adjacent teeth, assessing the health of the neighbouring roots and determining the prognosis and best mode of treatment.<sup>2</sup>

The conventional radiographic techniques that are used are – intraoral periapical radiograph (IOPA), occlusal radiograph, orthopantomograph (OPG) which suffice for simple cases of impaction but for difficult cases not only is correct diagnosis required but also precise location, accurate assessment of the relation of the adjacent teeth and the surrounding anatomic structures, for the above stated procedures advanced radiography is useful in planning the treatment.

The advanced radiographic techniques include computed tomography (CT), cone beam computed tomography (CBCT) and transtomography.

### Intra oral periapical radiographs (IOPA)

A single periapical film provides the clinician with a two-dimensional representation of the dentition. In other words, it would relate the canine to the neighbouring teeth both mesiodistally and superoinferiorly. To evaluate the position of the canine buccolingually, a second periapical film should be obtained by one of the following methods –

- a. Tube-shift technique or Clark's rule - Two periapical films are taken of the same area, with the horizontal angulation of the cone changed when the second film is taken. If the impacted canine in question

moves in the same direction as the cone, it is lingually positioned. If the canine moves in the opposite direction, it is situated closer to the source of radiation and is therefore buccally located.

- b. Buccal-object rule - If the vertical angulation of the cone is changed in two successive periapical films, the buccal object will move in the direction opposite the source of radiation. On the other hand, the lingual object will move in the same direction as the source of radiation. The basic principle of this technique deals with the foreshortening and elongation of the images of the films.<sup>10</sup>

### Occlusal Radiographs

Occlusal films also help determine the buccolingual position of the impacted canine in conjunction with the periapical films, provided that the image of the impacted canine is not superimposed on the other teeth.<sup>10</sup>

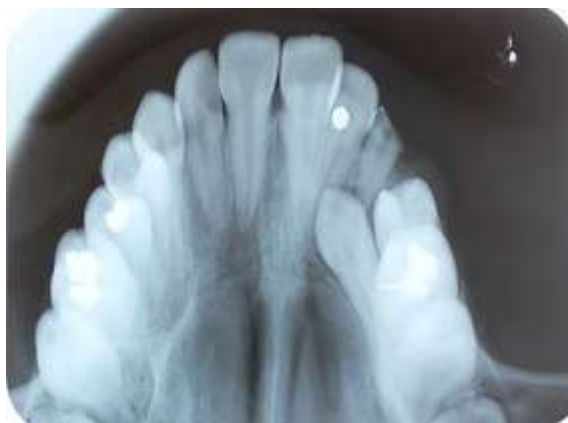


Fig. 3: Palatally impacted canine

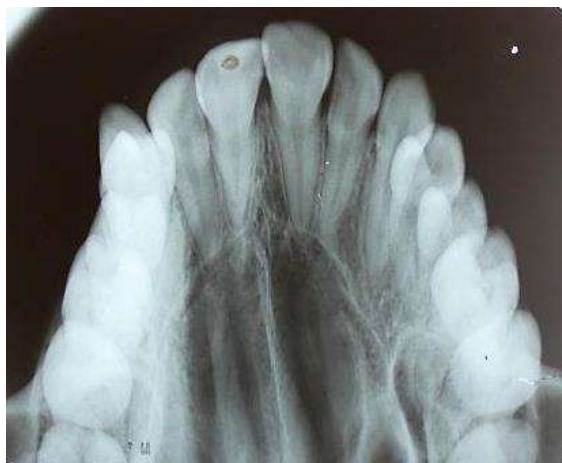

Fig. 4: Buccally impacted canine

### Orthopantomograph (OPG)

Panoramic radiography is a fundamental examination which gives an overview but does not permit precise localization of an impacted canine in three-dimensional space.

In a study conducted by ERICSON and KUROL<sup>11</sup> they concluded that the orthopantomograph was found to be unreliable for the purposes of-

1. Determining the position of a misplaced canine in the dental arch or to the adjacent lateral incisors, and
2. Showing resorption on adjacent teeth.

Its value lies in giving a panoramic view of the mouth before starting orthodontic treatment.

Bayesian network analysis can be applied to the OPG to evaluate the position and judge the degree of canine impaction. In Bayesian network analysis the parameters which are taken into account are alpha angle which is the angle measured between the long axis of the impacted canine and the midline, d-distance: distance between the canine cusp tip and the occlusal plane (from the first molar to the incisal edge of the central incisor), and s-sector: sector where the cusp of the impacted canine is located (sector 1, between the midline and the axis of the central incisor; sector 2, between the axes of the central incisor and the lateral incisor; or sector 3, between the axes of the lateral incisor and the first premolar)<sup>12</sup>.

According to their analysis the values that indicate a favourable canine impaction are as follows –

- Alpha angle -  $\leq 35 \pm 13^\circ$
- Distance -  $15 \pm 4\text{mm}$
- Sector - 3

Values beyond this range indicate an unfavourable impaction.

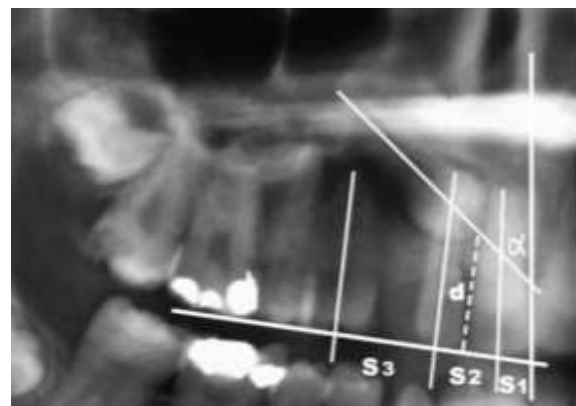
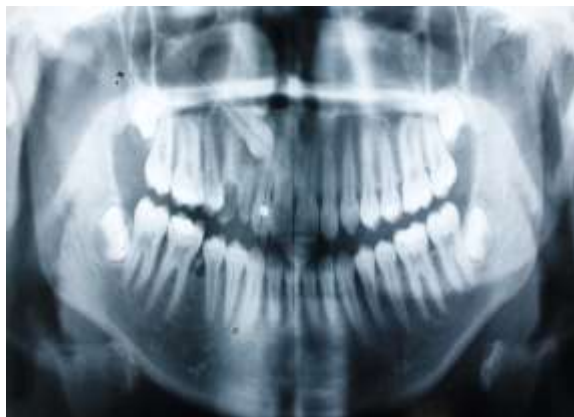

Fig. 5: Bayesian Network analysis



**Fig. 6: Bayesian Network analysis**

In the above shown OPG, the alpha angle is  $55^\circ$ , distance (D) is 21mm and the impacted canine is in sector 2. Hence it is an unfavourable impaction.

### Computed Tomography (CT)

In order to minimize the risk of root resorption of permanent teeth due to impacted canine, an early detection of abnormal contact between the malpositioned canine and the roots of permanent incisors is essential. In this respect, conventional radiographs have proved inadequate. Both conventional radiology panoramic and intra-oral only suggest possible contact between an impacted canine and the permanent incisor when it is located in a true palatal or buccal position relative to the root of adjacent teeth. Several authors have suggested the use of CT in these cases because it is known to be superior to other radiographic methods in showing bony lesions as well as provides accurate 3D localization of canines.<sup>13</sup>

The relative introduction of spiral CT has significantly improved scanning by reducing the examination time and minimizing movement artefacts. Multiple transaxial images can be retrospectively reviewed from a single spiral CT scan data set with varying degrees of overlap, thus optimizing multiplanar reformations with better longitudinal resolution.<sup>14</sup>

Tomography offers greater diagnostic yield, but it is difficult to perform, entails high radiation exposure, and often fails to demonstrate minimal root resorption. The major limitation of CT is radiation risk which is especially greater in children.<sup>13</sup> The average range of radiation exposure for maxilla is 1,031-1,420  $\mu\text{Sv}$ .<sup>15</sup>

### Cone Beam Computed Tomography (CBCT)

The most recognized need for CBCT imaging in orthodontics is that of impacted canine evaluation.

CBCT imaging is precise in determining not only the labial/lingual relationship but also a more exact angulation of the impacted canine. These 3D images are beneficial in determining the proximity of adjacent incisor and premolar roots, which can be invaluable in determining the ease of uncovering and bonding and the

vector of force that should be used to move the tooth into the arch with a lesser chance of damage to adjacent tooth.<sup>16</sup> It also has the potential of providing clear images of highly contrasted structures and is useful in evaluating bone.

CBCT scanners are based on volumetric tomography, using a 2D extended digital array providing an area detector. This is combined with a 3D x-ray beam.<sup>15</sup>

The advantages that the CBCT offers over conventional tomography are<sup>14</sup>:

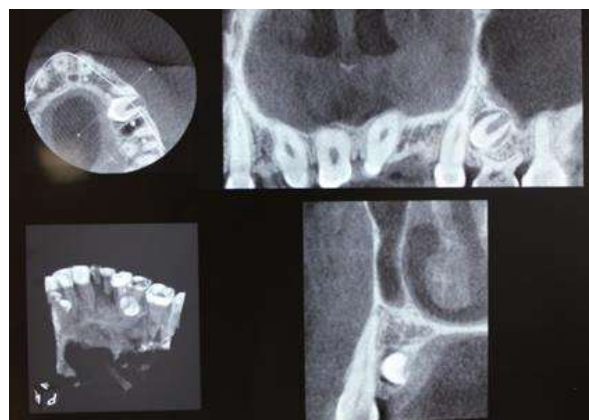
X-ray beam limitation, image accuracy, rapid scan time, dose reduction, display modes unique to maxillofacial imaging and reduced image artefact.

The average radiation dose in CBCT is 36.9 – 50.3  $\mu\text{Sv}$ , that is significantly reduced upto 98% compared to conventional CT.<sup>15</sup>

The analysis that is novel and unique to cbct and helps in aid clinicians to quickly estimate the difficulty of treatment involving impacted canines, without having to do multiple measurements of angles and distances, to relay the approximate treatment plan to the patient<sup>17</sup>.

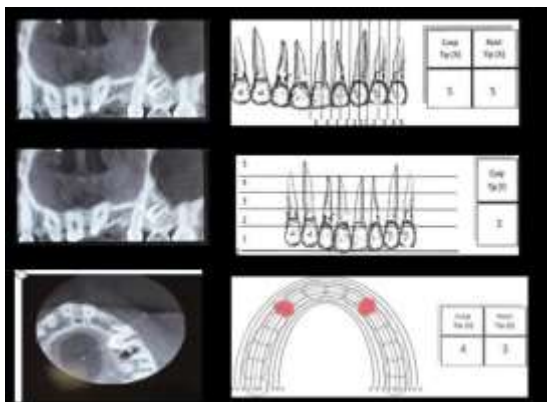
KPG analysis uses a KPG index which is a grid-like scale was devised of the three different views (x, y and z) in order to grade the difficulty of impaction and the potential efficacy of treatment.<sup>17</sup> What makes this analysis unique is the x axis which helps in scoring the canine in the x axis.

Depending on its anatomical location, the cusp tip and the root tip are each given a number on a 0–5 scale on the three separate images taken before treatment. The sum of both cusp tip and root tip scores in the three views would decide the anticipated difficulty of treatment, classified as easy, moderate, difficult, and nearly impossible. Scores in the range 0–9 fall into the category of easy; 10–14 are moderate; 15–19 are difficult; and 20 and above are extremely difficult.<sup>17</sup>



**Fig. 7: CBCT Images**





**Fig. 8: CBCT Images**

In the above given case the scores for KPG analysis are – 20, X Axis -10 (cusp tip-5, root tip-5), Y Axis -3 (cusp tip -3, root tip – 0), Z Axis – 7 (cusp tip- 4, root tip – 3). Hence it is an extremely difficult case.

### Transtomography

Computed tomography and cone beam computed tomography come with a drawback that free-standing conventional tomographic equipment is not readily available outside specialist departments. A few panoramic units on the market are capable of exposing true tomographic images. Such units are dual-purpose units with separate programs and functions for panoramic radiography and tomography.<sup>18</sup>

Transtomography uses a well-established scanning method employing a narrow beam i.e. so called orthoradiographic technique or parallel scanning that is used with several existing digital panoramic units to expose.

By using a narrow beam we increase the magnification and thus minimize the unsharpness but layer thickness becomes very wide. To this simple translational scanning technique one more movement i.e. pendular movement is also added to decrease the layer thickness. But the problem of blurred images still exists to a certain depth.<sup>18</sup>

Transtomography is useful for canine impactions that are not very highly placed and most useful in knowing the relationship between the impacted canine and the root resorption of the lateral incisor.

The value of this useful technology is in the series of options available for exposure. It is thus possible to expose transtomographs employing different tomographic angles, 25°, 10°, 5°, 3.4°, 1.7° and 0.9°, creating nominal layer thicknesses of 1 mm, 3 mm, 6 mm, 9 mm, 18 mm and 36 mm. It is possible to expose cross-sectional or longitudinal transtomographs of any part of the jaws including the temporomandibular joints. Such transtomographs may portray the upper or the lower jaw, or both. It is possible to combine four cross-sectional transtomographs or three cross-sectional and one longitudinal transtomograph in one composite image.<sup>18</sup>

The advantages of this technique over are conventional tomography are low radiation, low cost and the easy availability and use of routine equipment.<sup>19</sup>

### Conclusion

Examination for an impacted canine should be started as early as 10 years in children to save time, complexity and cost of treatment. After careful inspection and palpation radiographic examination should be done in a stepwise program to minimize the total radiation exposure to a patient without losing essential information.

In uncomplicated cases with ectopic eruption, the radiologic examination may be limited to 2 or 3 conventional intraoral films exposed in different projections, this allows reliable assessment of the position and eruption pathway of the canines.

The need for advanced investigations will be determined by the diagnostic problems caused by overlapping and interrupted lamina dura and the risk of resorption.

In cases of ectopic eruption and when therapeutic or prophylactic orthodontic measures are considered, the 2 or 3 films procedure should be supplemented with a film in an axial projection so that the position of the tooth in the dental arch and in relation to adjacent teeth can be assessed more accurately<sup>11</sup>.

Transtomography is a novel method in radiology and it should be adapted in routine practice due to its advantages of low radiation exposure to patient, low cost and the easy availability and use of routine equipment.

### References

1. Rossella Maverna, Antonio Gracco. Different diagnostic tools for the localization of impacted maxillary canines: clinical considerations. *Prog Orthod* 2007;8(1):28-44.
2. Grace Richardson, Kathy A. Russell. A Review of Impacted Permanent Maxillary Cuspid — Diagnosis and Prevention. *Can Dent Assoc* 2000;66:497-501.
3. Peck S, Peck, Kataja, M. The palatally displaced canine as a dental anomaly of genetic origin. *Angle Orthod* 1994;64:249-56.
4. Baccetti T. A controlled study of associated dental anomalies. *Angle Orthod* 1998;68:267-74.
5. Becker A. Palatal canine displacement: guidance theory or an anomaly of genetic origin? *Angle Orthod* 1995;65:95-102.
6. Becker A, Smith P, Behar R. The incidence of anomalous maxillary lateral incisors in relation to palatally displaced cuspids. *Angle Orthod* 1981;51:24-9.
7. Bishara SE. Impacted maxillary canines: a review. *Am J Orthod Dentofac Orthop* 1992;101:159-71.
8. Jacoby M. The etiology of maxillary canine impaction. *Am J Orthod Dentofac Orthop* 1983;84:125-32.
9. Localization of the unerupted maxillary canine: How to and when to Stanley G Jacobs, BDS (Melb), FDSRCS (Eng), DOrthRCS (Eng).
10. Bishara SE. Impacted maxillary canines: a review. *Am J Orthod Dentofacial Orthop* 1992;101:159-71.
11. Ericson S, Kuroi J. Radiographic examination of ectopically erupting maxillary canines. *AM J ORTHOD DENTOFAC ORTHOP* 1987;91:483-92.

12. Michele Nieri, Aldo Crescini, Roberto Rotundo, Tiziano Baccetti, Pierpaolo Cortellini, and Giovan Paolo Pini Prato. Factors affecting the clinical approach to impacted maxillary canines: A Bayesian network analysis. (*Am J Orthod Dentofacial Orthop* 2010;137:755-62).
13. Preda L, La Fianza A, Di Maggio EM, Dore R, Schifino MR, Campani R, et al. The use of spiral computed tomography in the localization of impacted maxillary canines. *Dentomaxillofac Radiol* 1997;26:236-41.
14. Brink JA. Technical aspects of helical(spiral) CT. *Radiol Clin of North America* 1995;33:825-841.
15. William C. Scarfe, Allan G. Farman, Predag Sukovic. Clinical Applications of Cone - Beam Computed Tomography in Dental Practice. *J Cant Dent Assoc* 2006;72(1):75-80.
16. Steven L. Hechler. Cone-Beam CT: Applications in Orthodontics. *Dent Clin N Am* 52 (2008);809–823.
17. Chung How Kau, Philip Pan, Ron L. Gallerano, Jeryl D. English. A novel 3D classification system for canine impactions – the KPG index. *Int J Med Robotics Comput Assist Surg* 2009;5:291–296.
18. U Welander, G Li, WD McDavid and G Tronje. Transtomography: a new tomographic scanning technique. *Dentomaxillofacial Radiology* (2004);33,188–195.
19. M Ashwini Kumar, Bharat Mody, Gopa Kumar R Nair, LR Surender, S Sujatha Gopal, Ravi Varma KA Prasad. Dimensional Accuracy and Details of the Panoramic Cross-sectional Tomographic Images: An in vitro Study. *The Journal of Contemporary Dental Practice*, January-February 2012;13(1):85-97.