

Content available at: <https://www.ipinnovative.com/open-access-journals>

IP Indian Journal of Orthodontics and Dentofacial Research

Journal homepage: <https://www.ijodr.com/>

Case Report

Breaking through mandibular barrier: A case report on orthodontic repositioning of an impacted tooth

Hemwati Nandan^{1*}, Srinivas Gosla Reddy¹, Pragjyoti Jha¹

¹GSR Institute of Craniofacial and Facial Plastic Surgery, Hyderabad, Telangana, India



ARTICLE INFO

Article history:

Received 25-04-2024

Accepted 21-05-2024

Available online 21-06-2024

Keywords:

Guided eruption

Orthodontic repositioning

Impaction of deciduous teeth

Impacted deciduous molar

Impacted premolar

ABSTRACT

Tooth impaction is known to cause various problems such as space loss, tipping of adjacent teeth, super-eruption of the antagonist tooth, and dislocation of the permanent tooth beneath the impacted primary tooth. In this case report, we present the treatment of a 14-year-old female patient who presented with a chief complaint of missing teeth in the lower left back jaw region. OPG finding reveal the exceptional occurrence of simultaneous impact ion involving the primary second molar and its succedaneous teeth—a remarkable rare observation. Based on the CBCT findings, it was revealed that the impacted premolar had ruptured the lower border of the mandible. To address this issue, a comprehensive treatment plan was developed. The treatment plan included the use of a bonded appliance to create space for tooth eruption, followed by surgical removal of the primary molar to provide more room for the impacted premolar. A traction chain was then attached from a fixed orthodontic appliance to the impacted premolar, guiding it into the correct position. Throughout the treatment process, the patient was closely monitored for any signs of discomfort or complications, and necessary adjustments were made to ensure the best possible outcome. The combination of these techniques proved to be effective in achieving successful orthodontic treatment and improved dental health for the patient.

This is an Open Access (OA) journal, and articles are distributed under the terms of the [Creative Commons Attribution-NonCommercial-ShareAlike 4.0 License](https://creativecommons.org/licenses/by-nc-sa/4.0/), which allows others to remix, tweak, and build upon the work non-commercially, as long as appropriate credit is given and the new creations are licensed under the identical terms.

For reprints contact: reprint@ipinnovative.com

1. Introduction

The condition of tooth impaction occurs when a tooth is unable to erupt due to mechanical obstruction and remains unerupted beyond its expected eruption time.¹ Impaction of teeth can occur in two ways: primary and secondary. Primary impaction refers to teeth that never emerge from the jaw and are covered by a layer of intact mucosa. Diagnosis is confirmed by radiographs showing the tooth buried deep within the bone. On the other hand, secondary impaction occurs when teeth that have already erupted become impacted again due to various reasons, such as retained deciduous teeth, odontomas, cystic lesions, or

supernumerary teeth.^{2,3} Impacted primary teeth can lead to several issues, including loss of space, tipping of adjacent teeth, supra eruption of the opposing tooth, and dislocation of the underlying permanent tooth.⁴

Various treatment options are, available for impacted deciduous or permanent teeth, ranging from extraction of the primary tooth followed by monitoring without intervention to monitoring the eruption process under supervision.⁵ Surgical exposure or repositioning with or without orthodontic traction is another treatment option. In certain cases, surgical removal of the impacted permanent tooth may be necessary.⁶ Whenever enucleation is the first treatment of choice for impacted primary teeth, careful evaluation of the inferior alveolar nerve bundle and mental nerve is necessary prior to surgery because this method carries certain risks. Damaging the mental foramen or

* Corresponding author.

E-mail address: hemwatinandanbahuguna@gmail.com (H. Nandan).

inferior dental canal is a possible complication, thus the position of the canal and foramen relative to the tooth should be established beforehand.⁷

If a primary tooth becomes impacted, it may disturb the growth of the dental arch and also cause impaction of the permanent tooth. Therefore, it is essential to identify and treat impacted primary teeth. The current study examined a case of severe impaction of the mandibular second primary molar, in which the impacted premolar was located below the primary molar, leading to mandibular lower border perforation which is very rare.

2. Case Presentation

This report discusses the case of a 14-year-old female patient who presented with a complaint of missing teeth in the lower left back tooth region. The patient had no significant medical or dental history and had not undergone any dental extractions or orthodontic treatment in the past.

Clinical examination revealed retained primary canine, primary first and primary second molars on the right side, and primary second molar on the left side in the maxillary arch. In the mandibular arch, primary first and primary second molars were retained on the right side and second premolar on the left side was missing (Figure 1).

OPG findings showed that all four second premolars were impacted, and the mandibular left first premolar and second molar were tipped toward each other, leading to the failure of the primary second molar to erupt. The second premolar on the mandibular left side was also deeply impacted. To precisely determine the position of the impacted teeth, CBCT was performed, which revealed that the crown of the second premolar was encircled by the root of the primary second molar. Furthermore, the lower border of the mandible was ruptured by the impacted premolar (Figure 2).

To address the issue, a comprehensive treatment plan was developed to create space and facilitate the eruption of the impacted premolar. The first step was to use a bonded appliance to create space in the impacted area by uprighting the second premolar and first molar. However, due to the proximity of the mental nerve to the surgical site, initially we decided not to perform disimpaction of the primary molar. Instead, we attempted active eruption of the primary molar with a lingual button and elastomeric chain. However, the primary molar failed to erupt as it was ankylosed, and so we proceeded with the disimpaction of the primary molar and active eruption of the premolar.

The impacted primary molar was surgically removed to provide more room for the eruption of the impacted premolar. A traction chain was then attached to a fixed orthodontic appliance to guide the impacted premolar into the correct position. Over several months, the traction chain applied a gradual force to the impacted teeth, allowing it to move into the desired location (Figures 3 and 4).

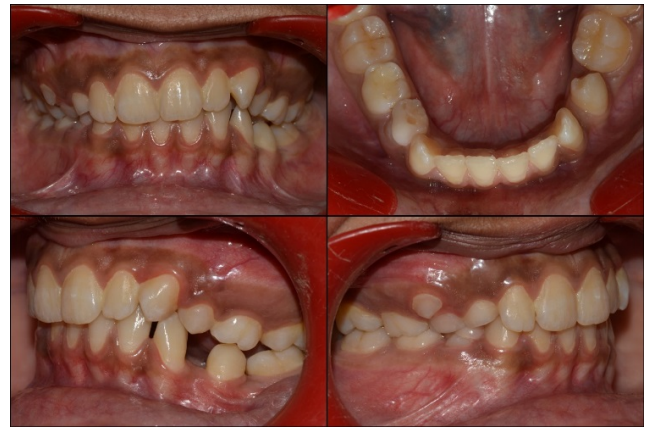

Figure 1: Intra oral photographs

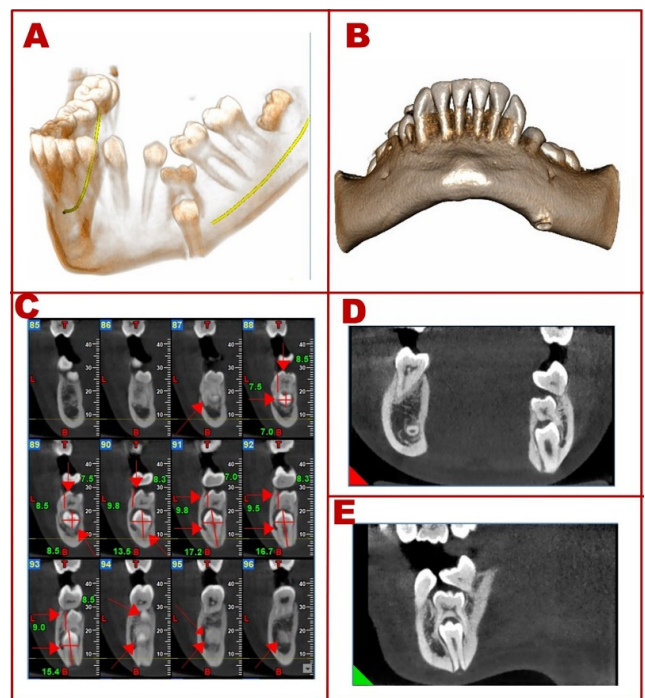


Figure 2: CBCT images depicting the positions of the mandibular premolar; A,B: volumetric frontal view showing the impacted mandibular Premolar is perforating the lower border; C-E: Coronal and Sagittal views showing the position impacted mandibular primary molar and premolar;

However, after the surgical extraction, the patient reported a tingling sensation on the left side of the lower lip, which suggested grade-1 paresthesia. The patient fully recovered from the paresthesia after 6 months. Throughout the entire treatment process, we closely monitored the patient for any signs of discomfort or complications, and adjustments were made as necessary to ensure the best possible outcome. The combination of techniques, including the bonded appliance, tooth extraction, and

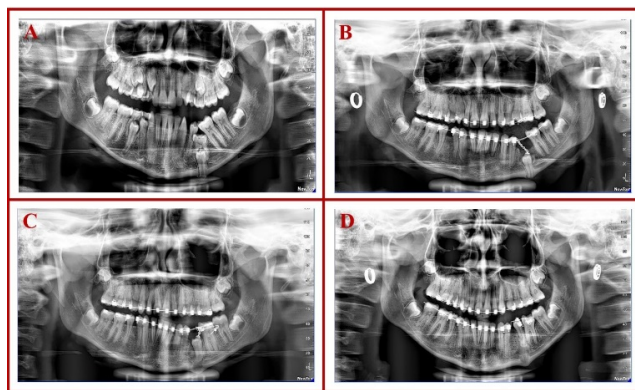


Figure 3: Panoramic radiograph showing orthodontic guided repositioning of impacted teeth

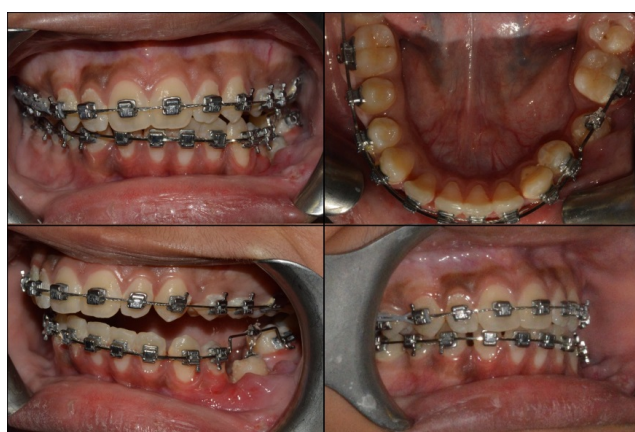

Figure 4: Intra oral photographs showing guided eruption of impacted premolar

traction chain, proved effective in achieving successful orthodontic treatment and improved dental health for the patient.

3. Discussion

Impaction of primary teeth and its succedaneous permanent teeth together is considered to be rare. The process of mandibular premolar eruption occurs in various stages. During the early pre-eruptive phase, successional permanent teeth develop near the occlusal level and lingual to their primary predecessors. Towards the end of this phase, premolars are positioned under the roots of primary molars. The change in tooth germ position is not primarily due to the apical movement of permanent tooth germs but rather the eruption of primary teeth and the simultaneous increase in the height of supporting tissues.⁸

Third molars are the most commonly impacted teeth, followed by maxillary canines and then premolars. Research on impacted premolars is limited and not extensive. The prevalence of impacted premolars is approximately

1% among ethnic Chinese in Hong Kong and a recent study conducted on a North Greek population found that 2.2% of the population had impacted premolars, with the second mandibular premolars being the most frequently affected, followed by the second maxillary premolars.^{9,10} An Indian population study found that tooth impaction had a prevalence of 16.8%, which falls within the range of 5.6- 18.8% as reported in earlier studies.¹¹ The prevalence of impacted premolars has been found to vary based on age. The overall prevalence in adults has been reported to be 0.5%, with maxillary premolars ranging from 0.1-0.3%, and mandibular premolars ranging from 0.2-0.3%. These discrepancies in prevalence rates may be attributed to genetic and ethnic differences among patients.¹² Similarly, the case report describes an impacted mandibular primary second molar, which is in line with previous studies. However, the impaction of primary teeth with impacted permanent teeth causing perforation of the mandible's lower border has been rarely reported to date.

There are various reasons why premolars may become impacted, and these can be attributed to either local or systemic factors. Local factors include the lack of space in the jaw, premature loss of primary molars leading to mesial drift of teeth, and abnormal or ectopic positioning of the developing premolar tooth buds. Inflammatory or pathological conditions, like dentigerous cysts, can also contribute to impaction. Genetic and environmental factors may also play a role in the development of impacted premolars.¹³ When premolars become impacted, it can result in aesthetic problems, difficulties in chewing food properly and maintaining oral hygiene. It can also lead to follicle pathology and damage to nearby structures, such as adjacent teeth.¹⁴

Proper radiographic examinations are important for planning the surgical procedure in cases of impacted teeth. A study has shown that these radiographic techniques can help visualise the morphological changes in impacted teeth and their relationship with neighbouring structures, aiding in diagnosis and surgical planning. Periapical, occlusal and panoramic radiographs are the most commonly recommended techniques, although they may not provide a complete 3D view of all structures in the region due to overlapping anatomical structures.¹⁵ When it comes to the placement and proximity of an impacted tooth, specific radiographic procedures may be necessary. Cone-beam CT (CBCT) is a valuable method for evaluating impacted teeth and is frequently utilized in place of, or in conjunction with, traditional techniques. Research indicates that CBCT is preferred due to its benefits, which include comprehensive visualization of the area and less radiation exposure for the patient when compared to helical tomography. As a result, CBCT enables the exact location of the tooth to be determined and permits the relationships between it and neighbouring structures to be established through

multiplanar views.¹⁶

There are several treatment options available for impacted teeth, including observation, intervention, relocation, and extraction. These treatment options may sometimes be combined with each other to achieve the best outcome. Observation requires monitoring the patient's condition without any active treatment but with regular clinical and radiographic check-ups.¹⁷ Intervention options may include the removal of one or more teeth, typically primary teeth. In some cases, extraction of a permanent tooth may be necessary depending on the underlying cause of the impaction and the specific tooth affected. Intervention might consist of a short course of orthodontic therapy aimed at resolving the impaction. Relocation can refer to either surgical repositioning of an impacted tooth or more commonly, orthodontic eruption of the tooth. Orthodontic relocation may take more treatment time but has fewer or no complications.⁵ Kokich,¹⁸ discusses the surgical and orthodontic approaches for managing impacted teeth in his study. According to Kokich, the prognosis and treatment outcome of impacted teeth are influenced by various critical factors such as the position and angulation of the impacted tooth, treatment duration, keratinized tissue and spacing.

When choosing a suitable treatment option for an impacted premolar, various factors should be taken into account, including the cause of the impaction, the amount of space required, whether primary molars need to be extracted, the severity of the impaction, and the stage of root formation. Other factors such as the patient's medical history, dental health, oral hygiene, functional and occlusal relationships, as well as their attitude and willingness to follow through with the treatment, will also impact the selection of treatment options.¹⁹

Our patient experienced two complications during the course of treatment: minor tissue swelling at the surgical site and grade-I paresthesia. The swelling resolved within four to five days, while the paresthesia took six months to fully resolve. Despite these challenges, the treatment was ultimately successful in achieving the desired outcome.

4. Conclusions

Rarely does an impacted tooth perforate the lower border of the mandible, but this case report demonstrates that even in unfavourable circumstances, impacted mandibular premolars can be successfully treated using a multidisciplinary approach. Surgical success is achievable through a thorough understanding of regional anatomy, precise tissue manipulation, and correct mechanical principles during tooth extractions. This exceptional and infrequent case adds to the limited literature on impacted second premolars and suggests orthodontic treatment as a viable alternative in similar scenarios.

5. Source of Funding

None.

6. Conflict of Interest

None.


References

1. Yildirim‑Oz G, Tosun G, Kiziloglu D, Durmuş E, Sener Y. An Unusual Association of Odontomas with Primary Teeth. *Eur J Dent.* 2007;11(1):45–9.
2. Winter GB, Gelbier MJ, Goodman JR. Severe Infra-occlusion and failed eruption of deciduous molars associated with eruptive and developmental disturbances in the permanent dentition: a report of 28 selected cases. *Br J Orthod.* 1997;24(2):149–57.
3. Hashim HA, Al-Qahtani AA, Taha SM, Tharupeedikayil S, Ahmed MF. Management of complete impacted maxillary second deciduous molar with the aid of cone-beam computed tomography: Case report and a review of the literature. *J Orthod Sci;*2(4):130–5.
4. Altay N, Cengiz SB. Space-regaining treatment for a submerged primary molar: A case report. *Int J Paediatr Dent.* 2002;12(4):286–9.
5. Frank CA. Treatment options for impacted teeth. *J Am Dent Assoc.* 2000;131(5):623–32.
6. Murray P, Brown NL. The conservative approach to managing unerupted lower premolars- Two case reports. *Int J Paediatr Dent.* 2003;13(3):198–203.
7. Cobourne MT, Brown JE, McDonald F. Analysis of the morbidity of submerged deciduous molars: the use of imaging techniques. *Oral Surg Oral Med Oral Pathol Oral Radiol Endod.* 2002;93(1):98–102.
8. Avery JK. Oral Development and Histology. New York, NY, USA: Thieme Medical Publishers; 2002.
9. Chu FCS, Li TKL, Lui VKB, Newsome PRH, Chow RLK, Cheung LK, et al. Prevalence of impacted teeth and associated pathologies-a radiographic study of the Hong Kong Chinese population. *Hong Kong Med J.* 2003;9(3):158–63.
10. Fardi A, Kondylidou-Sidira A, Bachour Z, Parisis N, Tsirlis A. Incidence of impacted and supernumerary teeth-a radiographic study in a North Greek population. *Med Oral Patol Oral Cir Bucal.* 2011;16(1):56–61.
11. Patil S, Maheshwari S. Prevalence of impacted and supernumerary teeth in the North Indian population. *J Clin Exp Dent.* 2014;6(2):116–20.
12. Şimşek-Kaya G, Melih-Ömezli M, Yapici G, Dayi E, Ertaş U. Prevalence of impacted premolars in a Turkish population and considerations for surgical treatment. *Med Oral Patol Oral Cir Bucal.* 2011;16(6):781–6.
13. Ishihara Y, Kamioka H, Yamamoto TT, Yamashiro T. Patient with nonsyndromic bilateral and multiple impacted teeth and dentigerous cysts. *Am J Orthod Dentofacial Orthop.* 2012;141(2):228–41.
14. McNamara C, McNamara TG. Mandibular premolar impaction: 2 case reports. *J Can Dent Assoc.* 2005;7(11):859–63.
15. Haney E, Gansky SA, Lee JS, Johnson E, Maki K, Miller AJ, et al. Comparative analysis of traditional radiographs and cone-beam computed tomography volumetric images in the diagnosis and treatment planning of maxillary impacted canines. *Am J Orthod Dentofacial Orthop.* 2008;137(5):590–7.
16. Quereshy FA, Savell TA, Palomo JM. Applications of cone beam computed tomography in the practice of oral and maxillofacial surgery. *J Oral Maxillofac Surg.* 2008;66(4):791–6.
17. Rubin DM, Vedrenne D, Portnof JE. Orthodontically guided eruption of mandibular second premolar following enucleation of an inflammatory cyst: case report. *J Clin Pediatr Dent.* 2002;27(1):19–23.
18. Kokich VG, Mathews DP. Surgical and orthodontic management of impacted teeth. *Dent Clin North Am.* 1993;37(2):181–204.

19. Jain U, Kallury A. Conservative Management of Mandibular Second Premolar Impaction. *People's J Sci Res*. 2011;4(1):59–62.

Pragjyoti Jha, Consultant

Author biography

Hemwati Nandan, Consultant  <https://orcid.org/0000-0003-1874-6321>

Srinivas Gosla Reddy, Director

Cite this article: Nandan H, Reddy SG, Jha P. Breaking through mandibular barrier: A case report on orthodontic repositioning of an impacted tooth. *IP Indian J Orthod Dentofacial Res* 2024;10(2):124-128.