



Case Report

Ortho-surgical management of skeletal class III malocclusion: A case report

Binu Purushothaman¹, Amrutha Krishnan¹, Naseem Keeranthodika¹,
Indu Nambiar^{1*}, Aswathi Kandath¹, Muhammed Fairooz¹

¹KMCT Dental College, Kozhikode, Kerala, India



ARTICLE INFO

Article history:

Received 19-04-2024

Accepted 03-06-2024

Available online 21-06-2024

Keywords:

Skeletal class III malocclusion

Orthognathic surgery

Concave profile

ABSTRACT

18-year-old female, presented with c/c of forwardly placed lower jaw. Extraorally, the patient had a symmetrical face and concave profile, competent lips, positive lip step, and obliterated mentolabial sulcus. Intraorally, the patient had Angle's class III malocclusion with an overjet of (–5) mm, overbite of 0%, and cross-bite with respect to 15,12, 11, 21, 22 and upper and lower midline shift. The patient was skeletal class III due to prognathic mandible with hypodivergent growth pattern, and proclined upper and lower incisors. The patient was managed ortho-surgically with bijaw surgery (maxillary advancement 4mm + mandibular setback 7 mm) after presurgical decompensation. This case report discusses in detail the diagnosis and comprehensive management of the skeletal class III case.

This is an Open Access (OA) journal, and articles are distributed under the terms of the [Creative Commons Attribution-NonCommercial-ShareAlike 4.0 License](https://creativecommons.org/licenses/by-nc-sa/4.0/), which allows others to remix, tweak, and build upon the work non-commercially, as long as appropriate credit is given and the new creations are licensed under the identical terms.

For reprints contact: reprint@ipinnovative.com

1. Introduction

Human physical attractiveness is determined by a harmonious facial profile. Ideal beauty may be deteriorated in case of skeletal disharmony, occlusal problems, and soft tissue strain. Even though the concept of beauty has changed over the centuries and differs from one population to another, it has always been a subject of interest and importance to people of all cultures.^{1–5}

Dentofacial deformities cause an alteration in the relation between the maxilla and mandible, resulting in compromised function and aesthetics. Skeletal class III malocclusion requires prompt attention once diagnosed. It may be due to retrognathic maxilla, prognathic mandible, or a combination of both. The possible therapeutic options to manage dentoskeletal discrepancies are early modification of growth, orthodontic camouflage through dental compensation, or orthodontic and surgical repositioning of the jaw bases.

This case report presents the treatment of an adult girl with class III skeletal discrepancy by combined ortho-surgical management.

2. Case Report

A female patient, 18 years of age presented with a chief complaint of forwardly placed lower jaw.

Extra oral examination revealed mesocephalic head with leptoprosopic facial type, concave profile with anterior divergence, acute nasolabial angle, deficient midface, competent lips, obliterated mentolabial sulcus, average nose and increased lower anterior facial height.

Intraorally, molar relation and canine relation were observed to be class III bilaterally. Upper anteriors were in crossbite with a reverse overjet of 5mm. Crossbite was also present in relation to 15. Upper midline was shifted to right by 1mm and lower midline was shifted to right by 2mm. Both arches were U-shaped with mesiopalatally rotated 13, 15 and mesiolingually rotated 32, 42 (Figure 1).

* Corresponding author.

E-mail address: indunambiar13@gmail.com (I. Nambiar).

2.1. Pre-treatment radiographic assessment

The patient was skeletal class III with micrognathic and prognathic mandible. The patient had a hyperdivergent growth pattern. (Table 1) The maxillary and mandibular anterior teeth were proclined. Orthopantomogram (OPG) showed unerupted 18, 28, 38, and 48 (Figure 2).

2.2. Diagnosis

Angles class III malocclusion on a class III skeletal base with prognathic mandible, retrognathic maxilla, proclined upper and lower anteriors, multiple rotated teeth, crossbite in 15, upper and lower midline shift to right on an average growth pattern individual.

2.3. Problem list

1. Concave profile
2. Class III skeletal pattern
3. Reverse overjet of 5 mm
4. Molar and canine relationship
5. Crossbite in relation to 15
6. Mesiopalatally rotated: 15,13
7. Mesiolingually rotated: 32,42
8. Midline shift

2.4. Treatment plan

After discussing the treatment options with the patient, the treatment was planned to be a combined ortho-surgical approach. Presurgical orthodontics was planned to gain negative overjet. Bijaw surgery (LeForte I maxillary advancement 4 mm + BSSO mandibular setback 7 mm) was decided.

2.5. Treatment progress

The treatment commenced with extraction of 18, 28, 38, 48 and fixed orthodontic treatment for decompensation with MBT prescription 0.022*0.028 brackets. Archwire progressed sequentially from 0.014, 0.018, 0.016*0.022, 0.017*0.025 NiTi wires to 0.018, 0.017*0.025, 0.019*0.025 SS wires. Class II elastics were used for retraction of maxillary incisors and proclination of mandibular incisors. Opencoil spring was engaged between 41 and 43 for aligning 42. Decompensation was complete with a negative overjet of 7 mm after 12 months of treatment (Figure 3).

Pre-treatment lateral cephalogram was digitized and evaluated on CTARS software. The treatment simulation was done with 4 mm anterior sagittal movement of maxilla and 7 mm mandibular setback (Figure 4).

2.6. Presurgical mock surgery

Facebow transfer was done and the relationship of FH plane to maxilla was recorded to the semiadjustable articulator.

Wax bite in occlusion was taken to fix the mandibular model. Horizontal lines at a distance of 10 mm were drawn parallel to occlusal plane. Vertical lines were drawn passing through mesio-buccal cusp of second molars, cusp tip of canines and midline. Maxilla was advanced 4 mm with reference to the horizontal and vertical lines. Intermediate acrylic splint was formed at this position. Another pair of models were articulated in the final position after mandibular set back and final splint was prepared.

2.7. Surgical phase

BSSO setback and Lefort 1 advancement under GA were performed. Vestibular incision placed 5mm above the mucogingival junction of maxilla extending from 17 to 27. Lefort I osteotomy done and maxillary advancement of 4mm using interim splint was done. Fixation was done using 2* 8 mm titanium plate and screw.

For mandible, incision was placed over anterior border of ramus to mesial aspect of first molar bilaterally. BSSO done and osteotomised segment repositioned (7mm setback) using splint. Maxillomandibular stabilization was done using intermaxillary elastics. Haemostasis and suturing were performed.

2.8. Post-surgical management

Bijaw surgery (maxillary advancement 4 mm + mandibular setback 7 mm) was done. Patient was instructed to wear class III elastics to prevent any relapse post surgically for 6 weeks. Diagonal elastics were given from 23 to 43. In the finishing stage, repositioning of brackets was done, and vertical settling elastics were given.

2.9. Post-treatment assessment

The patient had an ideal overjet and overbite of 2 mm, and nearly concordant midlines post-treatment. The case was finished in class I molar relation, class I incisor, class I canine, and premolar relation and canine guided occlusion (Figure 5). Desirable root parallelism was achieved (Figure 6).

The ANB was improved from -5° to $+1^\circ$ and Wits changed from -8mm to -4mm , thus showing marked improvement in skeletal class III malocclusion. Maxillary incisor inclination changed from 34° to 31° (Table 2).

Figure 7 shows intra-oral photographs with fixed lingual retainers and Begg wrap-around retainers in both upper and lower arch.

3. Discussion

Despite oral and maxillofacial surgery being traumatic and invasive, many patients opt the treatment not only to improve function but also for esthetic improvements in the smile or face. It offers the benefits of improving the self-

Table 1: Pre treatment cephalometric values

Measurement	Mean	Pre-treatment
Maxilla		
SNA	82 ± 2°	85
Na per to Pt A	0-1 mm	0 mm
Co to Pt A		78 mm
Mandible		
SNB	80±2°	90°
Na per Pog	-8 to -6mm	8 mm
Co-Gn		113 mm
Max-mand relation		
ANB	2°	-5
WITS		BO ahead of AO by 8 mm
McNAMARA diff		35 mm
Vertical		
FMA	25 ± 3°	27°
SN to Go-Gn	31°	29°
Sum of posterior angles	396±4°	392°
Jarabak ratio	62-65	64%
Dental		
U1 to N-A (angle)	22°	34°
U1 to N-A (mm)	4mm	7mm
U1 to SN	102°	117°
L1 to N-B (mm)	4mm	7mm
L1 to N-B (angle)	25°	30°
L1 to A-Pog (mm)	1-2mm	8mm
L1 to A-Pog (angle)	22°	34°
Interincisal angle	131°	122°
IMPA	90°	88°
U6 to PtV	17 ± 3 mm	23mm
Soft tissue		
E line to lower lip	-2 to 2mm	0 mm
S line to upper lip	0mm	3 mm
S line to lower lip	-2mm	4 mm
Nasolabial angle	102 +8	83°

Table 2: Post treatment cephalometric values

Measurement	Mean	Post treatment
Maxilla		
SNA	82 ± 2°	87
Na per to Pt A	0-1 mm	5mm
Co to Pt A		80mm
Mandible		
SNB	80±2°	86°
Na per Pog	-8 to -6mm	12 mm
Co-Gn		105mm
Max-Mand Relation		
ANB	2°	1
WITS		BO ahead of AO by 4mm
McNAMARA diff		25 mm
Vertical		
FMA	25 ± 3°	23°
SN to Go-Gn	31°	26°
Sum of posterior angles	396±4°	390°
Jarabak ratio	62-65	69.6%
Dental		
U1 to N-A (angle)	22°	31°
U1 to N-A (mm)	4mm	7mm
U1 to SN	102°	118°
L1 to N-B (mm)	4mm	6mm
L1 to N-B (angle)	25°	27°
L1 to A-Pog (mm)	1-2mm	5mm
L1 to A-Pog (angle)	22°	30°
Interincisal angle	131°	121°
IMPA	90°	88°
U6 to PtV	17 ± 3 mm	26
Soft Tissue		
E line to lower lip	-2 to 2mm	0mm
S line to upper lip	0mm	1 mm
S line to lower lip	-2mm	2 mm
Nasolabial angle	102 +8	92°

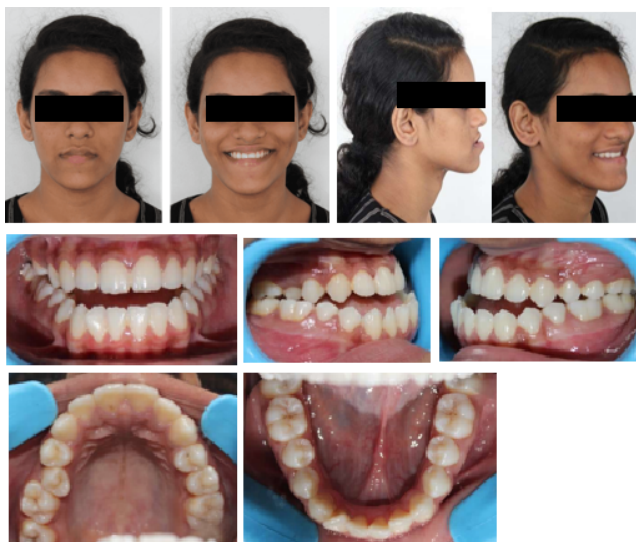

Figure 1: Pre-treatment extra oral and intraoral photographs

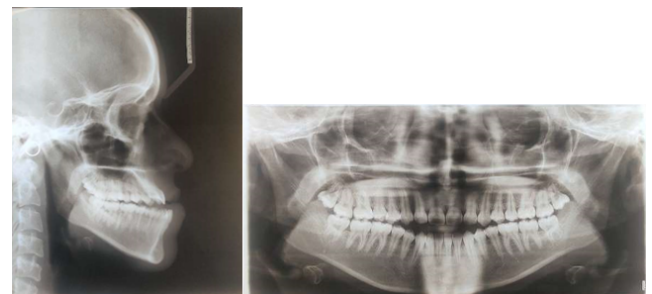


Figure 2: Pre-treatment lateral cephalogram and orthopantomogram

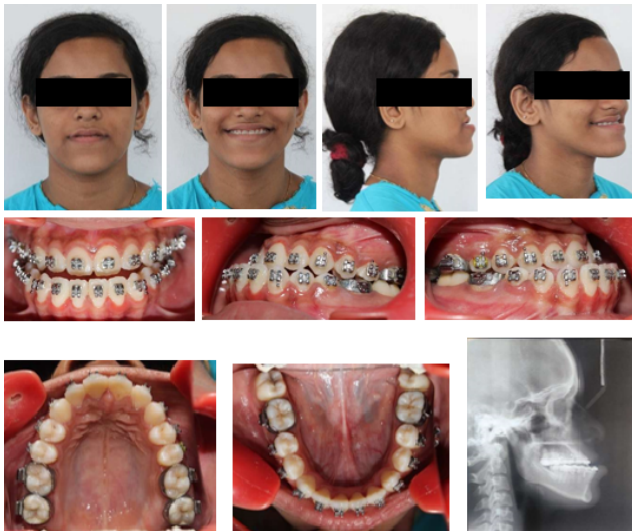

Figure 3: Extraoral and intraoral photographs and lateral cephalogram after presurgical orthodontics

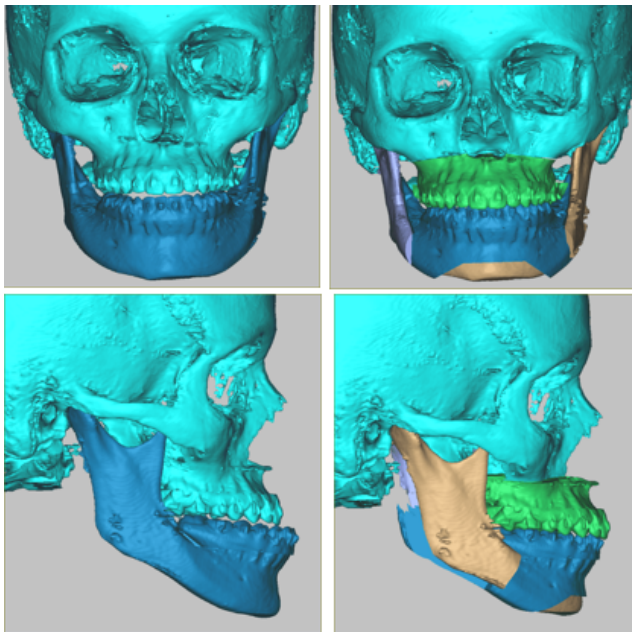


Figure 4: CTARS software simulation showing 4mm maxillary advancement and 7mm mandibular set back

esteem, satisfaction, self-confidence, social functioning, and interpersonal relationships of patients.⁶ Therefore, this case report aims to create an awareness among patients on the vast possibilities of the multidisciplinary approach by orthognathic surgery combined with orthodontics.

Skeletal class III patients may be surgically corrected with maxillary advancement, mandibular setback or a combination of both. The type of surgery to be performed will depend on the site, the amount of discrepancy, and also facial aesthetics.⁷ Many times, maxillary advancement is

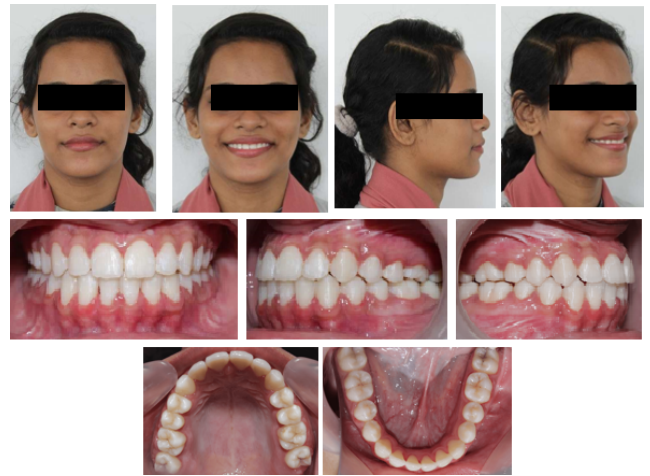

Figure 5: Post treatment extraoral and intraoral photographs

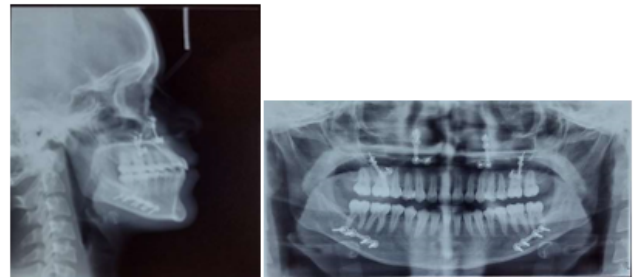


Figure 6: Post treatment lateral cephalogram and orthopantomogram

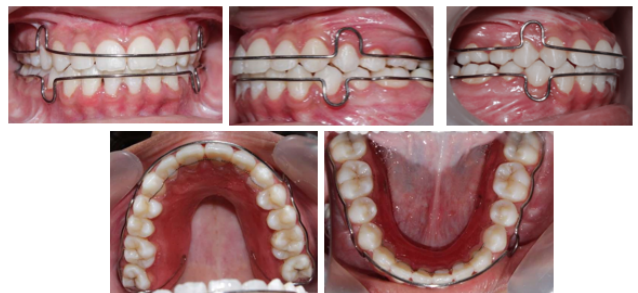

Figure 7: Retention

chosen based on the probability of potential impairment of airways.

The literature on the effects of orthognathic surgery on airway space improvement is controversial. In a study conducted by Azavedo et al,⁸ it was concluded that maxillary advancement and mandibular setback surgery induced a slight increase in upper airway volume, although the difference was not statistically significant. In contrast to this, Park et al⁹ found no difference in the total volume of airways, although they did find a decrease in the oropharyngeal region.

When upper and lower portions of the airways were separately evaluated in similar studies, it was found that advancing the maxilla enlarged the upper airway while mandibular setback reduced the lower airway, as a compensatory process.¹⁰ This fact justifies the bimaxillary surgical procedures undertaken even though the maxilla appeared to be orthognathic in the present case.

3.1. Critical appraisal

1. An orthognathic profile was achieved with surgical treatment that addressed the skeletal malocclusion and the concave profile of the patient.
2. The parallelism of roots was achieved.
3. Upper incisor proclination could have been corrected by extraction of premolars.
4. Midline shift could have been corrected.

4. Patient's Consent

The patient's consent has been obtained for reproducing her photographs.

5. Ethical Clearance

Not applicable.

6. Conflicting of Interests

The authors declared no potential conflicts of interest with respect to the research, authorship, and/or publication of this article.

7. Source of Funding

The authors received no financial support for the research, authorship, and/or publication of this article.


References


1. Powell N, Humphreys B. Proportions of the aesthetic face. Thieme-Stratton; 1984.
2. Giddon DB. Orthodontic applications of psychological and perceptual studies of facial esthetics. *Semin Orthod.* 1995;1(2):82–93.
3. Kamat NV, Chandra PK, Godinho A. Ortho-Surgical Management of Class III Malocclusion in Identical Twins - Case Report. *J Indian Orthodontic Soc.* 2009;43(1):23–39.
4. Gupta RK, Tikku T, Khanna R, Gupta H, Srivastava K, Verma SL, et al. Ortho-surgical management of skeletal Class III malocclusion.

Natl J Maxillofac Surg. 2015;6(1):110–4.


5. Mendiratta A, Mesquita A, Kamat NV, Dhupar V. Orthosurgical Management of a Severe Class III Malocclusion. *J Ind Orthod Soc.* 2014;48(4):273–9.
6. Ashton-James CE, Chemke-Dreyfus A. Can orthognathic surgery be expected to improve patients' psychological well-being? The challenge of hedonic adaptation. *Eur J Oral Sci.* 2019;127(3):189–95.
7. Boeck EM, Lunardi N, Pinto AS, Pizzol K, Boeck RJN. Occurrence of skeletal malocclusions in Brazilian patients with dentofacial deformities. *Braz Dent J.* 2011;22(4):340–5.
8. Azevêdo MS, Machado AW, Ida SB, Esteves LS, Rocha V, Bittencourt MA, et al. Evaluation of upper airways after bimaxillary orthognathic surgery in patients with skeletal Class III pattern using cone-beam computed tomography. *Dental Press J Orthod.* 2016;21(1):34–41.
9. Panou E, Motro M, Ates M, Acar A, Erverdi N. Dimensional changes of maxillary sinuses and pharyngeal airway in Class III patients undergoing bimaxillary orthognathic surgery. *Angle Orthod.* 2013;83(5):824–31.
10. Lee Y, Chun YS, Kang N, Kim M. Volumetric changes in the upper airway after bimaxillary surgery for skeletal Class III malocclusions: a case series study using 3-dimensional cone-beam computed tomography. *J Oral Maxillofac Surg.* 2012;70(12):2867–75.


Author biography


Binu Purushothaman, Professor and HOD  <https://orcid.org/0000-0002-5975-4937>

Amrutha Krishnan, Former Post Graduate Student  <https://orcid.org/0000-0002-3916-0162>

Naseem Keeranthodika, Professor  <https://orcid.org/0000-0003-2194-3270>

Indu Nambiar, Post Graduate Student  <https://orcid.org/0000-0001-6629-6156>

Aswathi Kandoth, Post Graduate Student  <https://orcid.org/0000-0002-5208-6948>

Muhammed Fairooz, Post Graduate Student  <https://orcid.org/0000-0002-4506-1814>

Cite this article: Purushothaman B, Krishnan A, Keeranthodika N, Nambiar I, Kandoth A, Fairooz M. Ortho-surgical management of skeletal class III malocclusion: A case report. *IP Indian J Orthod Dentofacial Res* 2024;10(2):114–118.