

Content available at: <https://www.ipinnovative.com/open-access-journals>

IP Indian Journal of Orthodontics and Dentofacial Research

Journal homepage: <https://www.ijodr.com/>

## Case Report

# Enhancing the aesthetics with anterior deep bite correction: A case report

Shruti Verma<sup>1\*</sup>, Deveshi Nigam<sup>1</sup>, Chaitra Ravishankar Telgi<sup>1</sup>, Seema Chaudhary<sup>1</sup>,  
Naveen Manuja<sup>1</sup>, Ashish Amit Sinha<sup>1</sup>

<sup>1</sup>Dept. of Pediatric and Preventive Dentistry, Kothiwal Dental College & Research Centre, Moradabad, Uttar Pradesh, India



### ARTICLE INFO

#### Article history:

Received 18-12-2023

Accepted 23-01-2024

Available online 04-04-2024

#### Keywords:

Deep bite

Extrusion

Anterior bite plane

Fixed orthodontics

### ABSTRACT

One of the most challenging orthodontic treatment scenarios is deep bite. Anterior bite plane can be used to facilitate the extrusion of posterior teeth and intrusion of incisors in growing individuals, as a part of deep bite correction strategy. This clinical case report is of a 16-year-old female patient with anterior deep bite and crowding. With combined approach of anterior bite plane placement and fixed orthodontics both improved aesthetics as well as functions were achieved.

This is an Open Access (OA) journal, and articles are distributed under the terms of the [Creative Commons Attribution-NonCommercial-ShareAlike 4.0 License](https://creativecommons.org/licenses/by-nc-sa/4.0/), which allows others to remix, tweak, and build upon the work non-commercially, as long as appropriate credit is given and the new creations are licensed under the identical terms.

For reprints contact: [reprint@ipinnovative.com](mailto:reprint@ipinnovative.com)

## 1. Introduction

One of the hardest malocclusions to correct with orthodontics is deep bite, which occurs when the maxillary incisors overlap the mandibular incisors more than the typical coverage of 30% to 40%, or 2-4 mm.<sup>1</sup> Based on population-based research carried out in China, Korea, Malaysia, India, and other Middle Eastern countries, the estimated prevalence of deep bite cases in Asian population is 23.83%.<sup>2</sup> Skeletal or dentoalveolar causes, or both, may be the cause of a deep bite.

Dentoalveolar variables that result in deep bites typically have an association with either over- or under-eruption of the anterior or posterior teeth.<sup>3</sup> Short anterior lower facial heights, flat mandibular plane angles, decreased gonion angles, severe overjets, supraocclusion of incisors, infraocclusion of molars, and deep Spee curves are among the clinical traits of people with deep bites.<sup>4</sup> Treatment for short lower face height is challenging because it is a skeletal issue.

A deep overbite can be treated using a variety of therapeutic techniques, but it needs to be diagnosed carefully. The patient's age, the cause of the deep bite, the skeletal and dental morphology, the vertical dimension, how the teeth relate to the surrounding soft tissue structures, the length of the lip, and the occlusal plane all influence the treatment option.<sup>5,6</sup> Anterior bite plane are reported to be beneficial in treating deep bites in growing patients by permitting molar eruption.<sup>7</sup> This case report presents the treatment of a growing patient with a deep bite using an anterior bite plane in conjunction with a fixed orthodontics.

## 2. Case Report

A 16-year-old female patient reported to the department of paediatric dentistry with the chief complaint of irregular front teeth (Figure 1) since last 4 years.

Intraoral examination revealed Class I molar relationship (right and left) with Type 1 Dewey modification (anterior crowding) (Figure 3 a, b). Palatally tilted left central incisor (21) (Figure 1), V shaped maxillary arch, U shaped mandibular arch and lower anterior crowding. The patient's oral hygiene was fair. A panoramic radiograph revealed

\* Corresponding author.

E-mail address: [verma.drshruti03@gmail.com](mailto:verma.drshruti03@gmail.com) (S. Verma).

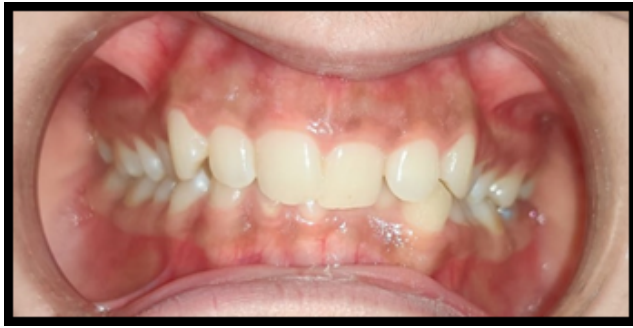

Figure 1: Frontal view



Figure 2: a) Left profile, b) Front profile, c) Right profile

adequate levels of alveolar bone. All permanent teeth were present, except for the third molars.

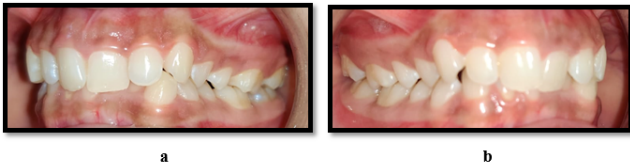

Figure 3: a) occlusion on left side b) occlusion on right side

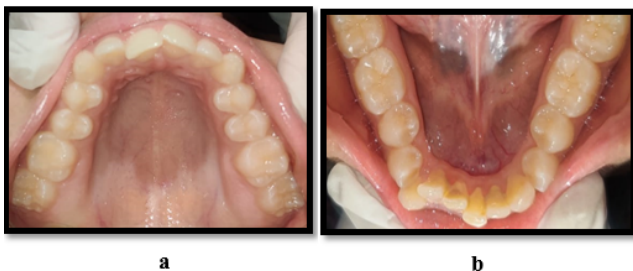

Figure 4: a) Maxillary arch, b) Mandibular arch

Cephalometric analysis confirmed Class II skeletal malocclusion with a retrognathic mandible ( $ANB = 5.5^\circ$ ). The incisor inclination was retroclined in both the upper and the lower jaws (Figure 5 a). Facial growth was favorable. There were no signs of a temporomandibular joint disorder (Figure 5 b).

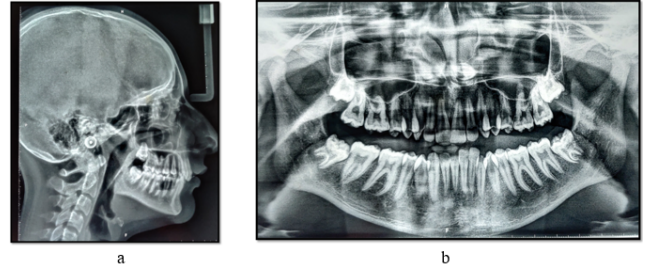


Figure 5: a) Lateral Cephalogram, b) Orthopantomogram

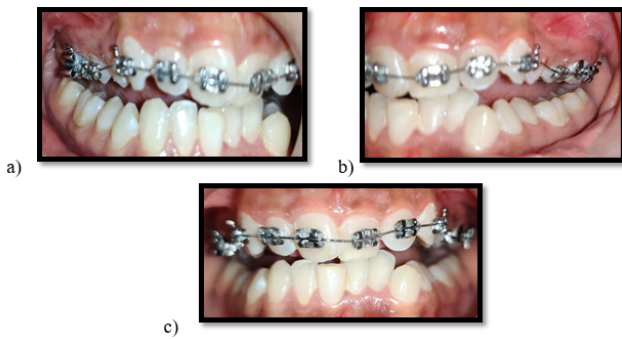
Therefore, the final diagnosis of a female patient having class I molar relation on both left and right side, with palatally inclined upper left central incisor, presence of crowding in mandibular anterior region, with presentation of deep bite of deep bite was made.

The treatment objectives in this case were to establish a Class I canine relationship, relieve crowding on both arches, achieve an ideal overbite and overjet, and level the curve of Spee. First step was a complete oral prophylaxis of the patient since the deep bite had been causing impingement of upper anteriors on to the buccal surface of the gingiva of lower anteriors resulting in fair oral hygiene. The patient was then treated using a fixed anterior bite plane along with fixed orthodontic treatment (Figures 6 and 7 a-c).

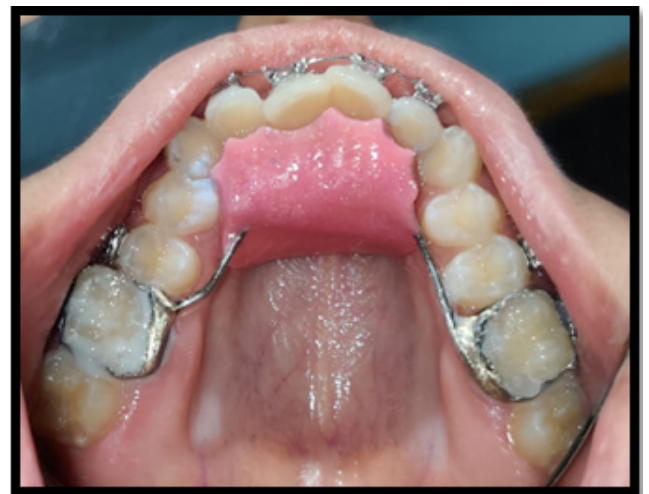

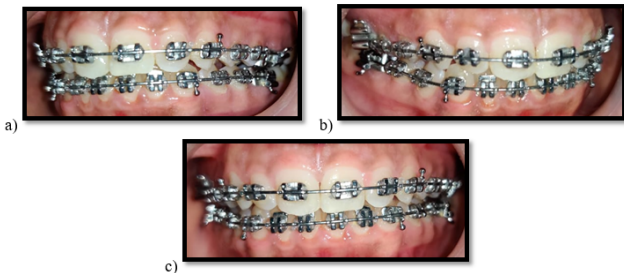
Figure 6: Fixed Anterior Bite Plane along with fixed orthodontic treatment in maxillary arch

On the lower arch, brackets were placed later followed by space gaining by proximal stripping of the lower incisors.



**Figure 7:** Bracket placement in maxillary arch a) Right side b) Left side c) Front view

At the beginning of the treatment, we fixed the anterior bite plane so that the alignment process could take place simultaneously. The wire sequence for aligning process was 0.014, 0.016, 0.016 × 0.022, and 0.017 × 0.025-inch nickel–titanium wires (Figure 8 a-c).



**Figure 8:** Aligning of the maxillary and mandibular arches a) left side b) right side c) front view

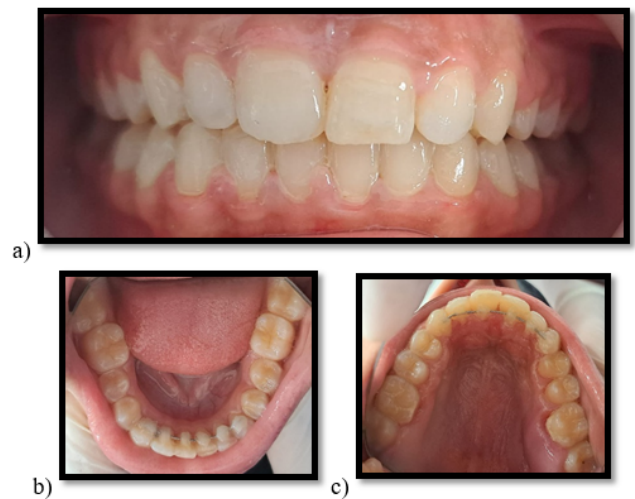After 15 months of treatment, the teeth on both arches were aligned, and a 3 mm overbite was achieved. Retraction of maxillary incisors was performed to achieve a normal, 2 mm overjet. Intrusion of incisors was performed on both arches to achieve a 2-mm overbite with a 0.017 × 0.025-inch stainless steel wire. E-chains were placed with relieve given to 21 for a period of 2 months since the orthodontic forces caused Grade I mobility in it.

Debonding was performed after 18 months of treatment (Figure 9 a). The deep bite was corrected (2 mm overbite), a normal overjet was achieved, the maxillary and mandibular teeth were well aligned, and the aesthetics were improved.

Oral prophylaxis was repeated followed by fluoride application. Retainer wires were bonded to the lingual surfaces of both upper and lower anterior teeth (Figure 9 b, c). Patient was kept on a 6-month follow-up.

### 3. Discussion

Graber defined ‘Deep bite’ as a condition of excessive overbite, where the vertical measurement between the maxillary and mandibular incisal margins is excessive when



**Figure 9:** a) Front view after debonding b) Retainer placement in mandibular arch c) Retainer placement in maxillary arch

the mandible is brought into habitual or centric occlusion.

Treatment options for cases with deep bites include proclination of the lower incisors, incisor intrusion, molar eruption/extrusion, and, in extreme situations involving the skeleton, a combination of orthodontics and surgery.<sup>7,8</sup>

The ideal mechanics should be determined by taking into account a number of variables, such as the patient’s development potential, profile, smile aesthetics, and stability of the outcome. In our present case the patient was referred to our institution with a chief complaint of irregular teeth and an unattractive smile.

Based on the clinical examination, the patient was found to have an extreme curve of Spee, significant crowding in mandibular arch, and Class II skeletal malocclusion (ANB = 5.5°).

According to El-Dawlatly et al.<sup>9</sup> deep bite malocclusion is primarily caused by an excessive or steep mandibular curve of Spee, as shown in our case as well. Overeruption of the mandibular incisors as an adaptation to achieve occlusal contact with the maxillary incisors results in a steep curve of Spee.<sup>9,10</sup> Untreated deep bites can result in temporomandibular joint abnormalities, aberrant mandibular function, palate mucosa injuries, lower incisor attrition, and in extreme situations, lower incisor loss.<sup>4</sup> For this reason, orthodontic therapy is necessary.

In this case, the patient had an anterior deep bite with Type I Dewey modification (anterior crowding). There was class I molar relationship on both (right and left) side. The maxillary arch was V-shaped and the mandibular arch was U-shaped. The fixed anterior bite plane helped us in correction of the anterior deep bite and the increased overbite. The fixed orthodontic treatment assisted in aligning the crowded teeth. At the end of the treatment, we achieved a better interdigitation of the teeth as well

as an aesthetically pleasing smile of the patient. However, there was slight space in the premolar region for their interdigitation, on the right as well as the left side, which got corrected after their complete eruption. Hence after a period of 18 months we removed the brackets and archwires so that the premolars could erupt completely into occlusion.

A shift in the interincisal angle, leveling methods, the vertical position of the maxillary incisors, the location of the mandibular incisors in the basal bone, and patient compliance during the retention phase are just a few of the variables that might impact the stability of deep bite repair.<sup>11</sup> Too straight mandibular and maxillary incisors prior to treatment usually revert to their pre-treatment positions during the postretention phase.<sup>12</sup> Because of this, it is advised to have a favorable interincisal angle, which can be accomplished by proclining either or both of the mandibular or maxillary teeth. To create an occlusal stop and restrict the mandibular incisor tips from erupting past the maxillary incisors, the interincisal angle should be adjusted so that they occlude onto the maxillary incisor cingula.<sup>13</sup> In this case, proclination of the maxillary and mandibular incisors was achieved through the leveling and aligning process.

In deep bite correction, long-term retention is crucial, just like in any other orthodontic treatment. According to Danz et al.<sup>14</sup> a fixed retainer and a temporary detachable upper plane placed after successful treatment discovered that the degree of relapse is minimal and not clinically significant. Hence, at the end of the treatment we placed retainer wires in the anterior region of both upper and lower arches for retention.

#### 4. Conclusion

For the treatment of deep bites in growing patients, anterior bite plane used in conjunction with fixed appliances work well. While the fixed appliances align the teeth by incisor proclination, an anterior bite plane permits the posterior segment to erupt freely and flattens the Spee curve. Consequently, the overbite is lessened and aesthetics enhanced.

#### 5. Source of Funding

No financial support was received for the work within this manuscript.

#### 6. Conflicts of Interest

There are no Conflicts of Interest.

#### References

- Ghafari JG, Macari AT, Haddad RV. Deep bite: Treatment options and challenges. *Semin Orthod.* 2013;19(4):253–66.
- Alhammadi MS, Halboub E, Fayed MS, Labib A, El-Saaidi C. Global distribution of malocclusion traits: A systematic review. *Dental Press J Orthod.* 2018;23(6):40–1.
- Proffit WR, Fields HW, Sarver DM, Ackerman JL. Contemporary Orthodontics. 5th ed. Elsevier; 2013. p. 744.
- Bhateja NK, Fida M, Shaikh A. Deep bite malocclusion: Exploration of the skeletal and dental factors. *J Ayub Med Coll Abbottabad.* 2016;28:449–54.
- Dermaut LR, Pauw D. Biomechanical aspects of Class II mechanics with special emphasis in deep bite correction as part of the treatment goal. *Biomechanics Clin Orthod.* 1997;p. 86–98.
- Namrawy ME, Sharaby FE, Bushnak M. Intrusive Arch versus Miniscrew-Supported Intrusion for Deep Bite Correction Manal . *J Med Sci.* 2019;7(11):1841–7.
- Mitchell L. An Introduction to Orthodontics. Oxford: Oxford University Press; 2013.
- Daokar S, Agrawal G. Deep bite its etiology, diagnosis and management: A review. *J Orthod Endod.* 2016;2:1–4.
- El-Dawlatly MM, Fayed MM, Mostafa YA. Deep overbite malocclusion: Analysis of the underlying components. *Am J Orthod Dentofac Orthop.* 2012;142:473–80.
- Fontaine-Sylvestre C. Predictability of Deep Overbite Correction Using Invisalign. *Am J Orthod Dentofac Orthop.* 2019;163(6):793–801.
- Huang GJ, Bates SB, Ehlert AA, Whiting DP, Chen SS, Bollen AM. Stability of deep-bite correction: A systematic review. *J World Fed Orthod.* 2012;1:89–95.
- Kim TW, Little RM. Postretention assessment of deep overbite correction in Class II Division 2 malocclusion. *Angle Orthod.* 1999;69:175–86.
- Millett DT, Cunningham SJ, O'Brien KD, Benson PE, De Oliveira C. Treatment and stability of class II division 2 malocclusion in children and adolescents: A systematic review. *Am J Orthod Dentofac Orthop.* 2012;142:159–69.
- Danz JC, Greuter C, Sifakakis I, Fayed M, Pandis N, Katsaros C, et al. Stability and relapse after orthodontic treatment of deep bite cases—a long-term follow-up study. *Eur J Orthod.* 2014;36:522–52.

#### Author biography

**Shruti Verma**, PG Student  <https://orcid.org/0009-0006-0036-2927>

**Deveshi Nigam**, PG Student

**Chaitra Ravishankar Telgi**, Associate Professor

**Seema Chaudhary**, Professor and Head

**Naveen Manuja**, Associate Professor

**Ashish Amit Sinha**, Associate Professor

**Cite this article:** Verma S, Nigam D, Telgi CR, Chaudhary S, Manuja N, Sinha AA. Enhancing the aesthetics with anterior deep bite correction: A case report. *IP Indian J Orthod Dentofacial Res* 2024;10(1):55-58.