

## Rapid Maxillary Expansion – A Review

Pooja Relwani<sup>1,\*</sup>, Shashanka P. Kumar<sup>2</sup>, Nishitha C. Gowda<sup>3</sup>, Vennila N. Swamy<sup>4</sup>, Santosh Ramegowda<sup>5</sup>

<sup>1</sup>Post Graduate Student, <sup>2,4</sup>Reader, <sup>3</sup>Senior Lecturer, <sup>5</sup>HOD & Professor, Vokkaligara Sangha Dental College & Hospital, Bangalore

**\*Corresponding Author:**

Email: poojarelwani1002@gmail.com

### Abstract

Rapid Maxillary expansion also called as palatal expansion has a unique role in dentofacial therapy. Rapid Maxillary expansion which is a type of skeletal expansion involves the opening of the mid-palatal suture and movement of the palatal shelves away from each other. Selection of appropriate appliance should be made by preparing a list of criteria depending on the biomechanical requirements of RME. Rapid expansion affects the maxillary complex, palatal vaults, maxillary teeth, adjacent periodontal structures to get desired expansion in the maxillary arch.

**Key Words:** Rapid Maxillary Expansion, Maxillary halves, Sutures

### Introduction

In 1860, Emerson Angell first described the rapid maxillary expansion and later re-popularized by Haas. Expansion of the maxilla, by the use of fixed or removable expansion appliances, is mainly used in orthodontics for the correction of malocclusion. Expansion is primarily used for the correction of posterior crossbites occurring as a result of insufficient maxillary width. It is particularly important to correct the deviation of mandible while function and deficient maxillary arch width in early dentition development, which, if not corrected, may have undesirable consequences on facial symmetry and function of TMJ.

Rapid Maxillary expansion occupies unique niche in orthodontic treatment. The elimination of transverse maxillary deficiency should include as an important part of an orthodontic treatment plan. Growth is normally complete by the age of 17 years and the mean transverse growth between the age of four years and adulthood is 6.9 mm. Maxilla will grow in small amount transversely throughout the life, it is more likely that a crossbite encountered in the permanent dentition will not get corrected by itself.<sup>1</sup>

### Anatomy of Maxilla

Except for the mandible, the maxilla (including the premaxilla) is the largest facial bone. Maxilla articulates with the following bones.<sup>2</sup>

#### Cranial –

1. Frontal 2. Ethmoid

#### Facial –

1. Nasal 2. Lacrimal 3. inferior nasal concha 4. vomer 5. Zygomatic  
6. Palatine 7. Opposite maxilla

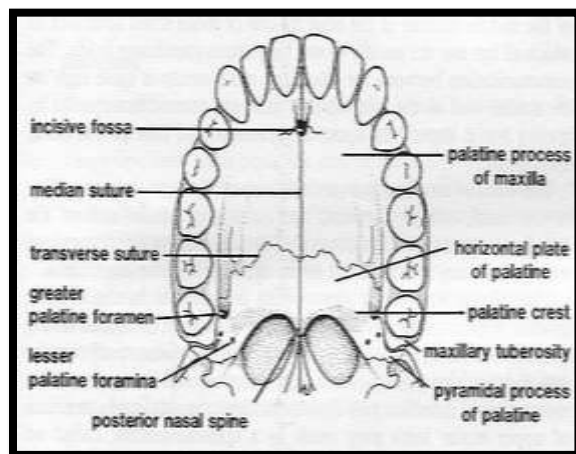
### Sutures<sup>1</sup>

The rigidity of circummaxillary sutures due to upholding is strong postero-superio-medially and posterior- superio -laterally. A palatal bone combines

with maxilla to form complete hard palate (or) nasal floor and major part of lateral wall of nasal cavity. It fuses with maxilla anteriorly through transverse palatal sutures and through pterygoid process of the sphenoid bone posteriorly. Two palatine bones joins by interpalatine suture at their horizontal plate and continuous as inter maxillary sutures. These sutures form the junction of three pairs of bones: the premaxillae, maxilla and the palatine and completely forms mid-palatal suture.

Mid Palatine Suture –shape changes with age<sup>2</sup>

- i. Infancy - Y-shape
- ii. Juvenile - T-shape
- iii. Adolescence - Jigsaw puzzle



**Fig. 1: Inferior Aspect of Palate**

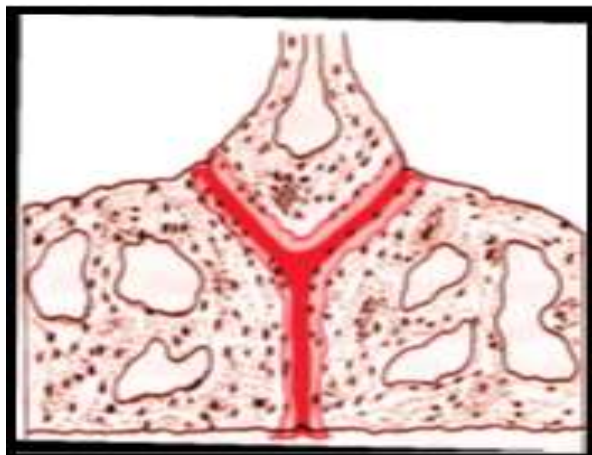


Fig. 2: Mid Palatal Suture in infancy<sup>4</sup>

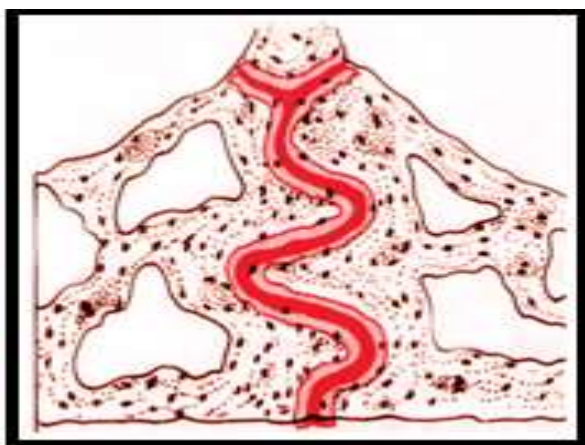


Fig. 3: Mid Palatal Suture in Juvenile,<sup>(4)</sup>

The maxilla is connected to the cranium and cranial base by a number of sutures<sup>3</sup>

1. Nasomaxillary Suture
2. Frontomaxillary Suture
3. Zygomaticotemporal Suture
4. Lacrimomaxillary Suture
5. Ethmoidomaxillary Suture
6. Vomeromaxillary Suture

It is important to know when does the suture closes by synostosis and on an average 5% of suture in closed by age 25 years. Earliest closure occurs in girls aged 15 yrs. Greater degree of obliteration occurs posteriorly than anteriorly. Ossification comes very late anterior to incisive foramen, this is important when planning surgical freeing in late instances of RME.<sup>1</sup>

#### Factors to be considered prior to expansion<sup>1</sup>

Important factors to be considered in Rapid Maxillary Expansion:

1. **Rate of Expansion:** Active expansion of 0.3 -0.5 mm is completed in 2-4 weeks, with some time for the cellular response of osteoclasts and osteoblasts cells.
2. **Form of Appliance:** expansion must reach to the basal portions of maxilla when the thrust come to

the teeth. According to its rigidity or flexibility, appliance will play an important role i.e. anchorage or control of tipping.

3. **Age and Sex of the patient:** expansion differs in both the sexes because of increasing rigidity of facial skeletal with age.
4. **Difference between maxillary and mandibular first molars & bicuspid width** is 4mm or more indicated for rapid expansion.
5. **Severity of cross bite** i.e. number of teeth involved.
6. **Initial angulations of molars or premolars:** When the maxillary molars are buccally inclined, expansion will help to tip them further into the buccal musculature and also help to upright the lower molars if they are lingually inclined.
7. Assessment of roots of deciduous tooth.
8. Physical availability of space for expansion.
9. **Nasal Obstruction:** Before orthodontic treatment, patient should examine for nasal obstruction. If obstruction is present then the patient should refer to an otolaryngologist.
10. **Medical history:** maxillary expansion depends on suture opening, lack of obstruction and the resiliency of craniofacial complex to adapt to biomechanical changes. So the medical conditions should be considered.
11. **Metabolic disorders:** Many metabolic disorders are associated with suture synostoses which include hyperthyroidism, hypophosphatemic vitamin D-resistant rickets and mucopolysaccharidoses and mucopolipidoses. These disorders are mostly associated with bone metabolism. Maxillary expansion will be affected even in young patients if they are suffering from any of these diseases.
12. **Periodontal Type:** Gingival condition is also important as periodontal condition because a thin and delicate gingiva might be prone to recession after surgical trauma or injury.
13. **Mucogingival Health:** Health of the mucogingival tissue is also important as periodontal and gingival condition, so it should be assessed before expansion.

#### Types of RME

- a) Tooth & tissue borne
  - Derichweiler
  - Hass
- b) Tooth borne
  - Isaacson
  - Hyax

#### Indications for RME

1. Severe maxillary constriction (narrow maxillary base or wide mandible).
2. Unilateral or bilateral posterior crossbites.
3. Anteroposterior discrepancies.
4. Patients with Class III malocclusions and borderline skeletal and pseudo Class III problems.
5. Cleft lip and palate patients with collapsed maxillae.

- To gain arch length in patients who have moderate maxillary crowding.

### Contraindication for RME

- Uncooperative individuals.
- Single tooth cross bite.
- Anterior open bite.
- Steep mandibular plane angle and convex profile.
- Skeletal asymmetry of the maxilla or mandible.
- Adults with server anteroposterior and vertical skeletal discrepancies

### Activation schedule

- Schedule by Timms<sup>2</sup>

Patients  $\leq$  15 yrs: 90 degree rotation in morning and evening.

$\geq$  15 yrs: 45 degree activation 4 times per day.

$\geq$  20 yrs: 45 degree rotation in morning and evening.

- Schedule by Zimring and Isaacson<sup>6</sup>

**Young growing patients:** Two turns per day for 4- 5 days, followed by one turn per day till expansion is achieved.

**Non growing adults:** Two turns per day for 2 days, then one turn per day for 5-7 days, followed by one turn every alternate day, till expansion is achieved.

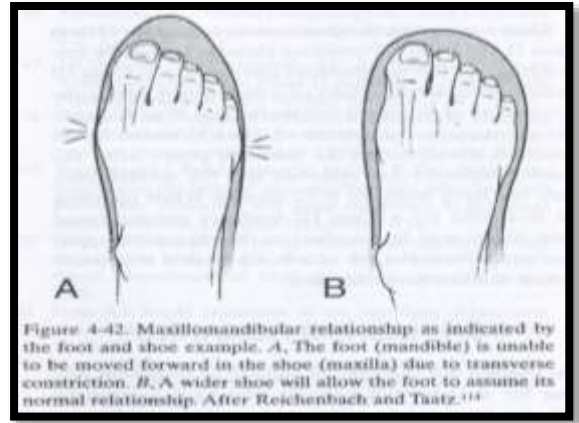
- Mc Namara and Brudon: Prefer a once per day activation schedule till expansion is obtained, in order to avoid nasal distortion (saddle nose deformity) which has been associated with two expansions per day protocol.<sup>7</sup>

### How much to expand??

Kerbs (1964) Stockfisch (1976) and Linder Aronson et al (1979) found that one third to one half of the expansion, was lost before achieving permanent stability.<sup>8</sup>

### A general and convenient guideline for expansion

- Stop expansion when the palatal cusps of maxillary posterior teeth reach up to the level of buccal cusps of the mandibular teeth.<sup>9,10</sup>
- Measure the distance between the mesiobuccal cusp tips of maxillary 1<sup>st</sup> molars.
- Buccal groves at the middle of the buccal surfaces of mandibular 1<sup>st</sup> molars.
- Subtract the mandibular measurement from maxillary measurement.



### Ideal transpalatal width

Maxillary: 35- 39mm

Mandibular: 33 to 34mm

### Effects of RME

**Effect of RME on periodontal ligament:** The width of the PDL is 0.18 – 0.25mm. The screw when turned 90 degrees, the midpalatal suture will open by 0.2 mm and narrows the periodontal membrane by 0.1 mm on each side. It has been argued that such a mild reduction in space in the periodontal width would not interrupt the circulation of blood and will facilitate an ideal orthodontic condition for the transformation of bone. Also, Ziehe in 1930 has mentioned that the expansion should not exceed 0.2 – 0.5mm/ day which would lead to PDL compression and rupture of blood vessels.<sup>2</sup>

**Effect on maxillary and mandibular complex:** The appliance collapses the periodontal ligament in periodontal space, bends the alveolar processes, tips the anchor teeth buccally and gradually opens the midpalatal suture. The applied force acts like an orthopaedic force that opens the midpalatal suture.<sup>11</sup>

**Viewed frontally:** The maxillary suture separates supero-inferiorly in a nonparallel manner and pyramidal in shape with the base of the pyramid located at the oral side of the bone. The suture opens like a fan with the inferior points moving greater and the fulcrum in the nasal cavity. Krebs, showed that the both the halves of the maxilla rotated in the antero-posterior and frontal direction.<sup>6</sup>

**Viewed occlusally:** Palatine processes of the maxillae separates in a nonparallel wedge shaped manner (75% to 80% of the cases observed).Wertz's study of three dry skulls; he found that the shape of the anteroposterior palatal opening of suture was nonparallel in all three skulls. The amount of the opening varies greatly in different person and at different area of the suture. In general, the opening is smaller in adult patients. The

actual measurement ranges practically from no separation to 10 mm or more.<sup>6</sup>

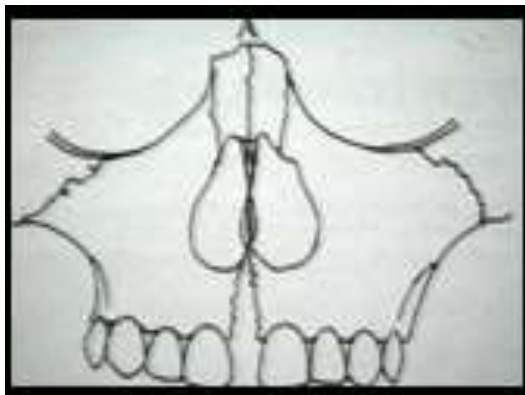


Fig. 5: Frontal View

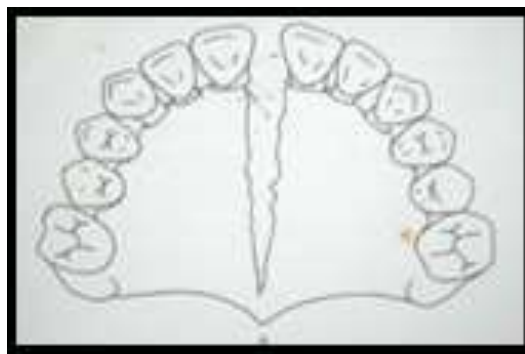

Fig. 6: Occlusal View

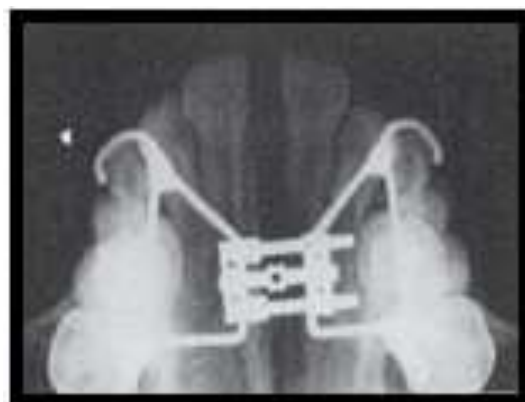

Fig. 7: Occlusal Radiograph

#### Effects of RME on adjacent facial structures

Kudlick, in a study on a human dry skull that simulated in vivo response of RME, concluded the following<sup>6</sup>

1. Directly attached bones of craniofacial region were moved except sphenoid bone.
2. No change in cranial base angle.
3. Displacement of the maxillary halves was asymmetric.
4. Sphenoid bone was the main uphold against expansion of maxilla not the zygomatic arch.

**Movements of the Maxilla:** Haas and Wertz found the maxilla moves mainly downward and forward due to expansion. The final position of the maxilla, after completion of expansion, cannot predict and it has been reported to return either partially or completely, to its original position.

**Alveolar processes:** Because bone is resilient, bending of the alveolar processes occurs laterally initially during expansion. Most of the applied forces tend to dissipate within 5 to 6 weeks. After stabilization is terminated, any remaining forces in the displaced tissues will react on the maxillary alveolar processes causing them to bounce back. So the overcorrection is required to compensate the subsequent rebound.<sup>6</sup>

**Maxillary anterior teeth:** One of the most dramatic changes accompanying rapid expansion is the opening of a diastema. It is evaluated that during initial suture separation, the incisors move almost half the distance, the expansion screw has been opened. After this separation, the crowns of incisors converge and establish proximal contact. Due to property of elastic recoiling the transeptal fiber tips the crown mesially. Once the crowns touch, the continued stretching of the fibers makes the roots to move towards their initial axial position. This cycle generally takes about 4 months. This cause the extrusion of maxillary central incisors relative to the Sella-Nasion plane and in 76% of the cases it has up righted or tipped lingually. This tooth movement helps to close the diastema and also to shorten arch length. Stretched circumoral musculature cause the tipping of incisors lingually.

**Maxillary posterior teeth:** With the initial alveolar bowing and condensing of the periodontal ligament, there is a certain change in the long axis of the posterior teeth and the angulations of both the sides of molars increased from 1° to 24° during expansion. All these changes are not only because of alveolar bowing but also the buccal tipping of posterior teeth.

**Effect of RME on mandible:** Due to expansion of maxilla, the mandible swing downwards and backwards. Increase of mandibular plane angle due to tipping and extrusion of maxillary posterior teeth along with bowing of alveolar processes. So care should be taken while using RME patient with steep mandibular plane angle or open bite tendencies.

**Effects of RME on the mandibular teeth:** Gryson, studied on 38 patients (age ranges b/w 6-13 years) to compare the width of maxilla and mandible before and after expansion. He found that mandibular teeth were upright or remain relatively stable. The mean increase in the mandibular intermolar width was 0.4 mm; most patients either had no change or showed an increase of

up to 1 mm. so the rapid expansion affect the mandibular dentition but changes are unpredictable.

**Effects of RME on nasal airway resistance:** In 1902, Brown described the first case in which nasal blockage was eliminated by the rapid palatal expansion by separating the palatal halves along with opening of midpalatine suture. There is increase in volume of nasal cavity immediately following expansion, particularly at the floor of nose adjacent to midpalatal suture. The nasal cavity width gain averages 1.9 mm, but can widen as much as 8 -10mm at the level of inferior turbinates. The effect ranges from no change to marked improvement of nasal airflow.

**Effect on circummaxillary sutures:** The opening of circummaxillary sutures ranges from 0.30-0.45 mm. All the sutures which attached directly to maxilla opened more than suture away from maxilla, farther sutures show lower amount of opening.<sup>3</sup>

**Effect of RME on soft tissue:** Tip of the nose and soft tissue point A follows the anterior movement of the maxilla and maxillary incisors. Nihat, Kilic et al, concluded in their study that the soft tissue facial angle decrease, the H angle and profile convexity increases after RME.<sup>12</sup>

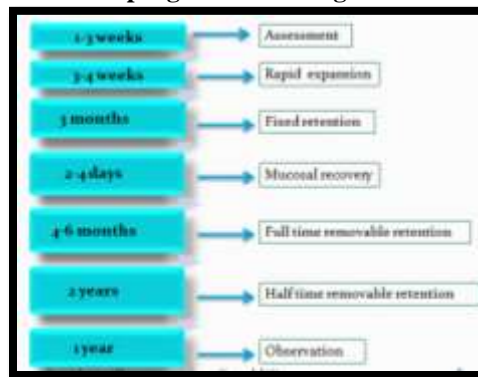**CBCT to assess changes after RME treatment:** Cone-Beam Computed Tomography is a innovative diagnostic method in dentistry as it gives high dimensional accuracy of the facial structures and a authentic method for quantifying the position of the maxillary halves, tipping of teeth, bone formation at the suture, alveolar bone resorption and other consequences of maxillary expansion.<sup>13</sup> Some studies have been done to assess the effects of Rapid Maxillary Expansion on the periodontal and skeletal changes. Before CBCT, the changes obtained by RME were used to assess by dental model and conventional radiographs but with CBCT, clinicians can accurately assess the three dimensional changes in the skeletal structures quantitatively. Also CBCT studies emphasize that tipping caused by maxillary expansion was due to the decrease in buccal bone thickness. One can see a triangular shaped, radiolucent area with its base facing the anterior nasal spine with reduced bone strength. At the same time CT confirms the orthopedic splitting of the maxilla, it subsequently records midpalatal suture reorganization, which occurs during the retention phase.<sup>14</sup>

#### Construction guide lines

- Ideally the screw should be placed as high in palatal vault as possible.
- The entire appliance component should be kept away from tissue surface.
- Centre of screw must be waxed out to keep it clear of acrylic.

- Screw is mounted in the midline of the vault with the thread axis in line with the anterior borders of the 1<sup>st</sup> permanent molar.
- Direction of the arrow should be facing posteriorly.

#### Retention program according to Timms<sup>2</sup>



#### Hazards of RME<sup>2</sup>

1. Difficulty with oral hygiene
2. Length of fixation
3. Chances of dislodgement and breakage
4. Tissue trauma
5. Infection (acute ulcerative gingivitis-most common)
6. Sometime failure of suture to open.

#### Advancement in Treatment

**SARPE<sup>15,16</sup> (Surgically Assisted Rapid Palatal Expansion):** During skeletal expansion, the buttressing effect of zygomatic and sphenoid bones at their point of attachment to the maxilla gives the main resistance and form the integrity of the midpalatal suture. With SARPE, these attachments are surgically detached which allows expansion to be easily achieved using a conventional RME appliance. Before surgery, fixed appliances can be used to move apart the roots of the central incisors to prevent the damage of roots by midline maxillary surgical cut. Expansion is typically carried out at a rate of 0.5 mm a day and patients develop a significant midline diastema, which they must be warned about. Probably because of the inelasticity of the palatal mucoperiosteum there will be more chances of relapse after surgical correction so the overcorrection is required to compensate the relapse. SARPE is the technique of choice in patients who do not have co-existing sagittal and vertical maxillary discrepancies which may require maxillary surgery at a later date.

**Segmental Maxillary Surgery<sup>16</sup>:** To expand the maxilla, Le fort I osteotomy technique should be performed simultaneously with surgical cut along the Midpalatal suture. The maxillary halves are then parted and positioned in the new place. Expansion is limited due to the relative inelasticity of palatal mucoperiosteum. Maxillary incisor roots can be separated with fixed

orthodontic treatment, to ease to make surgical midline cut like SARPE.

### Conclusion

RME is a technique of choice in several cases like moderate to severe transverse discrepancy. This helps us to increase the arch length in moderate crowding cases where arch length is deficient. Orthopedic transverse correction can be done by tipping of posterior teeth buccally along with separation of midpalatal suture. Overcorrection is required to compensate the relapse. Nowadays, CBCT has being used to assess the accurate three dimensional orthopedic changes after RME treatment

Advances in orthopedic expansion by surgical method include SARPE and segmental maxillary surgery which are simple, safe, noninvasive and similar to RME. Satisfactory occlusion can be established by subsequent, comprehensive orthodontic treatment with good stability. It is useful for cleft palate patients who often have an unpredictable blood supply system.

### References

1. Kumar SA, Gurunathan D, Muruganandham SS. Rapid Maxillary Expansion: A Unique Treatment Modality in Dentistry. *Journal of Clinical and Diagnostic Research*. 2011 August, Vol-5(4):906-911.
2. Rapid maxillary Expansion –Donald J. Timmis.
3. Leonardi R, Sicurezza E, Cutrera A, Barbato E. Early post-treatment changes of circumaxillary sutures in young patients treated with rapid maxillary expansion. *The Angle Orthodontist*. 2011 Jan;81(1):36-41.
4. Melsen B. Palatal growth studied on human autopsy material: a histologic microradiographic study. *American journal of orthodontics*. 1975 Jul 31;68(1):42-54.
5. Suri L, Taneja P. Surgically assisted rapid palatal expansion: a literature review. *American Journal of Orthodontics and Dentofacial Orthopedics*. 2008 Feb 29;133(2):290-302.
6. Bishara SE, Staley RN. Maxillary expansion: clinical implications. *American Journal of Orthodontics and Dentofacial Orthopedics*. 1987 Jan 1;91(1):3-14.
7. Altug-Atac AT, Atac MS, Kurt G, Karasud HA. Changes in nasal structures following orthopaedic and surgically assisted rapid maxillary expansion. *International journal of oral and maxillofacial surgery*. 2010 Feb 28;39(2):129-35.
8. Buddee, David Robert. "Some comparisons of slow and rapid maxillary expansion." (1984).
9. Isaacson RJ, Ingram AH. Forces produced by rapid maxillary expansion: II. Forces present during treatment. *The Angle Orthodontist*. 1964 Oct;34(4):261-70.
10. Zimring JF, Isaacson RJ. Forces produced by rapid maxillary expansion: III. Forces present during retention. *The Angle orthodontist*. 1965 Jul;35(3):178-86.
11. Doyle RE. Long term stability in the maxillary and mandibular arch dimensions using rapid palatal expansion and edgewise mechanotherapy in growing (Doctoral dissertation, Saint Louis University).
12. Kiliç N, Kiki A, Oktay H, Erdem A. Effects of rapid maxillary expansion on Hold away soft tissue measurements. *The European Journal of Orthodontics*. 2008 Jun 1;30(3):239-43.
13. Ribeiro GL, Locks A, Pereira J, Brunetto M. Analysis of rapid maxillary expansion using cone-beam computed tomography. *Dental Press Journal of Orthodontics*. 2010 Dec;15(6):107-12.
14. Khan MA, Hussain SS. The clinical application of cone beam CT in orthodontics. *Pak Ortho J*. 2014;6(1):32-7.
15. Susami T, Kuroda T, Amagasa T. Orthodontic treatment of a cleft palate patient with surgically assisted rapid maxillary expansion. *cleft palate craniofacial journal* . 1996 sep;33(5).
16. Gill D, Naini F, McNally M, Jones A. The management of transverse maxillary deficiency. *Dent Update*. 2004 Nov;31(9):516-23.