

## Adenoid Facies and its Management: An Orthodontic Perspective

Luv Agarwal<sup>1</sup>, Ragni Tandon<sup>2</sup>, Rohit Kulshrestha<sup>3,\*</sup>, Ankit Gupta<sup>4</sup>

<sup>1,3,4</sup> Post Graduate Student, <sup>2</sup>Professor & Head, Dept. of Orthodontics, Saraswati Dental College, Lucknow

**\*Corresponding Author:**

Email: kulrohit@gmail.com

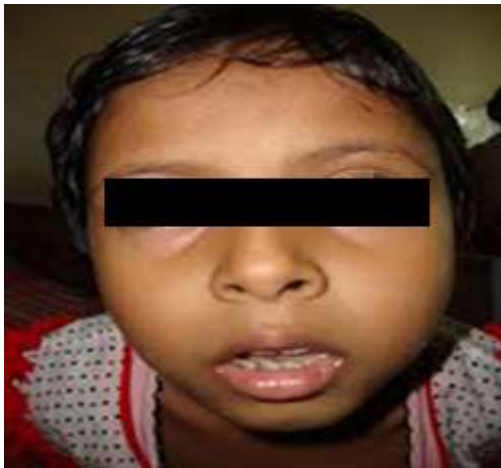### Abstract

Adenoid facies is a disorder which refers to the open-mouthed face of children who have long faces with adenoid hypertrophy. Hypertrophy of the lymphoid tissues in the throat (the adenoids) is the most common cause of nasal obstruction in children. The mouth is always open because upper airway congestion/narrowing has made patients obligatory mouth breathers. Persistent mouth breathing is seen due to nasal obstruction in children and it may be associated with the development of craniofacial anomalies such as the adenoid facies (also called the “long face syndrome”). The most common symptoms are habitual mouth breathing and snoring. The most dangerous symptom is sleep apnea due to obstruction. This article discusses the orthodontic aspects of diagnosis and treatment of adenoid facies.

**Key words:** Adenoids, Long face, Lymphoid tissue.

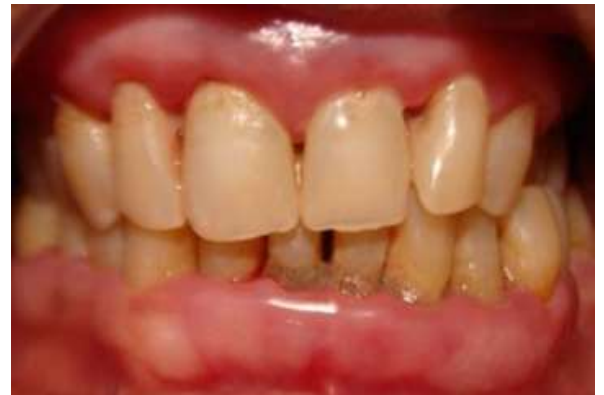### Introduction

C.V Tomes first coined the term “adenoid facies” in 1872, also called the “long face syndrome”. He described it as long, lean, open-mouth dumb faced patients with presence of dental crowding and high arched palate with chronic nasal airway obstruction (Fig. 1).<sup>1</sup>



**Fig. 1: Adenoid Facies**

The most common cause of nasal obstruction in children is hypertrophy of the adenoids (nasopharyngeal pad of lymphoid tissues). Mouth is always opened as patients with upper airway obstruction becomes obligatory mouth breathers and it results in abnormal face development with prominent crooked upper teeth and absence of lip seal (Fig. 2). This open mouth posture is called adenoid facies.



**Fig. 2: Intra oral feature of mouth breathing**

### Features of Adenoid Facies

The characteristic facial appearance is composed of:

Extra oral features

- Pinched nostrils, short upper lip
- Open mouth posture, elongated face
- Increased lower, steep angle of mandible
- mandibular retrognathism, vacant expression

Intra oral features

- Prominent upper teeth, high-arched palate,
- Crowded teeth, narrow upper alveolus
- Hypoplastic maxilla, anterior tongue position
- Retroclined mandibular incisors.

The most common presenting symptoms are chronic mouth breathing and snoring and most dangerous symptom is sleep apnea. Adenoid facies is also used for recurrent upper respiratory tract allergies.

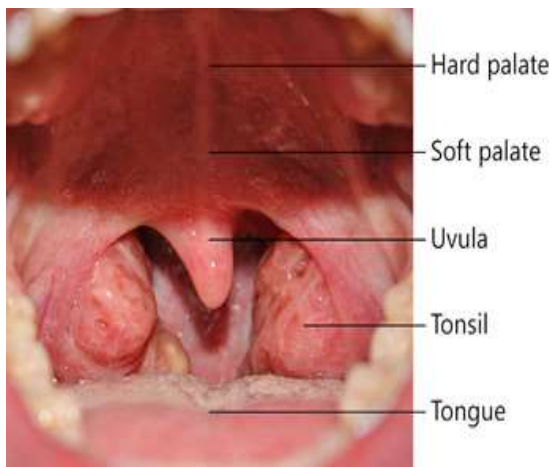
Its diagnostic features are:

- Dennie's lines- These are horizontal creases seen under both lower eyelids (first described by the American physician Charles Dennie)
- A nasal pleat- Horizontal crease just above the tip of the nose produced by the recurrent upward wiping of nasal secretions.

- Allergic shiners- These are bilateral shadows under the eyes produced by chronic venous congestion. Also, upward wiping of nasal secretions with either the palm or the dorsum of the hands is often called the “allergic salute”.
- Adenoid facies may be part of cowden syndrome.<sup>2</sup>

### Anatomy of Adenoids and its growth

Adenoid is a collection of lymphoid tissue in the mucous membrane at back of throat and it is a component of Waldeyer’s ring. The Waldeyer’s ring is a system of lymphoid tissue that surrounds the pharynx and it consists of adenoids, pharyngeal tonsils, lateral pharyngeal bands and lingual tonsils. Tonsils and adenoids are clumps of lymphoid tissue which are located on both sides at the back of the throat (Oropharynx) and adenoids are located higher in the passage that connects the back of the nose to the throat (Nasopharynx) (Fig. 3). The tonsils are visible through the mouth, but the adenoids are not directly visible through the mouth. A small mirror or a nasal endoscope is used to see the adenoids.



**Fig. 3: Anatomy of adenoids and tonsils**

It is oblong shaped, hangs from the roof of the nasopharynx and lined by ciliated columnar epithelium. The adenoid normally enlarges between 3 - 4 years during childhood as during this period, the child is most prone to respiratory infections. The adenoid shows regression in size and may disappear during puberty as the child grows older. The rapid nasopharyngeal airway enlargement has been attributed to this initial reduction in adenoid size. Adenoid tissue is rarely present in adults and when it is seen, it is usually in an atrophic condition. Linder-Aronson<sup>2</sup> (1970) described the sequel of hypertrophic adenoids for the face and coupled its development by changes in muscular balance. The mouth breathing results in a lower tongue position and there is an imbalance between the forces from the cheeks and tongue which causes a low mandibular position and extended head posture.

### Role of Adenoids and Tonsils

Tonsils and adenoids trap bacteria and viruses which enters through the throat and nose and produce antibodies to help fighting the body infections. They are not considered to be very important as our body has other means of preventing infection and fighting off bacteria and viruses. Children are born with adenoids which are small and they usually shrink after about 5 years of age, and it practically disappears by adolescence. Some children (and adults) are prone to develop infections of the tonsils and adenoids. These infections can be caused by different kinds of bacteria other than streptococcus.

### Symptoms of Enlarged adenoids and Tonsils

Enlarged adenoid causes typical changes in the face of young children. This excessive adenoidal growth interferes with normal facial growth and can result in abnormal breathing patterns, eustachian tube dysfunction, facial growth abnormalities, swallowing problems and speech problems (Fig. 4). It manifest as congestion, snoring, mouth breathing, sleep apnea, rhino-sinusitis, otitis media, reduced ability to smell and taste. Jaws and teeth are mostly disfigured, usually teeth of the upper jaw are irregular and crowded and there is malocclusion of upper and lower jaws. These changes are collectively termed as adenoid facies.<sup>3</sup>



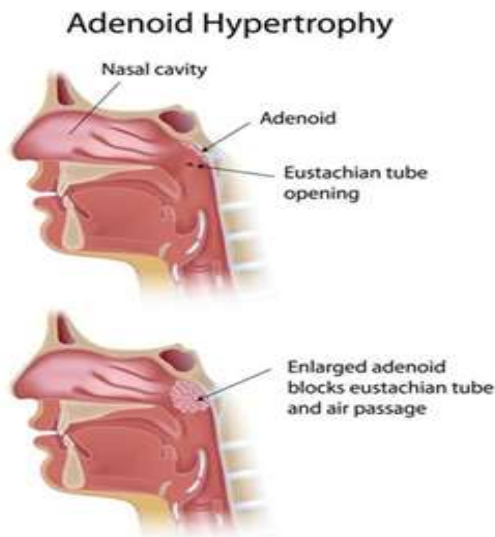
**Fig. 4: Abnormal breathing pattern in adenoid facies**

### Upper Airway Obstruction and Mouth Breathing

The etiological factors involved in upper airway obstruction are developmental disorders, macroglossia, anatomical constriction of airway, enlarged tonsils and adenoids, nasal polyps and allergic rhinitis, but enlarged adenoids and tonsils are considered as the major contributing factor.<sup>4,5</sup> Airway obstruction, resulting from nasal cavity or pharynx blockage, leads to mouth breathing (Fig. 5). This results in postural modifications such as open mouth, lowered tongue position, clockwise mandible rotation and head posture changes.

These modifications are seen as:

- Altered mandibular posture:** Downward and backward rotation of the mandible in response to the etiologic factor.
- Altered tongue posture:** Superior and anterior movement of tongue in response to the etiologic factor.
- Extended head posture:** Upward rotation of cranium and maxilla and mandible is held in position.
- These modifications take place to stabilize the airway.<sup>6,7</sup>



**Fig. 5: Adenoid Hypertrophy**

### Interrelation between adenoids, nasal obstruction and malocclusion

Enlarged adenoids can cause airway obstruction resulting in noticeable dentofacial changes and these changes have been described by CV Tomes in 1872 as adenoid facies. He reported that children, mouth breathers, often show narrow V-shaped maxillary arches and it is a result of mouth breathing which keeps their lips apart and low tongue position.<sup>8</sup> The tongue positioning plays an important role in development of mandible. The downward displacement of tongue leads to a retrognathic mandible and an interposed tongue causing anterior occlusal anomalies. Also, airway obstruction coupled with absence of bucco-lingual pressure of the tongue, produces alterations in the maxilla due to which narrow maxilla and maxillary retrusion are seen. Palatal inclination related to cranial base and lower anterior facial height is also increased. Occlusal alterations like increased over jet, cross bite, open bite and retroclined maxillary and mandibular incisors may be seen.<sup>9</sup>

### Diagnosis

Physical examination does not easily identify enlarged adenoids. A lateral cephalometric radiograph

of the nasopharynx provides a valuable method in the evaluation of children with upper airway obstructions for assessing adenoids size. The major drawback of using lateral cephalogram for analysis of airway is that the 3 dimensional (3D) structure of the airway is represented as a 2 dimensional (2D) image on a cephalogram.<sup>10</sup> Therefore, 3D analysis of the airway shape and possible airway obstruction requires CBCT for further detection and volumetric assessment of the exact soft tissue anatomy. Nasopharyngeal space and the size of adenoids can be evaluated using flexible optic endoscopy and rhinomanometry.<sup>11</sup>

### Early Intervention Changes Lives

The correct time to stop the gradual progression of craniofacial abnormalities is early in childhood. The ENT would advise that all toddlers who are noted to be mouth breather on examination should be considered for an otolaryngology evaluation. Adenoid hypertrophy is the most common cause for chronic mouth breathing but may inferior turbinate hypertrophy, chronic rhinitis, choanal atresia, and pyriform aperture stenosis are other causative factors as well. The ENT uses the most advanced and minimally invasive procedures to resolve chronic nasal obstructions in all patients, particularly those in early childhood. They also help adults and children suffering from nasal obstruction or chronic congestion problems, but it is children of 18 months to four years old who benefit most from the early intervention.<sup>12,13</sup> A multidisciplinary approach is most effective in evaluation of patients, diagnosis and treatment. Health care workers, ENT surgeons and orthodontists must all work together in treating these patients. Early intervention and interceptive measures are necessary.

### Treatment Options

#### Pharmacological management

The pharmacological management of adenoid or tonsillar hyperplasia begins with a course of an antibiotic which acts against beta-lactamase producing organisms such as clindamycin or augmentin. Patient's resistant to above drugs can be prescribed an antibiotic effective against beta-lactamase producing organisms and anaerobes.

#### Homeopathy Treatment

Homeopathy remedies include Hydrastis and glycerine, one part of the tincture to six of glycerine, the drops are placed deep into each nostril, having the child taking deep breathes, it is left there for about fifteen minutes and then flushed out. Adenoids are greatly helped and many a times permanently cured by a weekly dose of Tuberculinum or preferably Bacillinum.

### Surgical intervention

If hypertrophied adenoids are the cause of upper airway obstruction, then adenoidectomy with or without tonsillectomy is indicated. Adenoid has a capability to undergo compensatory hypertrophy after removal of tonsil, therefore it should always be removed along with tonsillectomy. Conservative septal surgery in growing patients will not cause any adverse effect in dentofacial growth, but full septoplasty is not preferred in growing face. Radiofrequency inferior turbinate reduction is performed with a specially designed probe with a needle at the end which is placed into the submucosal stroma of the inferior turbinate, and controlled radiofrequency energy is delivered for tissue ablation while sparing the vital mucosa. The inferior turbinates size reduces on tissue healing. It takes approximately 10 minutes, and recovery time is 24 hours.<sup>14-16</sup>

### Orthodontic management

Various modalities of orthodontic management of upper airway obstruction are as follows:

#### 1. Maxillary expansion

Expansion of maxilla improves nasal volume and nasal flow thus alleviates the symptoms of upper airway obstruction. There are four techniques for expanding narrow maxillae: (a) expansion by orthodontic technique e.g. use of quad-helix appliance (Fig. 6), (b) rapid maxillary expansion (RME) a hyrax screw or palatal distractor is used (Fig. 7)(c) surgically assisted orthodontic maxillary expansion (Fig. 8) and (d) transverse segmental osteotomy.<sup>17</sup>

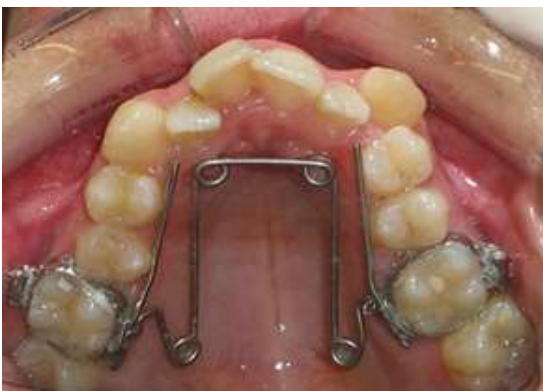

Fig. 6: Quad Helix

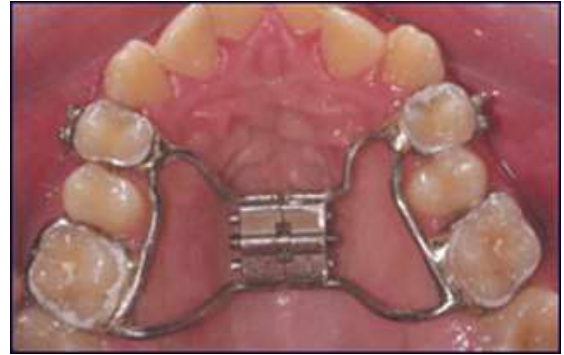

Fig. 7: Hyrax screw

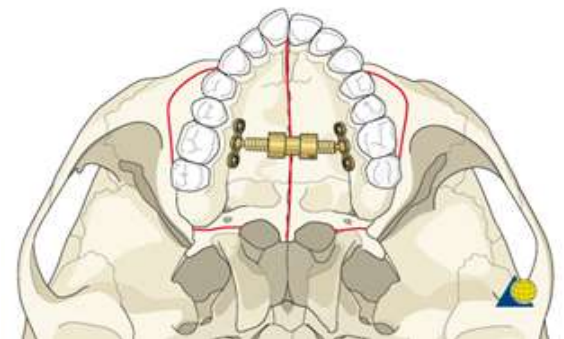


Fig. 8: Surgically assisted rapid palatal expansion

#### 2. Mandibular repositioning devices (MRDS)

The most common intervention for obstructive sleep apnea is removal of the adenoids and tonsils. This procedure is often associated with the surgical risks. This is why oral orthodontic appliances such as mandibular advancement devices are used which enlarges the upper airway and prevent its collapse by displacing the mandible forward (Fig. 9).<sup>18</sup>

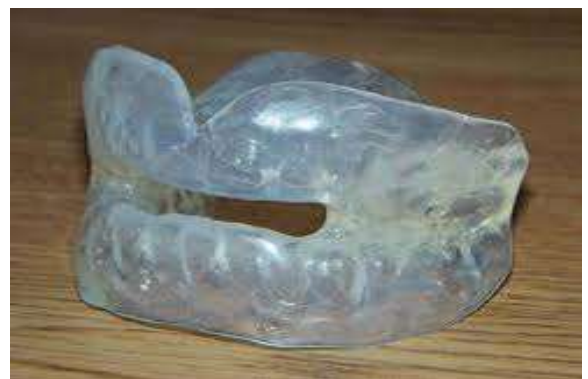
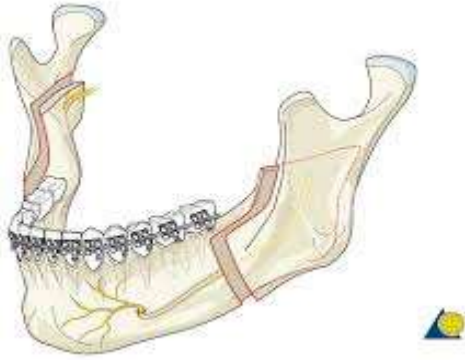
Fig. 9: Mandibular advancement splint

#### 3. Planned bilateral sagittal split surgery

This advances the mandible, widens the airway and relieves the symptoms of upper airway obstruction (Fig. 10).<sup>19</sup>



**Fig. 10: Bilateral sagittal split surgery**

### Discussion

The treatment modality depends on the extent and size of the adenoids, growth pattern of the patient, age and general body health. In younger children surgery is usually avoided as it may hamper normal growth.<sup>4,5</sup> In many cases surgery is done where there is no other treatment option left. The benefits are more than the side effects. Maxillary arch expansion is a very common technique and gives good results. Depending on the type of appliance patient co-operation can be included or excluded. Results are seen within 4 months of treatment. Expansion can be done in children till the age of 15 years that is before ossification of the mid palatal suture.<sup>17,19</sup> Once the suture is ossified arch expansion cannot be achieved. At this stage only surgical expansion of the arch is possible. Surgically assisted rapid palatal expansion is done in adults with severe malocclusions. This technique has been extensively researched and is a safe technique. Mandibular advancement splints are very useful in elder patients who have sleep apnea due to narrowing of the pharyngeal airway space. These splints place the mandible forward so that the pharyngeal airway space and increase its size and thus enable more air to pass through.<sup>15</sup> All these treatment modalities should be used after a sound diagnosis is made about the problem at hand. Etiological factor is also very important and it should be found and treated first.<sup>2,4,7,8</sup> Airway obstruction usually results from blockage of the nasal cavity or pharynx. This leads to mouth breathing which results in postural modification such as absence of lip seal, lowered tongue position, downward and backward rotation of the mandible, and a change in head posture. During mouth breathing, mastication, deglutition and phonation gets affected due to muscle alterations.<sup>7</sup> Rubin mentioned that if the patients are to be fully assessed they must be thoroughly examined by both an orthodontist and a rhinologist.<sup>8</sup>

### Conclusion

Adenoids have a significant effect on expressions of face, malocclusion and breathing mode. Therefore,

interceptive measures must be initiated soon. Early intervention requires a multidisciplinary approach to evaluation of patient, diagnosis of case and treatment. Physicians, allergists, otorhinolaryngologists, and orthodontists must all work together for early prevention and effective management of young patients with increased nasal airway resistance. After diagnosis, hereditary and environmental factors must be considered but the primary goal is to promote proper nasal respiration throughout a child's early years of facial growth. With the various treatment modalities at the orthodontists' disposal he can correctly diagnose and treat these cases. These cases may not be life threatening but can lead to many psycho social problems later in life.

### References

1. Hawke, Michael. 1997. Diagnostic handbook of otorhinolaryngology. CRC Press. King, Hueston C. 2004. Allergy in ENT practice. Thieme. Lee, Keat Jin. 2002. Essential otolaryngology. McGraw-Hill Professional.
2. Linder-Aronson, S, Adenoids: Their Effect on the Mode of Breathing and Nasal Airflow and Their Relationship to Characteristics of the Facial Skeleton and the Dentition, *Acta Oto-laryng Suppl*, 265:5-132,1970.
3. Diamond, O, Tonsils and Adenoids: Why the Delima? *Am J. Orthod.*, Nov. 78(5):495-503,1980.
4. Linder-Aronson S, Woodside DG. Excess face height malocclusion: Etiology, diagnosis and treatment. 1sted. Quintessence Pub; 2000.
5. Coelho AR, Tanaka O, Ribeiro JS, Machado MA, Camargo ES. Transverse craniofacial dimensions in Angle Class II, Division 1 malocclusion according to breathing mode. *Braz Oral Res.* 2010 Jan-Mar;24(1):70-5.
6. Oulis, CJ, Vadiaka, GP, Ekonomides, J, Dratsa, J, The Effect of Hypertrophic Adenoids and Tonsils on the Development of Posterior Crossbite and Oral Habits, *J Clin Pediatr. Dent*, Spring;18(3):197-201,1994.
7. Valera, FC, Travitzk, LV, Mattar, SE, Matsumoto, MA, Elias, AM, Anselmo-Lima, WT, Muscular, Functional and Orthodontic Changes in Pre-School Children with Enlarged Adenoids and Tonsils, *Int J Pediatr Otorhinolaryngol* 2003, Jul;67(7):761-70.
8. Rubin, RM, Effects of Nasal Airway Obstruction on Facial Growth, *Ear, Nose & Throat J*, May;66:44-53,1987.
9. Diamond, O, Tonsils and Adenoids: Why the Delima? *Am J. Orthod.*, Nov.78(5):495-503,1980.
10. Kemaloglu YK, Goksu N, Inal E, Akyildiz N. Radiographic evaluation of children with nasopharyngeal obstruction due to the adenoid. *Ann Otol Rhinol Laryngol*.1999 Jan;108(1):67-72.
11. Aboudara C, Nielsen I, Huang JC, Maki K, Miller AJ, Hatcher D. Comparison of airway space with conventional lateral head films and 3-dimensional reconstruction from cone-beam computed tomography. *Am J Orthod Dentofacial Orthop.* 2009 Apr;135(4):468-79.
12. Rubin, RM, Effects of Nasal Airway Obstruction on Facial Growth, *Ear, Nose & Throat J*, May;66:44-53,1987.
13. Gary, LP, Brogan, WF, Septil Deformity Malocclusions and Rapid Maxillary Expansion, *Orthodontist* 4;1-13,1972.

14. Cottle, MH, Nasal Surgery in Children, *Eyo, Ear, Nose and Throat Monthly*; 30:32-38,1951.
15. Jennes, JL, Corrective Nasal Surgery in Children: Long Term Results, *Arch Otolaryngol*;79:145-151,1964.
16. Stuck BA, Götte K, Windfuhr JP, Genzwürker H, Schrotten H, Tenenbaum T. Tonsillectomy in children. *Dtsch Arztebl Int.* 2008 Dec;105(49):852-60.
17. Kiliç N, Oktay H. Effects of rapid maxillary expansion on nasal breathing and some naso-respiratory and breathing problems in growing children: a literature review. *Int J Pediatr Otorhinolaryngol.* 2008 Nov;72(11):1595-601.
18. Effects of Mandibular Advancement Device (MAD) on Airway Dimensions Assessed With Cone Beam Computed Tomography Jennifer A. Haskell, John McCrillis, Bruce S. Haskell, James PScheetz, William C. Scarfe, and Allan G. Farman *Semin Orthod* 2009;15:132-158.
19. Stellzig-Eisenhauer A, Meyer-Marcotty P. Interaction between otorhinolaryngology and orthodontics: correlation between the nasopharyngeal airway and the craniofacial complex. *GMS Curr Top Otorhinolaryngol Head Neck Surg.* 2010;9:Doc 04.