

Content available at: <https://www.ipinnovative.com/open-access-journals>

IP Indian Journal of Orthodontics and Dentofacial Research

Journal homepage: <https://www.ijodr.com/>

Short Communication

Effortless canine up-righting with super elastic round wire

Sreejit Saha^{1*}, Diptiman Narayan Goswami¹, B S Chandrashekar¹,
Mahendra S¹, Aravind S Raju¹

¹Dept. of Orthodontics & Dentofacial Orthopedics, Krishnadevaraya College of Dental Sciences, Bangalore, Karnataka, India



ARTICLE INFO

Article history:

Received 20-11-2023

Accepted 12-12-2023

Available online 19-01-2024

Keywords:

Tipped canine

Ribbon arch mode

Super elastic round NiTi wire

Uprighting

Cuspid

ABSTRACT

Addressing dental irregularities and discrepancies in tooth size and arch length often involves intricate decision-making in planning orthodontic treatment for permanent teeth. Ensuring precise alignment of the dental crown's longitudinal axis is crucial for stability and achieving a balanced bite. In the past, orthodontists had to incorporate specific bends in the arch wire to achieve accurate tooth movements. However, with the introduction of the pre-adjusted edgewise appliance (PEA) it was thought to reduce the need for these complex wire manipulations, saving valuable time for clinicians. Rectangular NiTi and stainless-steel wires, along with specific auxiliaries, are commonly employed by orthodontists to correct tilted canines during the levelling and alignment phase, particularly when dealing with issues related to tip and torque using the built-in features of the PEA. Nonetheless, there are instances where these inherent features may prove insufficient due to mechanical inefficiency, prompting the utilization of auxiliary methods to rectify such issues. This article proposes a novel approach - the insertion of super elastic NiTi wire in the ribbon arch mode - to effectively rectify a tilted canine.

This is an Open Access (OA) journal, and articles are distributed under the terms of the [Creative Commons Attribution-NonCommercial-ShareAlike 4.0 License](https://creativecommons.org/licenses/by-nc-sa/4.0/), which allows others to remix, tweak, and build upon the work non-commercially, as long as appropriate credit is given and the new creations are licensed under the identical terms.

For reprints contact: reprint@ipinnovative.com

1. Introduction

The concept of normal occlusion, which characterizes the ideal dental alignment seen in individuals with excellent dental positioning, was originally introduced by Andrews in his seminal works published in 1972 and 1989.^{1,2} Andrews' pioneering research has since become a cornerstone in the field of Orthodontics. Furthermore, his contributions have reshaped our understanding of diagnostic criteria and treatment objectives in orthodontic practice.

Among the six key components defining normal occlusion, the precise mesiodistal alignment of the long axis of dental crowns plays a pivotal role in achieving a harmonious occlusal relationship and overall stomatognathic system balance.^{3,4} Additionally, this axial

alignment is a crucial factor for ensuring that teeth align correctly within their respective bony foundations and for maintaining the long-term stability of orthodontic treatments.³⁻⁵ This parameter is considered a benchmark for orthodontic treatment excellence and can be assessed through clinical evaluation or plaster model analysis, both before, during, and after orthodontic therapy.^{2,6-9}

Historically, the focus on dental angulations has been a notable aspect of Holdaway's perspective.⁴ In 1952, Holdaway proposed that orthodontic accessories should be angled during appliance installation, replacing the need for artistic bends in the anterior arch segment.⁴ Then, in 1970, Lawrence F. Andrews¹ pioneered the first fully preadjusted orthodontic appliance (Straight wire), which integrated in built prescription into the bracket design, thereby eliminating the necessity for second-order bends and the requirement for angulated bonding of the brackets.

* Corresponding author.

E-mail address: sreejitsaha.27@gmail.com (S. Saha).

However, the built-in features of this appliance do not entirely manifest due to mechanical inefficiencies in the fully preadjusted system.

Uprighting springs, initially introduced by Begg in 1956 as part of the light wire differential force technique, serve a dual purpose.¹⁰ They are employed not only for mesiodistal root uprighting during Stage III of Begg's Technique but also as braking auxiliaries to enhance anchorage during various tooth movements.^{10–12} However, the popularity of the light wire technique has waned with the advent of preadjusted edgewise appliances, leading to a decline in familiarity among modern orthodontists regarding the use of Begg uprighting springs. However, there are instances where these built-in features may not be fully effective owing to manufacturing errors. Of late, there has been renewed interest in exploring these springs as adjuncts in contemporary preadjusted edgewise appliance systems equipped with vertical slots. Their additional anchorage potential can be effectively harnessed for various treatments, such as posterior teeth protraction for space closure.¹² These springs are fabricated from 0.009" to 0.018" Australian archwire, tailored to the specific tooth type and intended purpose, whether mesiodistal up righting or providing supplementary anchorage as brakes.¹³

The inclinations of the anterior teeth, particularly those of the canines, play a pivotal role in determining the spatial arrangement of teeth within the dental arch, as illustrated in Figure 1. Moreover, these inclinations exert a direct influence on the angulation and protrusion of the incisors, as well as the measurement of overjet, as extensively documented in the literature.^{1,3,8,9,14}

2. Technique

A 17-year-old male patient visited our department, presenting with a primary concern of having upper and lower teeth that were positioned too far forward. However, it was not possible to evaluate the canine relationship on both sides due to the mesial tipping of both mandibular canines, as depicted in the figure. To address this, we bonded MBT brackets with 0.022 × 0.028 slots to both the upper and lower arches.

A 0.016 NiTi archwire was placed in the bracket slot in Ribbon archmode because it offers significant time and resource efficiency. In the context of the ribbon arch mode, the wire was skilfully ligated to the tipped canine bracket, forming an elegant 'S' configuration. This arrangement induced a counter-clockwise moment in the crown region, while simultaneously generating a clockwise moment in the root section, all with the ultimate objective of aligning the tooth to its proper position, as seen in the Figure 2. It was utilized to correct the mesial tipping of both canines by employing a super-elastic .014 NiTi round continuous archwire.

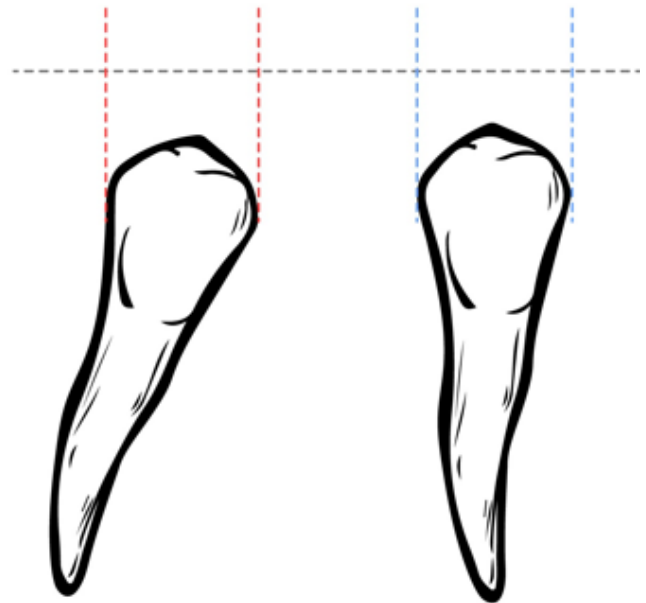


Figure 1: Greater angulation of anterior teeth results in greater occupancy of space within the dental arch, and conversely, reduced angulation leads to decreased space occupation.

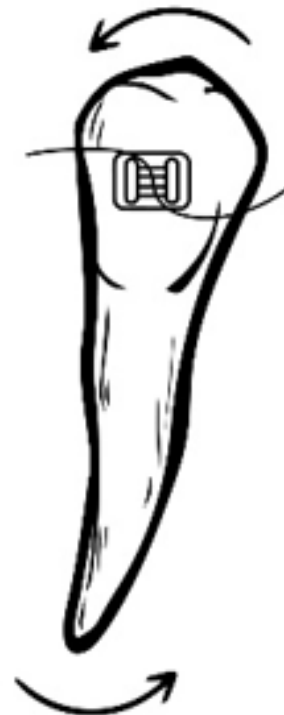

Figure 2: Ribbon arch mode- Placing round wire in a 'S' configuration to generate counter-clockwise moment in the crown and clockwise moment in the root in order to upright the tooth.

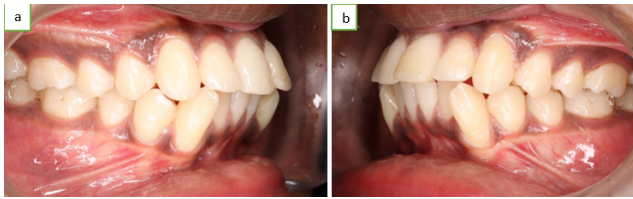


Figure 3: a, b: Pre-treatment photographs showing mesially tipped mandibular canine.

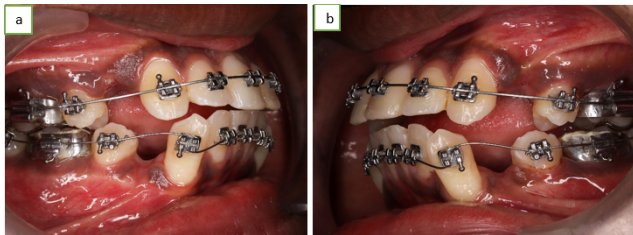


Figure 4: a,b: Intra oral pictures of the ribbon arch mode employed to upright the tipped canine.

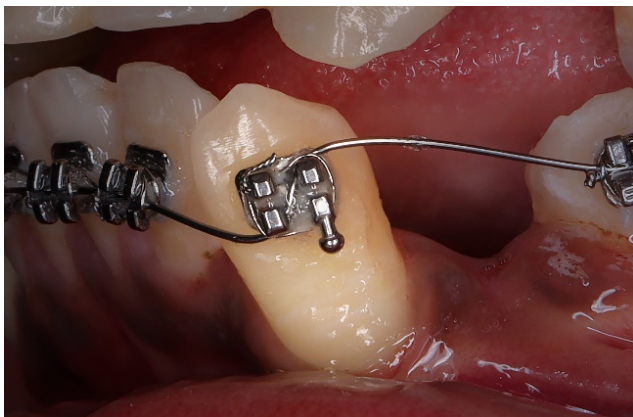


Figure 5: Zoomed in intra-oral picture of the ribbon arch mode

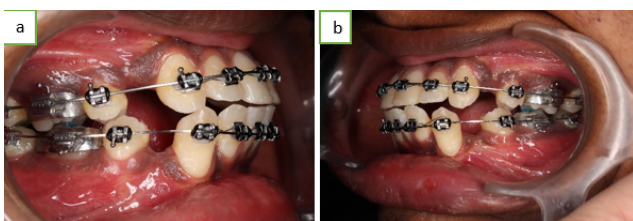


Figure 6: a,b: Intra oral pictures showing up righted mandibular canines after employing ribbon arch mode

2.1. Advantage

This approach not only significantly reduces treatment duration and the requirement for specialized tools but also presents a straightforward technique for uprighting anterior teeth, all accomplished without the necessity for additional auxiliary methods.

3. Conclusion

In summary, it can be inferred that each case mandates careful consideration for the selection of the most suitable appliance and a comprehensive evaluation. When conventional methods prove to be challenging or time-consuming in correcting tipped teeth, the ribbon arch mode technique emerges as a valuable alternative. It is imperative that each case is meticulously prepared, and optimal biomechanical principles are applied to expedite the achievement of therapeutic goals while prioritizing the patient's best interests.

4. Source of Funding

None.

5. Conflict of Interest


None.


References


1. Andrews LF. The six keys to normal occlusion. *Am J Orthod.* 1972;62(3):296–309.
2. Andrews LF. Straight-Wire: The Concept and Appliance. 2nd Edn. Wells Co., San Diego; 1989. p. 25–33.
3. Son LC, Filho OS, Ozawa T, Cavassan A. Individualization of brackets in the Straight wire technique: review of concepts and suggestion of indications for use. *R Dental Press Ortodon Ortop Facial.* 1999;4(4):87–106.
4. Holdaway RA. Bracket angulation as applied to the edgewise appliance. *Angle Orthod.* 1952;22(4):227–36.
5. Proffit W. Contemporary Orthodontics. Guanabara Koogan: Rio de Janeiro; 1995. p. 325.
6. Graber TM, Vanarsdall RL. Orthodontics: principles and techniques Current. Guanabara Koogan: Rio de Janeiro; 1996.
7. Strang RHW. Factors associated with successful orthodontic treatment. *Am J Orthod.* 1952;38(10):790–800.
8. Sangcharearn Y, Ho C. Upper incisor angulation and its effect on molar relationships. *Angle Orthod.* 2007;77(2):221–5.
9. O'Higgins EA, Kirschen RH, Lee RT. The influence of maxillary incisor inclination on arch length. *Br J Orthod.* 1999;26(2):97–102.
10. Begg PR, Kesling PC. The differential force method of orthodontic treatment. *Am J Orthod.* 1956;42:38–48.
11. Cadman GR. A vade mecum for the Begg technique: technical principles. *Am J Orthod.* 1975;67(5):477–512.
12. Barbieri AE, Barbieri FR. Begg auxiliaries. An evaluation and clinical application. *J Clin Orthod.* 1972;6(3):133–42.
13. Sengupt J. Refined Begg for Modern Times By Vijay P Jayade. First edition, Published by Mrs Anuradha V Jayade, Eureka Towers, Hubli-580 023. Karnataka, India, Sept 2001. 145 Pages. Price Rs 500/- . *Med J Armed Forces India.* 2001;59(1):80. doi:10.1016/S0377-1237(03)80122-3.
14. Almeida-Pedrin RR, Pinzan A, Almeida RR, Ursi W, Almeida MR. Panoramic evaluation of mesiodistal axial inclinations of maxillary anterior teeth in orthodontically treated subjects. *Am J Orthod Dentofacial Orthop.* 2006;130(1):56–60.


Author biography

Sreejit Saha, Post Graduate Student  <https://orcid.org/0009-0000-0523-8251>

Diptiman Narayan Goswami, Post Graduate Student  <https://orcid.org/0009-0000-7414-1680>

B S Chandrashekar, Professor  <https://orcid.org/0000-0002-3039-267X>

Mahendra S, Reader  <https://orcid.org/0009-0008-7285-3711>

Aravind S Raju, Reader  <https://orcid.org/0000-0003-1111-0136>

Cite this article: Saha S, Goswami DN, B S Chandrashekar, Mahendra S, Raju AS. Effortless canine up-righting with super elastic round wire. *IP Indian J Orthod Dentofacial Res* 2023;9(4):292-295.