

Content available at: <https://www.ipinnovative.com/open-access-journals>

IP Indian Journal of Orthodontics and Dentofacial Research

Journal homepage: <https://www.ijodr.com/>

Original Research Article

Ridge split assisted molar protraction

Anupa Rawat^{1,2*}, P Narayana Prasad^{1,2}, Tarun Kumar³, Tarun Sharma^{1,2},
Mansi Rawat^{1,2}, Gaurav Rathi^{4,5}, Sumit Joshi^{1,2}¹Seema Dental College and Hospital, Rishikesh, Uttarakhand, India²Hemwati Nandan Bahuguna Uttarakhand Medical Education University (HNBUMU), Dehradun, Uttarakhand, India³Faculty of Dental Sciences/SGT University, Gurugram, Haryana, India⁴Kalka Dental College & Hospital, Meerut, Uttar Pradesh, India⁵Chaudhary Charan Singh University, Meerut, Uttar Pradesh, India

ARTICLE INFO

Article history:

Received 06-10-2023

Accepted 09-11-2023

Available online 19-01-2024

Keywords:

Ridge split

Molar protraction

Knife edge ridge

Mini implant

ABSTRACT

Introduction: Protraction of a second molar into the gap left by a missing first molar is an option, although it is challenging to maintain root parallelism during mesial migration due to the thick and dense cortical bone. This study was carried out to make an attempt to evaluate whether molar protraction in subjects with missing mandibular first molar and knife edge ridges is possible or not using ridge split procedure (expansion).

Materials and Methods: The sample consisted of 12 subjects with missing mandibular first molar and knife edge ridges. All pre-treatment records were taken, after initial leveling and alignment ridge split procedure was performed and molar protraction was carried out using mini implants. Data was collected at a fixed interval of every six weeks. Statistical analysis using Repeated-measures ANOVA and Paired t test were done for evaluation of the rate of molar protraction and mesial molar tipping

Results: 0.12mm per week and 0.9 mm per six weeks was the rate of molar protraction that was accomplished. The mean edentulous space decreased from pre protraction to third visit significantly with a p value of ≤ 0.001 . There is mesial tipping of molar post protraction with a P value of 0.148 which is statistically non-significant. On an average duration for molar protraction was 8.4 months.

Conclusion: Ridge split made molar protraction possible in subjects with missing mandibular molar and knife edge ridges and enhanced the rate of tooth movement. The absolute anterior dental anchorage for the desired orthodontic movement was achieved by utilisation of mini implants.

This is an Open Access (OA) journal, and articles are distributed under the terms of the [Creative Commons Attribution-NonCommercial-ShareAlike 4.0 License](https://creativecommons.org/licenses/by-nc-sa/4.0/), which allows others to remix, tweak, and build upon the work non-commercially, as long as appropriate credit is given and the new creations are licensed under the identical terms.

For reprints contact: reprint@ipinnovative.com

1. Introduction

The highest susceptibility for carious degradation, periodontal disease and subsequent tooth loss is associated with permanent first molars as claimed by authors like Moyers. The permanent first molar has been claimed by Moyers to be the mostly lost tooth due to decay or periodontal disease.¹ A fixed partial denture is frequently

the preferred modality when the second or third molar is present. However, protracting the second and third molars is another effective method for closing the edentulous area. The mandibular molars are more difficult to shift mesially when compared to the maxillary molars because the mandible is composed of thick cortical bone joined by coarse trabecular pattern, and the molar roots are quite wide buccolingually. Anchorage control is crucial to prevent lingual tilting of mandibular incisors while protracting the second molar.²⁻⁷

* Corresponding author.

E-mail address: anuparawat123@gmail.com (A. Rawat).

One of the most difficult tooth movements during orthodontic therapy is mandibular molar protraction. The development of temporary anchorage devices has made it possible for orthodontists to complete complex tooth movements, such as molar protraction without moving the midlines and retracting the incisors.⁸

The duration for 2nd molar protraction in adults spans from 2 to 4 years. The rate of tooth movement relies on bone density, turnover rate, and hyalinization of the periodontal ligament. Adult patients have less cellular activity, more bone density, and more easily generate hyalinized zones on the pressure side, which reduces tooth movement and lengthens treatment times. Different therapy modalities have been described with varying degrees of efficacy in animal and clinical research to shorten the duration of treatment. The use of lasers or electrical stimulation, piezocision, vibration corticision, corticotomies, are a few of these techniques.⁹

In order to avoid the issues that are frequently associated with the use of dental anchorage, orthodontic temporary anchorage devices (TADs) can offer skeletal anchorage for mandibular molars protraction.¹⁰

The substantial density of mandibular bone makes it difficult for the mandibular molars to protract. Without reciprocal retraction of the incisors or displacement of the dental midline, anterior dental anchoring is sometimes insufficient to protract even a single first molar. Furthermore, safe and efficient protraction might not be achievable if the buccal and lingual cortical plates in the edentulous region have collapsed.¹¹ Power arms placed in auxiliary buccal tubes, are close to the point of resistance and can be used to translate the molars without mesial tipping.^{12–17}

This study was carried out to make an attempt to evaluate whether molar protraction in subjects with missing mandibular Ist molar in knife-edge ridges is possible or not using ridge split procedure.

2. Materials and Methods

The Seema Dental College and Hospital in Rishikesh was the site of the current clinical study to assess rate of molar protraction in subjects with missing mandibular Ist molars. 12 subjects were included in the study without any gender consideration. Ridge split was performed in selected subjects and molar protraction was carried out using temporary anchorage device.

2.1. Selection criteria

In the study subjects with missing mandibular Ist molars were selected by convenient sampling method. Subjects were selected from the Out Patient Department (OPD) of Seema Dental College and Hospital, Rishikesh, Uttarakhand, India. A total of 50 subjects were clinically

examined for the purpose of study and after fulfilling the selection criteria only 19 subjects were included in the study. Out of 19, two subjects refused for ridge split procedure two subjects did not follow the proper appointments and three subjects were reported with multiple breakages and loosening of implants. Hence, the final sample consisted of 12 subjects. Data was collected after every 6 weeks to assess molar protraction.

2.2. Inclusion criteria

1. Subjects not suffering from any debilitating illness such as Juvenile Diabetes or Leukemia
2. Subjects above 14 years of age.
3. Subjects with the knife-edge ridge in the mandibular first molar region.
4. Patients with missing mandibular first molar.
5. Patients on 0.019x0.025 stainless wire after leveling and alignment.

2.3. Exclusion criteria

1. Age below 14 years.
2. Non-compliant patient.
3. Growing patients who could be treated with functional therapy.
4. Subjects with missing mandibular second molars.
5. History of previous orthodontic treatment.
6. Selected subjects were advised for fixed orthodontic mechanotherapy.

Pre surgical preparation of sample – The following records of the patient were taken-

1. Lateral Cephalogram and OPG
2. IOPAR
3. Intraoral Photographs
4. Impressions
5. Coil spring

2.3.1. Surgical preparation of the sample

The surgical process involved in the procedure was explained and a written consent was obtained from the subjects and their parents. Subjects were prepared for the Ridge split procedure. Subjects were advised to get the following blood investigations done as the procedure involved surgery-

1. Bleeding time
2. Clotting time
3. Total leucocyte count
4. Differential leucocyte count
5. Haemoglobin percentage
6. Blood sugar examination
7. Examination for specific antibodies such as Hb_sAg and HIV for Hepatitis and AIDS

2.4. Methodology

A total of 50 subjects were clinically examined in the OPD of Seema Dental College and Hospital for missing mandibular first molar. Data was obtained from the primary source by directly asking the subject. Data obtained was quantitative in nature. Data was collected at a fixed interval of 6 weeks in the edentulous mandibular first molar region. Fixed mechanotherapy using Pre adjusted edgewise 0.022 prescription was advised for selected subjects.

Leveling and alignment was carried out in selected subjects. The Lower lingual holding arch was fabricated using 0.007 inches stainless steel wire and soldered on the band of mandibular second molars contralateral to the side of protraction and the lingual holding arch was kept unsoldered/removable on the side of protraction to prevent any lingual rolling of molar and guiding its movement during protraction. Mandibular second molars which were in unfavourable position for protraction were uprighted to make them favourable for protraction.

2.5. Surgical procedure

Before the surgical procedure antibiotics and steroids were given intramuscularly and intravenously to the subjects. Local anaesthesia was administered (blocks and local infiltration). In order to retain the periosteum attachment surrounding the buccal and lingual bone, full thickness mucoperiosteal flaps were raised on the buccal and lingual aspects of cortical plates after making a midline incision in the edentulous area. Under saline irrigation, a straight fissure bur was used to cut the narrow crest along the horizontal osteotomy line. Osteotomy line was further deepened, and ridge splitting was performed in the 1st molar region. Closure of flap was done using 4-0, 3-0 black thread sutures (Ethicon). Analgesics and antibiotics were prescribed to the subjects for five days. Subjects were recalled after seven days for suture removal.

2.6. Post-surgical

2.6.1. Implant placement

Mucosa was anaesthetized using topical anaesthetic aerosol spray. A Template was prepared for implant placement. Pre-operative IOPAR was taken. Implant was placed at the junction of attached and free gingiva. Implant site was marked with a punch in the gingiva prior to the implant placement. Mini implants (Denticon) of 1.3 mm diameter and 8mm length was placed manually using implant driver on the buccal aspect between mandibular first and second premolar at an angulation of 45° to occlusal plane.

2.6.2. Molar protraction

After initial leveling and alignment in the mandibular arch and completion of the ridge slit procedure molar protraction was started. Continuous rectangular 0.016x0.022 stainless

steel (Tandem wire i.e. 0.022 in anterior section and 0.016 in posterior section) was placed to carry out molar protraction. 0.019x0.025 stainless steel wire was used to design the power arms, which were then put into the second molar's auxillary tube. By providing 150gms of force from the implant to the power arm/post that was positioned in relation to the mandibular second molar utilizing power chains, molar protraction was initiated two days following the ridge split surgery.

2.7. Data collection

2.7.1. Assessment of mesial displacement and rate of molar protraction

Intraorally, the horizontal space between contact points of second premolar and second molar was recorded to 0.01 mm with a vernier calliper after protraction of second molar and the protraction rate in this instance was obtained by dividing the two variables i.e. distance and time.

2.7.2. Determination of change in angulation of second molar

The panoramic radiographs were taken before and after the protraction. A reference plane is constructed by a tangent to the lower border of the mandible and joining two orbitale points of left and right side. Two reference points were determined as described by Bansal et al¹⁸ formed by drawing mesial and distal cusp tips of lower molar (MD). A perpendicular bisector (MDP) of the line MD extending to the line drawn at lower border of mandible. Axial inclination of molars were measured on preoperative and post-operative orthopantomograms. The difference of angles measured suggested the amount of tipping encountered during protraction.

3. Results

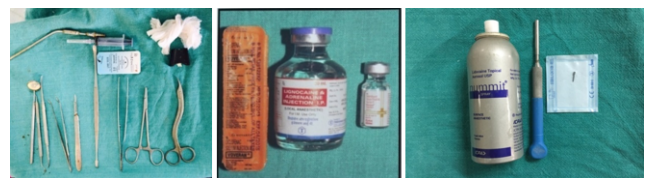

Figure 1: Surgical armamentarium Pre anaesthetic medication and Implant Kit

4. Discussion

Adults lose their mandibular first molars the most commonly. An alternative to restoration with fixed partial dentures or posterior dental implants is molar protraction. It is much harder to prevent anchor loss in the mandible

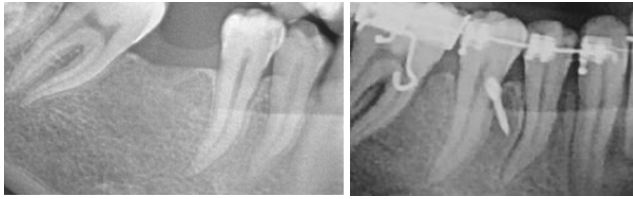

Figure 2: Intraoral periapical radiograph before and after implant placement

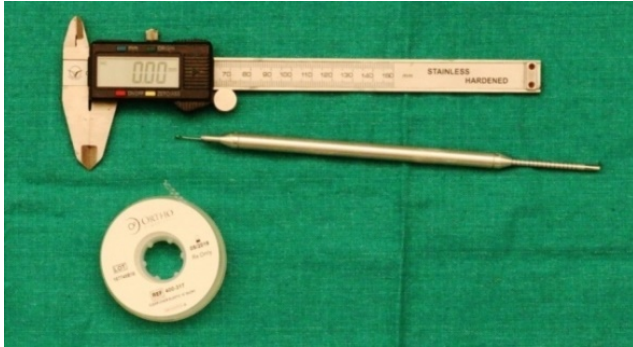


Figure 3: Vernier calliper, dountrix guage.




Figure 4: Armamentarium used for tracing

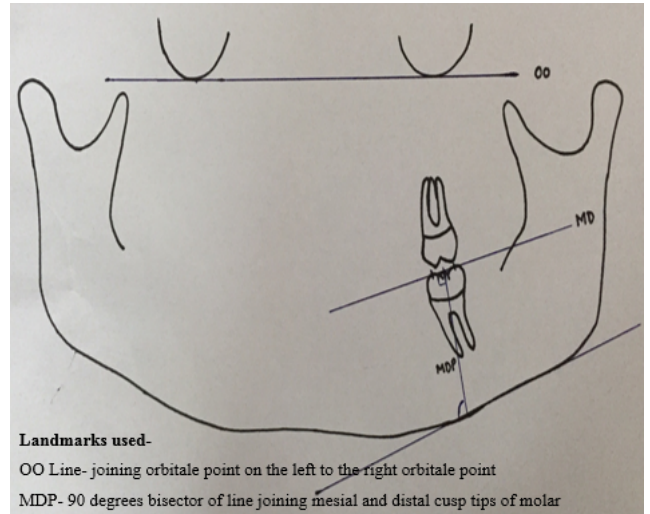


Figure 5: OPG tracing for assessment of tipping of molar

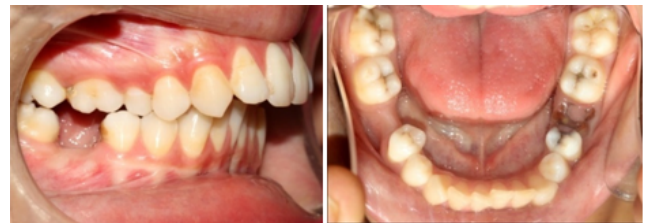

Figure 6: Pre treatment intraoral photographs

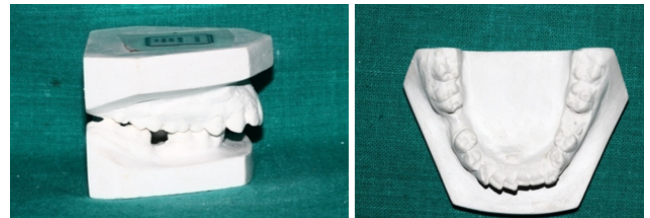


Figure 7: Pre-treatment study model

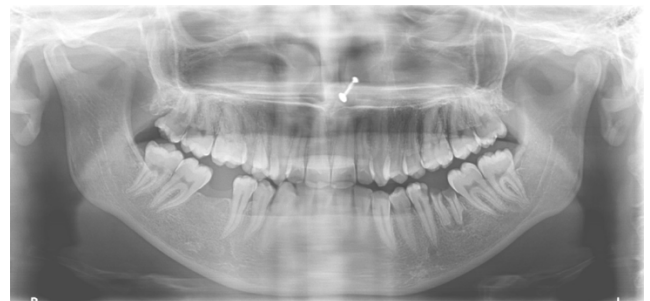


Figure 8: Pre-treatment OPG

Table 1: Mean Edentulous space using repeated-measures ANOVA test

Edentulous space	Mean	Std. Deviation	F-value	p-value
Pre protraction	7.67mm	3.00mm	55.742	< 0.001*
First visit	6.92mm	3.09mm		
Second visit	5.47mm	2.60mm		
Third visit	4.01mm	2.82mm		

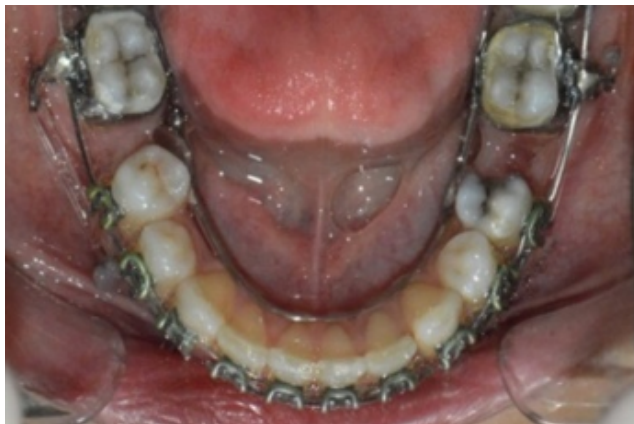

Figure 9: Power arm and lingual arch fabrication

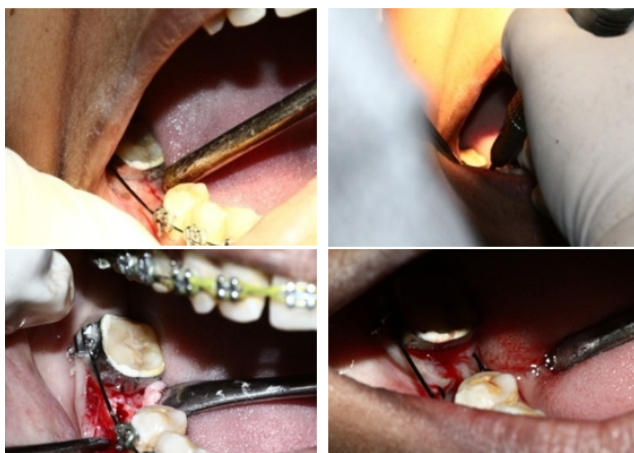

Figure 10: Ridge splitting procedure

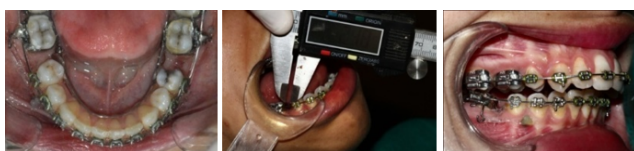

Figure 11: Protraction mechanics

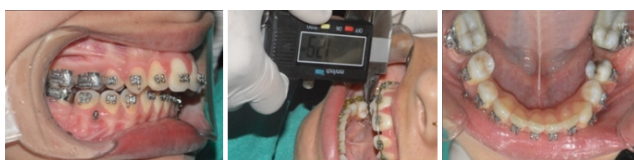


Figure 12: Protraction measured after 6 weeks Occlusal view after complete molar protraction

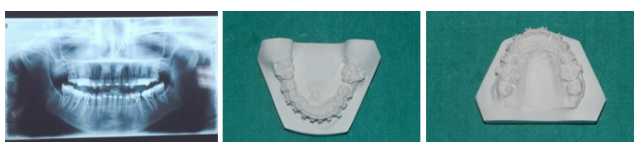

Figure 13: Post protraction OPG and study model

Table 2: Inter-interval comparison of mean edentulous space using the Post-hoc bonferroni test.

Inter-interval comparison			Mean Difference	p-Value
Pre protraction	Vs.	I visit	0.75mm	0.003*
Pre protraction	Vs.	II visit	2.20mm	< 0.001*
Pre protraction	Vs.	III visit	3.66mm	< 0.001*
I visit	Vs.	II visit	1.45mm	0.011*
I visit	Vs.	III visit	2.91mm	< 0.001*
II visit	Vs.	III visit	1.46mm	< 0.001*

Table 3: Assessment of mesial tipping /angular changes in molar using Paired t-test

	Angulation of molar				p-value
	Mean	Std. Deviation	Mean difference	t-test value	
Pre protraction	93.58	9.69	2.10	1.556	0.148
Post protraction	91.48	8.58			

Table 4: Assessment of rate of molar protraction using Repeated measure ANOVA test

	Rate of protraction per month			
	Mean	Std. Deviation	F-value	p-value
Pre protraction	7.67	3.00		
First visit	4.61	2.06		
Second visit	3.65	1.73	47.350	< 0.001*
Third visit	2.67	1.88		

Table 5: Inter-interval comparison of mean rate of protraction per month using Post-hoc bonferroni test

			Mean Difference	p-value
I Visit vs	II visit		0.97	0.011*
I visit vs	III visit		1.94	< 0.001*
II visit vs	III visit		0.97	< 0.001*

than it is in the maxilla, in part because of the anatomical variations between the two jaws¹¹The posterior mandible is made up of thicker cortical bone with dense, radially oriented trabeculae, as opposed to the posterior maxilla, which is made up of uniformly thin cortices connected by a network of wide trabeculae.¹¹In comparison to maxillary molars, mandibular molars are more difficult to move mesially due to the mandible's thick cortical bone and large buccolingually orientation of molar roots, Nagaraj (2008) claims that mandibular molars are more difficult to shift mesially.¹

The main goals of technological advancements in orthodontics are to shorten treatment duration, lessen postoperative discomfort, and improve periodontal health.¹¹

Stepovich (1979)¹⁹ and Hom and Turley(1984)²⁰evaluated the changes in edentulous

mandibular ridge prior to and after closure of lower first molar space by second molar mesialization. They found an increase in the buccolingual width of the alveolar ridge as the second molar moved anteriorly, 1–2 mm of mean crestal bone loss mesial to second molars, and insignificant root resorption. Both studies indicated that orthodontic space closure by second molar protraction in adults was effective and offered a potential solution in management of missing mandibular first molars. The edentulous ridge undergoes resorption with time after extraction of teeth. This makes things more difficult and extends the treatment duration.²¹ Thin alveolar ridges continue to be a major barrier to protraction, especially in the posterior jaw. Numerous methods, including guided bone augmentation using membranes and traditional grafting of bone can be used to treat knife-edge ridges. Ridge splitting was used in our investigation to create lateral ridge expansion by inserting the buccal cortex laterally. Khosshal et al (2013).²²

Ridge splitting is more efficient when there is cancellous bone present between thick outer cortical plates, the edentulous span is long enough, and the bone height is sufficient. In our study, a midline incision on the edentulous ridge was followed by the raising a full thickness mucoperiosteal flap on the buccal and lingual sections of the cortical plates. Better healing was facilitated by relocating the pieces and preserving the periosteum. The horizontal osteotomy line was cut along the thin crest using a straight fissure bur under saline irrigation. The osteotomy line was deepened and ridge was split was performed in 1st molar region. For irrigation, normal saline and betadine were utilized. The flap was closed with black thread sutures (Ethicon) in sizes 4-0 and 3-0. Analgesics and antibiotics were advised. Khosshal et al (2013).²²

Due to their convenience compared to dental implants, titanium screws have recently gained popularity for absolute anchorage throughout various types of tooth movement.¹ One major drawback of molar protraction utilizing traditional mechanics is the loss of anterior anchorage. Miniscrews have shown to be effective in maintaining the anchorage and ensuring optimal tooth motions. According to the research done by Gaur et al (2016)⁸ miniscrews were inserted in the area between two premolars at the level of apical thirds. A loading force of 150-200gms was maintained during active therapy and measured with the use of Dontrix gauze.²³ In our investigation, buccally inserted implant loosening was seen. In comparison to the maxilla, the mandible has a higher TAD failure rate. Bone density (or bone quality), peri-implant soft tissue health, sufficiency of peri-implant bone stock, and operator technique are the main biological aspects that affect miniscrew stability. The increased failure rate of mandibular miniscrews is due to root proximity (or insufficient peri-implant bone stock) and buccal tissue movement.¹²

In order to prevent unwanted moments like mesiolingual rotation, posterior cross bite, and open bite inclination, a lingual force is needed for direct protraction from the miniscrew.²³ In our study lower lingual holding arch was fabricated using 0.007 inches stainless steel wire and soldered on band of mandibular second molars contralateral to side of protraction and lingual holding arch was kept unsoldered/removable on the side of protraction to prevent any lingual rolling of molar and guiding its movement during protraction. Which is consistent with the work done by Kravitz (2008)¹⁹ and Baik (2012)²¹ In our study double tube molar tubes were placed in the mandibular second molar. Power arms were designed with 0.019x0.025 stainless steel wire and inserted in second molar's auxiliary tube. Continuous rectangular 0.016x0.022 stainless steel (Tandem wire i.e. 0.022 in anterior section and 0.016 in posterior section) was placed to carry out molar protraction. Placement of 0.022 in the anterior segment enhanced the anterior dental anchorage and 0.016 in posteriors allowed the protraction of second molar by sliding mechanics.

Rate of Molar Protraction- Gross skeletal morphology (bone density) of the alveolar process is inversely related to the rate of tooth movement. Histological analyses had revealed that the velocity at which the tooth moves is limited by the linear rate of resorption at the PDL/bone interface. It has been proposed that cortical bone is more resistant to resorption than trabecular bone because of lack of internal vascularised spaces.²⁴

Acc to Roberts et al (1996)²⁴ and Bhagat et al (2014)¹² The apparent radiographic density of the resistant alveolar bone is inversely correlated with the velocity of mandibular molar translation. The average amount of edentulous space that remained after three visits was 2.67 1.88mm, 3.65 1.73mm, and 4.61 2.06mm, suggesting a tooth movement rate of 0.9mm each month contrary to the findings of the investigation conducted by Roberts et al²⁴ in which the rate of molar protraction was 0.34mm over the last 12 months of space closure using retromolar dental implants. As shown in Table 3 the mean edentulous space has decreased from first visit to second visit at a faster rate from 6.92mm to 5.47mm with a standard deviation of 3.09mm in accordance with the study done by Uribe et al¹¹ which suggests that after corticotomy accelerated tooth movement is observed for at least 2-3 weeks and the exaggerated response tapers to normal steady state by 11 weeks of surgery.

Protraction was started on the third day of ridge split procedure with high force magnitude of 150-200gms to achieve bodily translation of molar. Greater force magnitudes are advised following corticotomy, quick activation and frequent activation schedules should be used to achieve optimal molar protraction.¹¹ A dramatic decrease in the rate of tooth movement was noted after second molars had moved mesially a few millimetres in consistent with the study done by Roberts et al.¹² The 1st visit, 2nd visit,

and 3rd visit all had significantly different mean rates of protraction per month, as demonstrated in Table 4 from the interval comparison of mean rate of protraction per month.

4.1. Angular changes/mesial tipping in molar

The posterior cross bite and open bite can be produced by direct protraction from a miniscrew that is lateral and inferior to the arch wire. Because molars can swiftly swing into cross bite, a balanced lingual force is crucial while protracting the terminal tooth in the arch. Kravitz (2008)¹¹ describes the usage of a sliding band with a helmet tube connected to its lingual arch and a lingual arch soldered to the molar band on the side opposite the lone molar surface. Through this tube, the lingual arch extends and serves as a guide for protraction. The mechanics employed in our investigation to stop mesial unintentional tooth movement are consistent with those proposed by Kravitz. According to Janakiraman (2016),¹⁹ mesial tipping of the molar occurs when force is exerted from the micro implant above the molar's center of resistance during the initial phase of protraction. As shown in Table 5 the mean angulation of molar pre protraction was 93.58±9.69 deg and after protraction was 91.48±8.58 deg with a mean difference of 2.10 deg of mesial tipping in molar during protraction. On comparison of the mean values of angulation of molar pre protraction and post protraction, A p value of 0.148 indicates that the mean difference, which is 2.10mm, is not statistically significant.

4.2. Duration of molar protraction

In adults the duration for space closure by 2nd molar protraction ranges from 2 to 4 years, as the rate of tooth movement is dependent on the density of bone, turnover rate, and hyalinization of the periodontal ligament. In our study it was noted that the remaining mean edentulous space pre protraction was 7.61mm with a standard deviation of 3.00mm. The rate of molar protraction was achieved at a rate of 0.9mm per six weeks and 0.15 mm per week which is in contrary with the study done by Roberts et al (1996)²⁴ where mesial movement was achieved at a rate of 0.60mm per month for the first eight months and then decreased to about 0.34mm per month. Thus total duration for protraction was approximately 8.4 months which is in contrary with study done by Uribe et al (2013)¹¹ It can be concluded that ridge split enhanced the tooth movement, utilization of mini implants provided absolute anchorage for molar protraction which in turn had shortened the duration of procedure.

5. Conclusion

The results obtained from the study were evaluated and several conclusions were made -

1. Ridge split procedure enabled the protraction of 2nd molars into missing 1st molar edentulous space in

individuals with knife edge ridges.

2. There is significant decrease in mean edentulous space from 1st visit to 2nd visit and from 2nd visit to subsequent 3rd visit.
3. It was concluded that the mean rate of protraction was 0.9mm per six weeks and 0.12mm per week.
4. The duration for molar protraction by ridge split procedure was 8.4 months approximately.
5. Molars were found to be mesially inclined post protraction by 2.10degrees which is not significant.
6. Molar protraction with mini implants enhanced the anterior dental anchorage and brought about the protraction of molar faster than conventional mechanics.

6. Source of Funding

None.

7. Conflict of Interest


None.


References

1. Nagaraj K, Upadhyay M, Yadav S. Titanium screw anchorage for protraction of mandibular second molars into first molar extraction sites. *Am J Orthod Dentofacial Orthop.* 2008;134(4):583–91.
2. Roberts WE, Marshall KJ, Mozsary PG. Rigid endosseous implant utilised as anchorage to protract molars and close an atrophic extraction site. *Angle Orthod.* 1989;60(2):135–52.
3. Katta A, Karthik K, Vannala V, Kumaran K, Peddu R, Dasari V, et al. Mandibular Second Molar Protraction with Temporary Anchorage Devices—A Case Report. *Int J Dent Sci Res.* 2014;2(6A):1–4.
4. Zimmer B. Wisdom tooth eruption secondary to localized lower molar mesialization in patients with aplastic lower second premolars. *J Orofac Orthop.* 2006;67(1):37–47.
5. Upadhyay M, Yadav S. Mini-implants for retraction, intrusion and protraction in a Class II division 1 patient. *J Orthod.* 2007;34(3):158–67.
6. Kravitz ND. Mandibular molar protraction with temporary anchorage devices. *JCO.* 2008;42(6):351–5.
7. Lindskog-Stokland B, Hansen K, Ekestubbe A, Wennström JL. Orthodontic tooth movement into edentulous ridge areas—a case series. *Eur J Orthod.* 2013;35(3):277–85.
8. Gaur A, Verma S, Maheshwari S, Anjum A. Miniscrew-Assisted Mandibular Molar Protraction: A Case Report. *J Adv Res Dent Oral Health.* 2016;1(1).
9. Sharma A. Restorative - Orthodontics: Is This An Option? . *J Clin Diagn Res.* 2011;5(2):396–8.
10. Furquim BD, Henriques JFC, Janson G, Siqueira DF, Furquim LZ. Effects of mandibular protraction appliance associated to fixed appliance in adults. *Dental Press J Orthod.* 2013;18(5):46–52.
11. Uribe F, Janakiraman N, Fattal AN, Schincaglia GP, Nanda R. Corticotomy-assisted molar protraction with the aid of temporary anchorage device. *Angle Orthod.* 2013;83(6):1083–92.
12. Bhagat A, Goel M, Batra P, Chugh RK. Mandibular Molar Protraction with Orthodontic Temporary Anchorage Devices: A Case Report. *Indian J Clin Pract.* 2014;25(4).
13. Belleggia F, Rocci M, Barlattani A, Gargari M. Piezoelectric surgery in mandibular Split crest technique with Immediate implant placement: A case report. *Oral Implantol (Rome).* 2008;1(3-4):116–23.

14. Nihara J, Gielo-Perczak K, Cardinal L, Saito I, Nanda R, Uribe F, et al. Finite element analysis of mandibular molar protraction mechanics using miniscrews. *Eur J Orthod.* 2015;37(1):95–100.
15. Zhang W, Qu HC, Yu M, Zhang Y. Effects of Maxillary Protraction with or without Rapid Maxillary Expansion and age factors in treating Class III malocclusion: A meta analysis. *PLoS One.* 2015;10(6):e0130096. doi:10.1371/journal.pone.0130096.
16. Kim SJ, Sung EH, Kim JW, Baik HS, Lee KJ. Mandibular molar protraction as an alternative treatment for edentulous spaces: Focus on changes in root length and alveolar bone height. *J Am Dent Assoc.* 2015;146(2):820–9.
17. Janakiraman N, Alrushaid S, Upadhyay M, Nanda R, Uribe FA. Biomechanics of Lower Second-Molar Protraction Using a New Appliance. *JCO.* 2016;L(12):736–44.
18. Bansal A, Prakash AT, Deepthi, Naik A. A Noble, Easy and Conceptual Radiographic Analysis to Assess the Type of Tooth Movement (Molar Distalization). *J Clin Diagn Res.* 2015;9(8):22–5.
19. Stepovich ML. A clinical study on closing edentulous spaces in the mandible. *Angle Orthod.* 1979;49(4):227–33.
20. Hom BM, Turley PK. The effects of space closure of the mandibular first molar area in adults. *Am J Orthod.* 1984;85(6):457–69.
21. Baik UB, Chun YS, Jung MH, Sugawara J. Protraction of mandibular second and third molars into missing first molar spaces for a patient with an anterior open bite and anterior spacing. *Am J Orthod Dentofacial Orthop.* 2012;141(6):783–95.
22. Khoshhal M, Torkzaban P, Vafae F, Razaghi S. Mandibular Ridge Splitting and Gradual Bone Expansion Technique for Immediate Placement of Implant in the Posterior Thin Region: A Clinical Report. *Avicenna J Dent Res.* 2013;5(2):e19463. doi:10.17795/ajdr-19463.
23. Metzner R, Schweska-Polly R, Helms HJ, Wiechmann D. Comparison of anchorage reinforcement with temporary anchorage devices or a Herbst appliance during lingual orthodontic protraction of mandibular molars without maxillary counterbalance extraction. *Head Face Med.* 2015;11:22. doi:10.1186/s13005-015-0079-4.
24. Roberts. Rate of mesial translation of mandibular molars using implant-anchored mechanics. *Angle Orthod.* 1996;66(5):331–8.

Author biography

Anupa Rawat, Reader  <https://orcid.org/0009-0008-0322-5914>

P Narayana Prasad, Professor and Head  <https://orcid.org/0000-0001-7982-2848>

Tarun Kumar, Professor and Head  <https://orcid.org/0000-0003-0268-0946>

Tarun Sharma, Professor  <https://orcid.org/0000-0003-1370-1343>

Mansi Rawat, Private Practitioner  <https://orcid.org/0009-0004-5973-732X>

Gaurav Rathi, Assistant Professor  <https://orcid.org/0009-0005-7329-4155>

Sumit Joshi, Assistant Professor  <https://orcid.org/0000-0002-8539-4533>

Cite this article: Rawat A, Prasad PN, Kumar T, Sharma T, Rawat M, Rathi G, Joshi S. Ridge split assisted molar protraction. *IP Indian J Orthod Dentofacial Res* 2023;9(4):270-277.