



## Short Communication

# Comparison between two types of grids for placement of mini-screw implant in posterior maxillary segment

Abha Chansoria<sup>1,\*</sup>, Yogesh Gupta<sup>1</sup>, Varunjeet Chaudhary<sup>1</sup>, Neha Singh<sup>1</sup>,  
Jas Kirat Singh<sup>1</sup>

<sup>1</sup>Dept. of Orthodontics and Dentofacial Research, RKDF Dental College & Research Centre, Bhopal, Madhya Pradesh, India



### ARTICLE INFO

#### Article history:

Received 05-05-2023

Accepted 13-06-2023

Available online 08-09-2023

#### Keywords:

Grid

TADs

Customised mesh

Placement of TAD

Anchorage

### ABSTRACT

Use of mini-screw implants is in vogue. It has brought about a drastic change in day to day practise for orthodontists. Despite being the most popular source of anchorage, it is not easy for newer clinicians to perfectly figure out the site of implant placement and the accuracy by which it should be placed to avoid failure. A customised grid or mesh is the simplest way to gain assistance for placement of miniscrew implants. This article focuses on comparison of two types of grids for placement of implant accurately and to guide the clinician in such a way that minimises all the possible errors.

This is an Open Access (OA) journal, and articles are distributed under the terms of the [Creative Commons Attribution-NonCommercial-ShareAlike 4.0 License](https://creativecommons.org/licenses/by-nc-sa/4.0/), which allows others to remix, tweak, and build upon the work non-commercially, as long as appropriate credit is given and the new creations are licensed under the identical terms.

For reprints contact: [reprint@ipinnovative.com](mailto:reprint@ipinnovative.com)

## 1. Introduction

Determination of the anchorage consideration of each and every case before commencement of any procedure is of primary importance in orthodontic treatment. Further it is utmost important to determine whether the case requires burning of anchorage or whether no anchorage loss can be afforded with the particular treatment. After the determination of the type of anchorage that is aimed for the particular treatment i.e. minimum, moderate, absolute or critical, the source of anchorage can be decided upon. This could be either intra-oral or extra-oral, primary, compound, reciprocal or reinforced. Once the clinician ascertains it, the treatment plan becomes clearer and efficient.

In recent years, the use of mini-screw implants has gained a lot of popularity in orthodontic treatment. When establishing intra-oral site of anchorage, TADs can be used in cases of absolute anchorage i.e. when most of the extraction space has to be maintained for the retraction of anterior teeth. For newer clinicians,

practitioners and budding orthodontists, it may be a slightly tricky phenomenon to figure out the site of mini-screw implant placement, the procedure of placement, the size of implant that needs to be selected, retraction of the mini-screw implant and the complications that come along with the procedure.

Fabrication of a simply designed grid (mesh) is the easiest way to efficiently overcome the above mentioned parameters. This article focuses on the comparison of two types of grids for guiding the implant placement and to determine the more trouble-free one out of the two.

## 2. Materials Used

1. 0.017" x 0.025" SS wire (straight length)
2. 0.016" x 0.022" SS wire (straight length)
3. Spot welder
4. Cold cure acrylic
5. Wax sheet (Modelling wax)
6. Micromotor


\* Corresponding author.

E-mail address: [abhachansoria@gmail.com](mailto:abhachansoria@gmail.com) (A. Chansoria).

### 3. Appliance Fabrication


The *first type (with acrylic)*:- This type of grid used in the procedure is fabricated using 0.017" x 0.025" SS wire by following 6 essential steps mentioned as under.

1. A frame is made first with the help of 0.017" x 0.025" SS wire.
2. In this, vertical and horizontal piece of wires are welded at an equal distance of 2mm.
3. To make this easier and cut into the right size of pieces, the design is first made on a block of Plaster of Paris. This makes it convenient to establish its length and distance (Figure 1).
4. Wires are now welded with the help of the frame-work.
5. The final grid is obtained as shown in Figure 2A,B.
6. The mesh is embedded in an acrylic bed made of cold cure acrylic and the final design is obtained as shown in Figure 3.




**Fig. 1:** Frame work made on plaster of Paris.

While placing the grid intra-orally, a softened layer of wax has to be placed on the occlusal side of the acrylic bed in order to stabilise the mesh while shooting the radiograph (Figure 4). Further, an IOPA is taken using angle bisecting technique which helps to obtain an exact assessment of the site and location of the placement of the mini-screw implant. (Figure 5). A similar design has been fabricated by Narendra S Sharma et al.<sup>1</sup> which was fabricated by using a 24 gauge

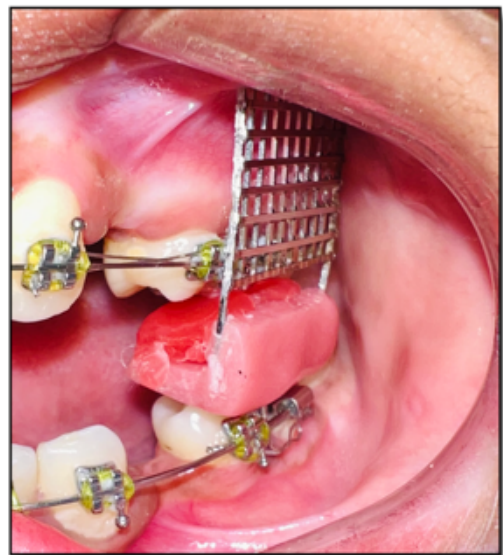

**Fig. 2:** A: After welding of wire; B: After welding of wire.



**Fig. 3:** Mesh embedded in cold cure acrylic.

straight stainless steel wire. The stainless steel wire was cut into pieces of 1 inch in length and was welded to form a column grid, in which each cell measured about 1.5 mm.

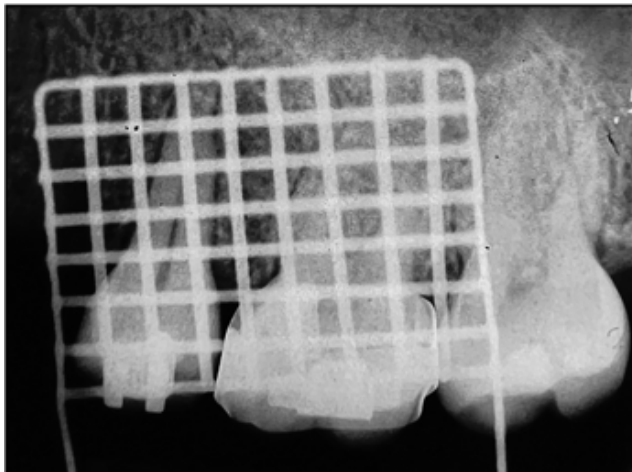


**Fig. 4:** Grid placed intra-orally along with modelling wax.

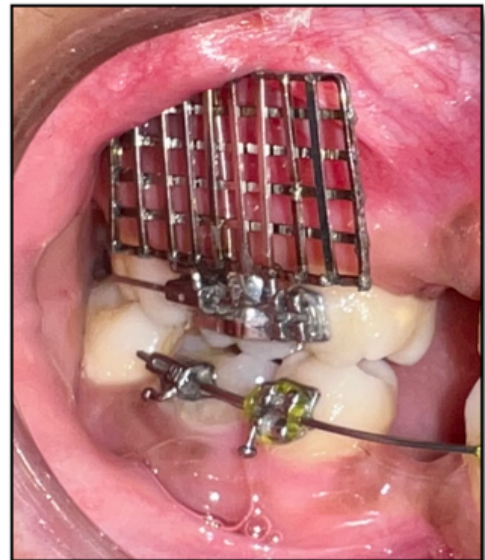The *second type (without acrylic)*: This type of mesh design is fabricated using 0.017" x 0.025" SS wire and the same sequence of steps is followed as mentioned in the

**Table 1:** Comparison of first and second type of grids


S.No.	First type	Second type
1	Can be used in all four quadrants in posterior region.	Can be used in all four quadrants with additional wire manipulation which may result in breakage of the wire.
2	Can be manipulated according to height of the vestibule because of the wax that is incorporated while intra-oral placement.	Can be manipulated according to the height of the vestibule but not multiple times as wire may require repeated bending and may lead to breakage.
3	Stability may be compromised if the patient doesn't bite in the same way while shooting the IOPA and while placing the implant.	Stability cannot be compromised since grid will be secured in the molar tube and premolar bracket firmly.
4	Removal of the grid is safe and doesn't cause any damage to the appliance.	Careful removal of the grid is required since it may lead to dislodgement of the molar band or the premolar bracket.
5	Patient compliance is of utmost importance with this type of grid due to the presence of wax sheet.	Patient cooperation is required but not as much as the first type.
6	Cannot be used in patients with allergy to acrylic material.	Allergic reaction is not possible.



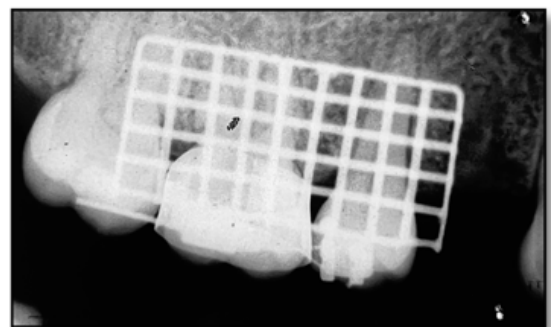
**Fig. 5:** IOPA of 56 region with grid in place.



**Fig. 7:** Grid in place intra-oral.

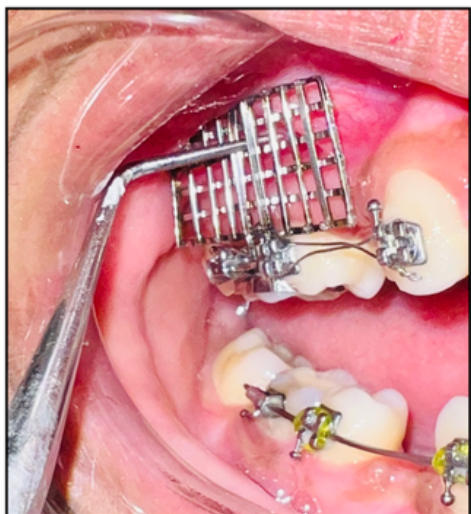

**Fig. 6:** A: 0.016'' x 0.022 wires welding horizontally; B: 0.016'' x 0.022 wires welding horizontally.

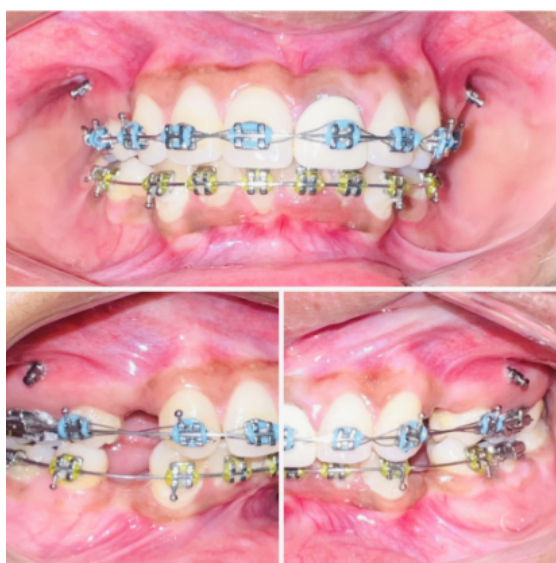

**Fig. 8:** IOPA of 56 region with grid in place.

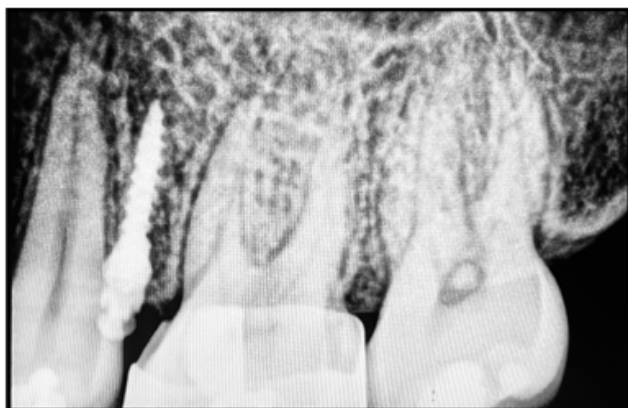




**Fig. 9:** Marking the site of placement of implant.



**Fig. 10:** After placement of mini-screw implant in patient (Ekta 24/F).



**Fig. 11:** Confirmation of position of implant after placement.

previous method. Except, this frame is made rectangular in shape and care is to be taken that it does not extend any further than the last welded wire. It has previously been made by Khan W et al.<sup>2</sup>

1. After getting a rectangular mesh of 20 x 10 mm, two wires of 0.016" x 0.022" SS are welded horizontally along the 5<sup>th</sup> and 6<sup>th</sup> horizontal wires (Figure 6 A and B).
2. While placing the grid intra-orally, the distal wire is bent at the level of the molar tube to be inserted into the molar and the mesial wire is bent to be inserted in the premolar bracket (Figure 7).
3. A radiograph was taken with the grid in place (Figure 8).

### 3.1. Determination of site / location of implant placement

There have been multitudinous studies regarding the location of placement of the implant in the inter-radicular spaces.<sup>3</sup> The most convenient site for placement of implant in the buccal area of the maxilla is between the distal side of the root of the second premolar and the mesial side of the root of the first molar.<sup>4</sup> The minimum inter-radicular distance required in this region i.e. the posterior maxilla is 3 mm which is also considered as the "safe zone" for placement of the screw.<sup>5</sup> Having noted that, it's also important to determine whether the implant is placed on the palatal side or the buccal side. The clearance from the alveolar bone should be between 5mm - 11mm.<sup>6</sup>

The following is the order of the safer sites available in the interradicular spaces of the posterior mandible:<sup>6</sup>

1. Interradicular spaces between the second and first molar.
2. Interradicular spaces between the second and first premolar.
3. Interradicular spaces between the first molar and second premolar at 11 mm from alveolar crest.
4. Interradicular spaces between the first premolar and canine at 11 mm from the alveolar crest.

According to the grid made, the determination of placement site is done and a punch is made with the help of a sharp probe (Figure 9), followed by which the grid was removed.

## 4. Conclusion

Use of grid (mesh) is a tool for making the process of implant placement a tad bit easier. The ease of determining the location helps in minimising the errors during placement which may ultimately lead to failure of the implant. Position of grid while taking the IOPA and while placement of the implant should be the same to avoid any complications. At the same time, it is of essence to note that complete

care and precautions must be taken into consideration while placing the implant. Proper sterilisation protocol must be maintained. After establishment of site, radiograph must be taken to confirm the preciseness of location of the implant. Care must be taken to avoid post-surgical complications that may occur.

## 5. Source of Funding

None.


## 6. Conflict of Interest

None.


## References

- Sharma NS, Shrivastav SS, Hazarey PV, Kamble RH, Sharma PN. *World J Dent.* 2013;4(1):74–6. doi:10.5005/jp-journals-10015-1206.
- Khan W, Shetty P, Gajapurada J. A New Guiding Template for Mini-Implant Placement in Orthodontics. *J Indian Orthod Soc.* 2018;52(3):219–20.
- Singh K, Kumar D, Jaiswal RK, Bansal A. Temporary anchorage devices -Mini-implants. *Natl J Maxillof.* 2010;1(1):30–4.
- Nanda R. *Temporary Anchorage Devices in Orthodontics.* London, Netherlands: Elsevier; 2009.
- Chaimanee P, Suzuki B, Suzuki EY. “Safe Zones” for miniscrew implant placement in different dentoskeletal patterns. *Angle Orthod.* 2011;81(3):397–403. doi:10.2319/061710-111.1.
- Poggio PM, Incorvati C, Velo S, Carano A. "Safe zones": A guide for miniscrew positioning in the maxillary and mandibular arch. *Angle Orth.* 2006;76(2):191–7. doi:10.43/0003-3219(2006)076[0191:SZAGFM]2.0.CO;2.

## Author biography

**Abha Chansoria**, -  <https://orcid.org/0000-0003-0496-140X>

**Yogesh Gupta**, Professor and HOD

**Varunjeet Chaudhary**, Reader  <https://orcid.org/0000-0002-0278-1029>

**Neha Singh**, -

**Jas Kirat Singh**, Reader

**Cite this article:** Chansoria A, Gupta Y, Chaudhary V, Singh N, Singh JK. Comparison between two types of grids for placement of mini-screw implant in posterior maxillary segment. *IP Indian J Orthod Dentofacial Res* 2023;9(3):217-221.