

Content available at: <https://www.ipinnovative.com/open-access-journals>

IP Indian Journal of Orthodontics and Dentofacial Research

Journal homepage: <https://www.ijodr.com/>

## Case Report

# Management of skeletal Class III malocclusion using two-phase therapy in young patient - A case report

Irfanul Haque<sup>1</sup>, Raghu Ranjan Prasad<sup>1</sup>, Priyanka Kumari<sup>1</sup>, Parul Priya<sup>1</sup>,  
Abhay Kumar Jain<sup>2,\*</sup>

<sup>1</sup>Dept. of Orthodontics and Dentofacial Orthopedics, Hazaribag College of Dental Sciences and Hospital, Hazaribag, Jharkhand, India

<sup>2</sup>Dept. of Orthodontics and Dentofacial Orthopedics, Dental College, RIMS, Ranchi, Jharkhand, India



## ARTICLE INFO

### Article history:

Received 10-07-2023

Accepted 02-08-2023

Available online 08-09-2023

### Keywords:

Class III malocclusion

Face mask therapy

RME

Orthopedic correction

Two phase therapy

## ABSTRACT

Maxillary and mandibular skeletal discrepancies are one of the commonly prevailing malocclusion in the childhood. Many a time it is ignored by the parents as well as the clinicians. It can present itself with aesthetic, functional and psychological problems of the child. Proper identification, diagnosis and treatment planning at the proper age can lead to correction and improvement in the overall facial balance and psychological esteem of the child. Over the years orthopedic and myofunctional appliances has been used to correct Class II and Class III skeletal malocclusion in a growing child. Face mask therapy with RME has been used as treatment choice to treat a patient with skeletal Class III malocclusion. Orthopedic correction in the early stage of life can eliminate the severity and further complex treatment modalities in the later stages of life. This case report describes the treatment of male child aged 12 years who had skeletal Class III malocclusion with maxillary deficiency. The treatment was done in two phases; orthopedic correction was done initially using RME Facemask followed by fixed orthodontic correction. There was overall improvement in the facial profile and occlusion of the patient post treatment.

This is an Open Access (OA) journal, and articles are distributed under the terms of the [Creative Commons Attribution-NonCommercial-ShareAlike 4.0 License](https://creativecommons.org/licenses/by-nc-sa/4.0/), which allows others to remix, tweak, and build upon the work non-commercially, as long as appropriate credit is given and the new creations are licensed under the identical terms.

For reprints contact: [reprint@ipinnovative.com](mailto:reprint@ipinnovative.com)

## 1. Introduction

Class III malocclusions are one of the less common type of malocclusion, yet they are often more complicated to treat.<sup>1</sup> It may occur as a result of skeletal and dental discrepancies leading to esthetic and facial impairment.<sup>2</sup> Underlying cause for Class III malocclusion may be : 1) retrognathic and/or small maxilla; 2) prognathic and/or large mandible; 3) combination of both jaw discrepancies.<sup>3,4</sup> It has a multifactorial etiology involving genetic and environmental reasons.<sup>5</sup> Prevalance of Class III malocclusion in Asian population ranges between 4% to 13%.<sup>6</sup> In Indian population prevalence reported of Class III malocclusion is

3.4%.<sup>7</sup> During the early phase of growth skeletal Class III patients with maxillary deficiency facemask or reverse pull headgear can contribute to the correction by application of orthopedic forces. So, early intervention is needed to obtain a more normal jaw relationship.<sup>8</sup>

Face mask consists of a metal framework which sits in front of the patients face with the support from the forehead and chin. Elastics are connected to the metal bar and the teeth - directly through intraoral appliances in the patient. The elastics apply forward and downward forces on the maxilla. Thus the force direction is the opposite from a standard headgear which is why this appliance is also known as a reverse-pull-headgear.<sup>9</sup> The facemask appliance needs to worn by the patient for 12 to 14 hours daily.<sup>10</sup> It is recommended that the age for effective treatment was

\* Corresponding author.

E-mail address: [docabhayjain@gmail.com](mailto:docabhayjain@gmail.com) (A. K. Jain).

ranges between 6 to 8 years (early mixed dentition) or 9 to 12 years (late mixed dentition).<sup>11</sup> Facemask along with rapid maxillary expansion (RME) to protract the maxilla has become a treatment protocol in cases with maxillary deficiency.<sup>12</sup> This article presents a case report of 12 years old boy having skeletal Class III malocclusion treated with facemask appliance followed by fixed appliance therapy.

## 2. Case Report

A 12-year-old male patient visited the Department of Orthodontics and Dentofacial Orthopedics with the chief complaint of forwardly placed lower front teeth.

No relevant medical or dental history was reported.

### 2.1. Clinical findings

#### 2.1.1. Extraoral

The patient had mesoprosopic facial form, mesocephalic head shape with a concave facial profile, anterior divergence with deficiency in maxillary projection, decreased clinical FMA, acute nasolabial angle, average mentolabial sulcus and a protuded chin. No gross facial asymmetry was noticed. (Figure 1)

#### 2.1.2. Intraoral

All teeth were present except 17,27. Patient had Angle's Class III molar and canine relation, anterior and posterior crossbite, negative overjet of -2 mm and overbite of 4mm. Ankyloglossia was seen.(Figure 2)

### 2.2. Cephalometric findings

#### 2.2.1. Skeletal

Class III jaw base due to retrognathic maxilla and prognathic mandible, horizontal growth pattern.

#### 2.2.2. Dental

Proclined upper anteriors, retroclined lower anteriors.

#### 2.2.3. Soft tissue

Acute nasolabial angle, protusive lower lip with average mentolabial sulcus.

#### 2.2.4. Growth status

CVMI stage 3.

#### 2.2.5. Panoramic radiograph

Showed erupting second molars in upper quadrant and unerupted third molars in all quadrants except fourth quadrant and incomplete root formation of canines, premolars of all quadrant and second molars of lower quadrant. (Figure 3)

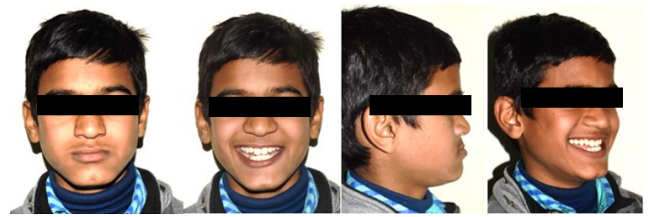

Fig. 1: Pre-treatment extra-oral photographs.

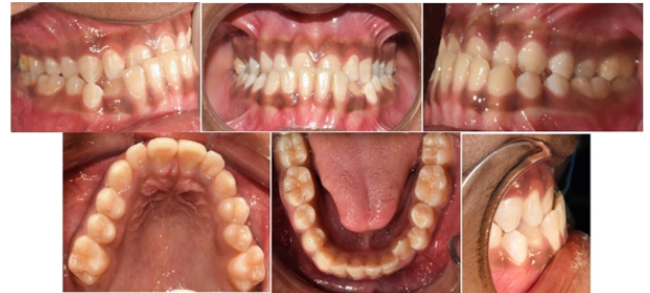

Fig. 2: Pre-treatment intra-oral photographs.

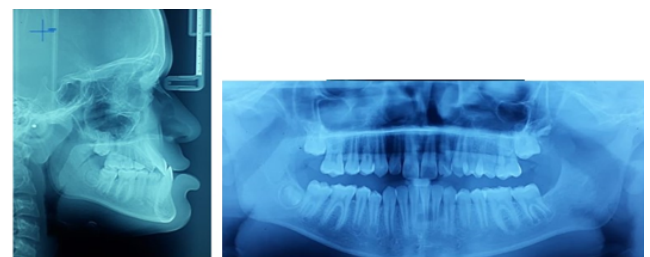

Fig. 3: Pre-treatment radiographs

## 3. Treatment Objectives

1. To correct the skeletal discrepancies.
2. To achieve normal incisor axial inclination.
3. To achieve Class I molar, canine and incisor relation.
4. To achieve ideal alignment of upper and lower teeth.
5. To achieve ideal overjet and overbite.
6. To achieve an esthetic and pleasing facial profile.

### 3.1. Treatment plan

Based on the clinical examination and cephalometric evaluation showing skeletal Class III due to maxillary deficiency and the growth remaining it was decided to treat this case by using orthopedic appliance. It was decided to use facemask to correct anteroposterior maxillary deficiency by protracting the maxilla and using expansion appliance as it disrupts the maxillary suture system and promotes maxillary protraction and to correct posterior crossbite simultaneously. After achievement of normal skeletal relationship followed by second phase of treatment with fixed orthodontic appliance for finishing and detailing

The treatment was carried out in two phases:

Phase I- Orthopedic correction with facemask and RME

Phase II - Dental correction and finishing and detailing with MBT prescription.

#### 4. Treatment Progress

##### 4.1. Phase I

The patient was given appliance which included protraction facemask and bonded maxillary splint (Haas type) with Hyrax screw (Leone, Italy). The expansion appliance was cemented and activation schedule of 1 turn in the morning was maintained for 3 weeks. In the expansion appliance hooks were incorporated on the buccal aspect near the permanent canines to engage the elastics for the facemask. After achieving the desired transverse dimension patient was asked to wear the facemask and the elastics. After a week facemask therapy was initiated with appliance worn for 12-14 hours a day. Initially force level was started at 200 g on each side which was later increased to 400 g after 2 weeks. The patient was asked to remove the appliance during eating and playing sports. The direction of the pull was downward and forward at an angle of around 30° to the maxillary occlusal plane. (Figure 4) The treatment duration of this phase was of 8 months. Appreciable clinical and radiographic changes were observed after phase I therapy. There was marked improvement in the profile of the patient (Figures 5 and 6) After the completion of active phase chin-cup was given for the retentive phase and subsequently during the fixed orthodontic treatment. (Figure 7)

##### 4.2. Phase II

Post orthopedic traction fixed orthodontic treatment was started. Preadjusted edgewise appliances 0.022" slot MBT prescription was used (Figure 8). Initial levelling and aligning was done using niti wires 0.014, 0.016 x 0.022", 0.017x 0.025 followed by stainless steel wire 0.019 x 0.025. Finishing and detailing with 0.016 ss wire and light Class III elastics were given to maintain the overjet correction. Patient was asked to wear chin cup during the entire fixed orthodontic phase. Active treatment duration was about 1 year and 2 months. After debonding, lingual bonded retainer was given in lower arch and wrap-on retainer in the upper arch and the patient was asked to wear it for 1 year. (Figure 9).

#### 5. Treatment Results

Post orthopedic and orthodontic treatment, improvement in facial profile was seen. Class I molar and canine relation was achieved with well aligned dental arches, normal overjet, overbite and matching midlines. Appreciable changes in the cephalometrics parameter of skeletal, dental and soft tissue was observed, evidenced by changes in

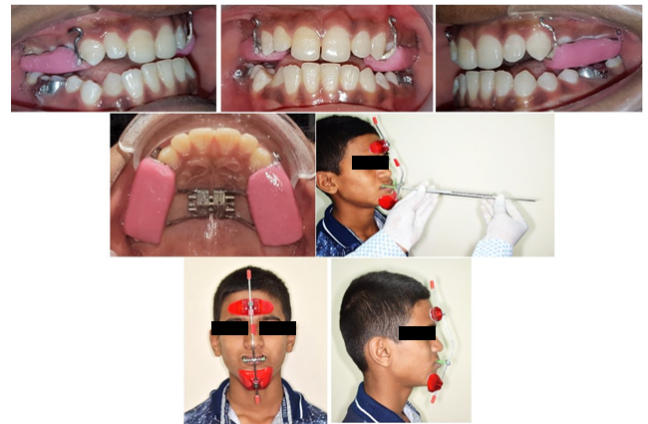

Fig. 4: Facemask with RME

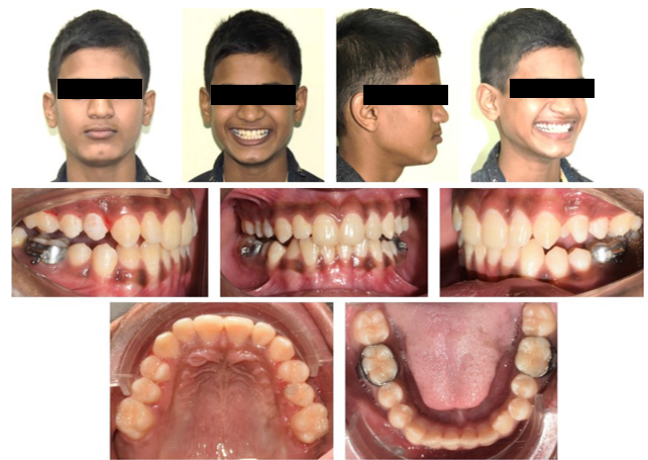

Fig. 5: Post-functional extra and intraoral photographs

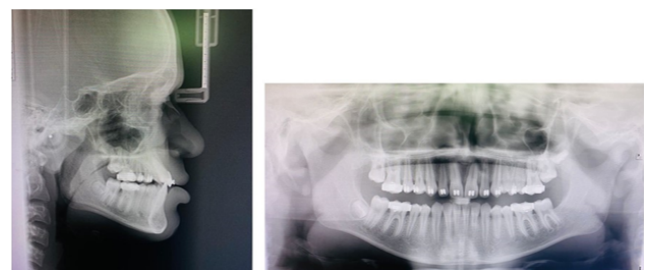


Fig. 6: Post-functional radiographs




Fig. 7: Post-functional retention using chin-cup

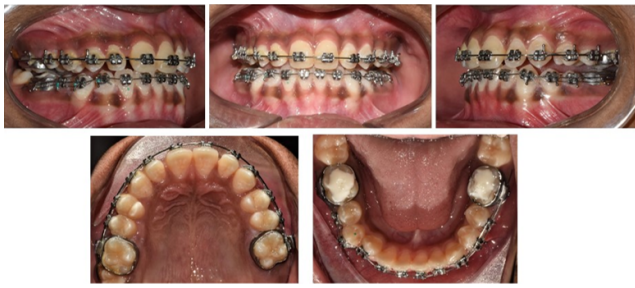

Fig. 8: Complete strap-up

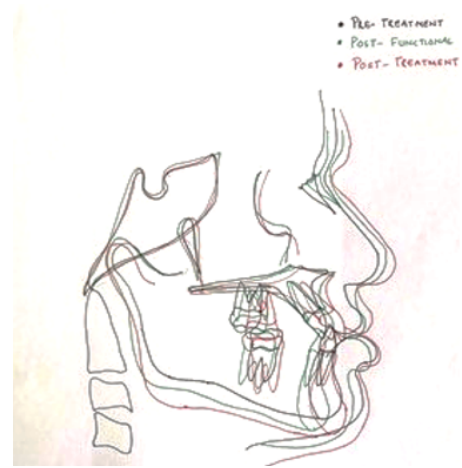


Fig. 11: Superimposition

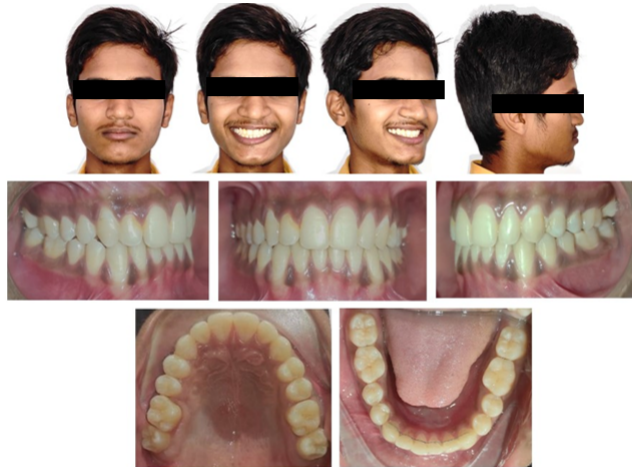

Fig. 9: Post-treatment extra-oral and intra-oral photographs.

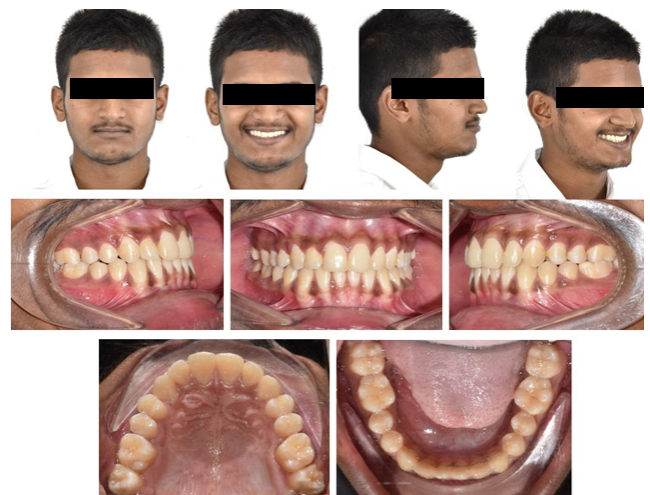

Fig. 12: Extra and intraoral photographs after one year follow-up.

ANB and Witts appraisal with increase in SNA angle. Improvement in the vertical skeletal measurements were also noted. (Figure 10). The comparison of pre-treatment, post-functional and post-treatment values are evident in Tables 1, 2 and 3. The cephalometric superimposition of the pre- and post-treatment radiographs were done which indicated favourable direction of patient growth towards class I skeletal and dental pattern. (Figure 11) After one year of follow-up the treatment changes and the profile of the patient were found to be stable. (Figure 12).

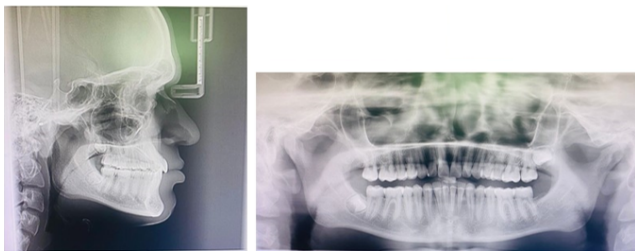


Fig. 10: Post-treatment radiographs

## 6. Discussion

While diagnosing the patient with skeletal imbalance age and growth stage is of utmost importance as the type and outcome of the treatment is dependent on it. When the patient is in the growth phase the intervention can be done using orthopedic or myofunctional appliances and desirable results can be seen.<sup>12,13</sup> Various studies has been reported on Class III malocclusion treatment during early growing phase where facemask with RME therapy has been used to correct maxillary deficiency and redirect mandibular growth.<sup>14</sup> A long term study stated the effects of maxillary expansion during facemask therapy, concluded that average anterior movement of point A post treatment was 1.54 mm, and that of maxillary teeth were 2.73 mm.<sup>15</sup>

In the present case, treatment was done in two phase therapy – in the first phase RME followed by facemask therapy to protract maxilla and later fixed orthodontic treatment for occlusal settling in the second phase. The

**Table 1:** Comparison of skeletal changes in sagittal plane

Variable	Pre-treatment	Post-functional	Post-treatment
SNA	83°	87°	87°
SNB	92°	87°	88°
ANB	-9°	0°	-1°
Wits	-9mm	-2°	-2°
Beta Angle	39°	30°	31°

**Table 2:** Comparison of skeletal changes in Vertical Plane

Variable	Pre-treatment	Post-functional	Post-treatment
Go-Gn to SN	26°	28°	28°
Y-Axis	58°	60°	60°
Basal plane angle	26°	27°	27°
Jaraback Ratio	72.8%	70%	70%
FMA	24°	25°	26°

**Table 3:** Comparison of dento-alveolar and soft tissue changes

Variable	Pre-treatment	Post Functional	Post-treatment
U1 to NA (Angle)	28°	33°	32°
U1 to NA (mm)	7mm	8mm	8mm
U1 to SN	107°	120°	115°
U1 to PP	118°	117°	115°
U1 to A-Pog	1mm	5mm	5mm
IMPA Angle	85°	86°	86°
L1-NB Angle	20°	15°	15°
L1-NB mm	17mm	15mm	15mm
Interincisal Angle	116°	132°	131°
L1 to A-Pog	5mm	4mm	3mm
Nasolabial Angle	78°	87°	88°
Lip Strain	0mm	2mm	1mm
Mentolabial sulcus	5mm	4mm	4mm
E-line to upper lip	-5mm	-1mm	-2mm
E-line to lower lip	2mm	2mm	1mm

skeletal growth pattern, age, appliance design and patient co-operation played a major role in correcting Class III malocclusion successfully.

## 7. Conclusion

Proper diagnosis and treatment mechanics is important to ensure better and long-term results in cases of skeletal discrepancies. If the predictable approach is done for a growing child, then effective skeletal dental and soft tissue outcome can be seen. Facemask with RME therapy given in cases of skeletal Class III patients during growth period modulates the active stages of craniofacial growth as well as dental development as shown in the case report.

## 8. Declaration of Patient Consent

The author certifies that he has obtained all appropriate patient consent forms. In the form, the patient has given her consent for her images and other clinical information to be reported in the journal. The patient understands that her name and initials will not be published, and due efforts

will be made to conceal their identity.

## 9. Source of Funding

The author received no financial support for the research, authorship, and/or publication of this article.

## 10. Conflicting of Interests

The author declared no potential conflicts of interest with respect to the research, authorship, and/or publication of this article.


## References

1. Nanda R. Biomechanics and esthetic strategies in clinical orthodontics. Elsevier Health Sciences; 2005.
2. Proffit WR. Contemporary Orthodontics, 4th edn. St. Louis: Mosby; 2007. p. 689–707.
3. Proffit WRF, Fields HW, Sarver DM. Contemporary Orthodontics, 5th Edn. India: Elsevier; 2012.
4. Guyer EC, Iii EE, Jr JM, Behrents RG. Components of Class III malocclusion in juveniles and adolescents. *Angle Orthod.*

- 1986;56(1):7–30.
5. Borzabadi-Farahani A, Borzabadi-Farahani A, Eslamipour F. Malocclusion and occlusal traits in an urban Iranian population. An epidemiological study of 11- to 14-year-old children. *Eur J Orthod.* 2009;31(5):477–84. doi:10.1093/ejo/cjp031.
  6. McNamara JA. An orthopedic approach to the treatment of Class III malocclusion in young patients. *J Clin Orthod.* 1987;21(9):598–608.
  7. Kharbanda OP, Sidhu SS, Sundaram KR, Shukla DK. Prevalence of malocclusion and its traits in Delhi children-I. *J Indian Orthod Soc.* 1995;26:98–103.
  8. Expanding limits for esthetic strategies by skeletal anchorage. In: Nanda R, editor. *Esthetics and Biomechanics in Orthodontics*. 2nd edn. Elsevier; 2015.
  9. Protraction facemask. Dr Sylvain Chamberland Orthodontiste. 2011-09-26. Retrieved 2019-08-18. Available from: <https://www.sylvainchamberland.com/en/appliances/protraction-facemask/>.
  10. Ozkalayci N, Cicek O. When Do Skeletal Class III Patients Wear Their Reverse Pull Headgears? *BioMed Res Int.* 2017;p. 1–5. doi:10.1155/2017/3546262.
  11. Ngan PW, Hagg U, Yiu C, Wei SHY. Treatment response and long-term dentofacial adaptations to maxillary expansion and protraction. *Semin Orthod.* 1997;3(4):255–64. doi:10.1016/s1073-8746(97)80058-8.
  12. Westwood PV, McNamara JA, Baccetti T, Franchi L, Sarver DM. Long-term effects of Class III treatment with rapid maxillary expansion and facemask therapy followed by fixed appliances. *Am J Orthod Dentofacial Orthop.* 2003;123(3):306–20. doi:10.1067/mod.2003.44.
  13. Surana A. IBO case report: Management of skeletal Class III malocclusion with combined rapid maxillary expansion: facemask therapy and 5-year follow-up. *J Ind Orthod Soc.* 2012;46(4):216–22.
  14. Gencer D, Kaygisiz E, Yüksel S, Tortop T. Comparison of double-plate appliance/facemask combination and facemask therapy in treating class III malocclusions. *Angle Orthod.* 2015;85(2):278–83.
  15. Williams MD, Sarver DM, Sadowsky PL, Bradley E. Combined rapid maxillary expansion and protraction facemask in the treatment of class III malocclusions in growing children: A prospective long-term study. *Semin Orthod.* 1997;3(4):265–74. doi:10.1016/s1073-8746(97)80059-x.


## Author biography

**Irfanul Haque**, Assistant Professor

**Raghu Ranjan Prasad**, Reader  <https://orcid.org/0000-0001-8866-2807>

**Priyanka Kumari**, Post Graduate  <https://orcid.org/0009-0008-4510-7692>

**Parul Priya**, Assistant Professor

**Abhay Kumar Jain**, Assistant Professor  <https://orcid.org/0000-0002-2457-8144>

**Cite this article:** Haque I, Prasad RR, Kumari P, Priya P, Jain AK. Management of skeletal Class III malocclusion using two-phase therapy in young patient - A case report. *IP Indian J Orthod Dentofacial Res* 2023;9(3):192-197.