



Case Report

A skillful combination of invisalign aligners followed with veneers: A case report

Gaurav Gupta^{1,2,*}, Anirudh Agarwal³, D.K Gupta⁴, Neeraj Chandra⁵, Priyanka Gupta⁶, Devanshi Sankhla⁷

¹Dept. of Paediatric and Preventive Dentistry, Jaipur Dental College, Jaipur, Rajasthan, India

²Private Practice, Wisdom Dental Clinics, Jaipur, Rajasthan, India

³Rajasthan Dental College & Hospital, Jaipur, Rajasthan, India

⁴Dept. of Oral and Maxillofacial Surgery, Wisdom Dental Clinics, Jaipur, Rajasthan, India

⁵Dept. of Periodontics, Institute of Dental Sciences, Bareilly, Uttar Pradesh, India

⁶Dept. of Pedodontics and Preventive Dentistry, RUHSCDS Govt. Dental College, Jaipur, Rajasthan, India

⁷Wisdom Dental Clinics, Jaipur, Rajasthan, India



ARTICLE INFO

Article history:

Received 10-03-2023

Accepted 20-04-2023

Available online 03-06-2023

Keywords:

Age

CEREC

Invisalign

Aesthetic

Veneers

ABSTRACT

Dental aesthetics have become highly important nowadays. Treating aesthetic needs with non-invasive and with minimal techniques can preserve tissues. Invisalign aligners are an aesthetic and comfortable option too for orthodontic treatment. The increased demand for orthodontic treatment in adults has increased and widened the upper age limit for orthodontic intervention. The antero-posterior skeletal relationship of the maxilla and mandible is determined by the ANB angle. Veneers can be one of the techniques which show excellent aesthetic results and longevity of the treatment. This report highlights the relevant aspects of Invisalign aligners and veneers in a 54-year-old female with the minimal invasive method where the aesthetics of patient was highly improved.

This is an Open Access (OA) journal, and articles are distributed under the terms of the [Creative Commons Attribution-NonCommercial-ShareAlike 4.0 License](https://creativecommons.org/licenses/by-nc-sa/4.0/), which allows others to remix, tweak, and build upon the work non-commercially, as long as appropriate credit is given and the new creations are licensed under the identical terms.

For reprints contact: reprint@ipinnovative.com

1. Introduction

The orthodontic diagnosis of disharmonies between the skeletal bases of the skull is mainly undertaken by the maxilla and mandible to their reference points. ANB (A point, nasion, and B point) describes the discrepancy between skeletal bases.¹

These angles depend on the landmarks that form them. Likewise, variation in the position of nasion due to growth or lack of accuracy while measuring can affect the relationship of skeletal bases, thus, involving the ANB measurement.²

Point A is not a fixed point as it varies with growth, similar to nasion as reported by one author ANB angle not

only depends on nasion but also facial divergence.³ Factors affecting ANB are the patient age (ANB decreases with age), nasion position, rotation of SN (Sella-nasion) line, occlusal plane, maxilla, and facial prognathism.¹

Invisalign is based on sophisticated 3D graphic technology for designing and creating personalized masks for the gradual movement of teeth.⁴ Since the 1930s, dental veneers have been used for improving the aesthetic and protection of teeth.⁵ Dental veneers are considered to give expected results in correction cases of anterior teeth.⁶

The 3D interface and digital designing of restoration allows the clinician to immediately evaluate the preparation for the correction if needed and take new impression.⁷ The use of laminate veneers resulted in a better aesthetic outcome and less chair time.⁸

* Corresponding author.

E-mail address: dr.gauravgupta99@gmail.com (G. Gupta).

In this case report, we present a case of an elderly 54-year-old female patient where Invisalign aligners did retraction utilizing the already present spaces, then veneer (CEREC) was given in the upper anterior, which highly improved the aesthetics in a single visit.

2. Case Report

A 54-year-old female patient reported to the clinic with the chief complaint of an unpleasant smile. On intraoral examination, she had protrusion, irregular, broken, and discoloured anterior teeth. Spacing was distal to the upper right lateral incisor. (Figure 1) Extraoral analysis, showed a convex facial profile. (Figure 2)

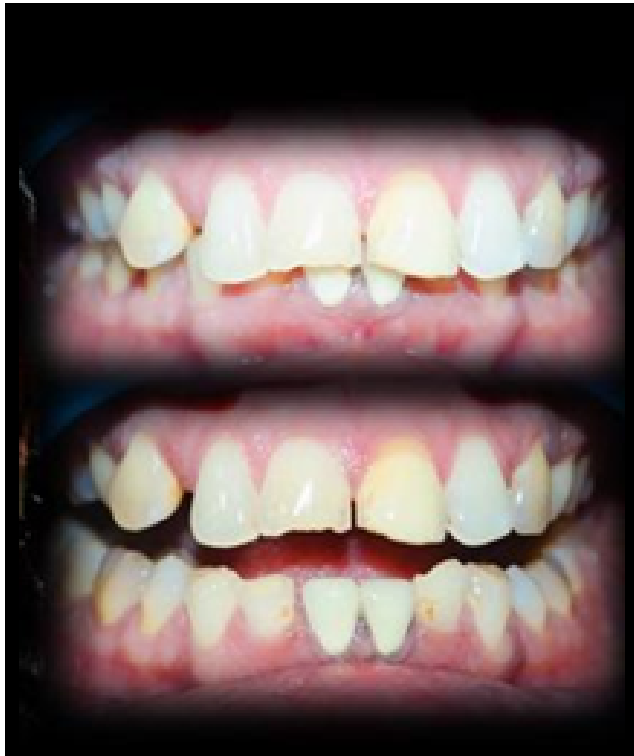

Fig. 1: Spacing, broken and discoloured anterior teeth.

Her primary concern was the alignment of her maxillary incisors, and she was not willing to have fixed appliances.

Based on her concern, we planned for Invisalign clear aligners followed with veneers as our treatment plan. Invisalign aligners were given to align her teeth and close the spacing in the maxillary arch, followed by veneers to improve the aesthetics. The primary goal was to maintain occlusion, maintaining normal overbite and overjet, achieving a functional occlusion.

Attachments were then placed on teeth to achieve predictable tooth movement using Invisalign aligners. The aligners were given for 3 months, and the treatment was further combined with veneers. Here we opted for CEREC workflow using eMax CAD block to make it convenient

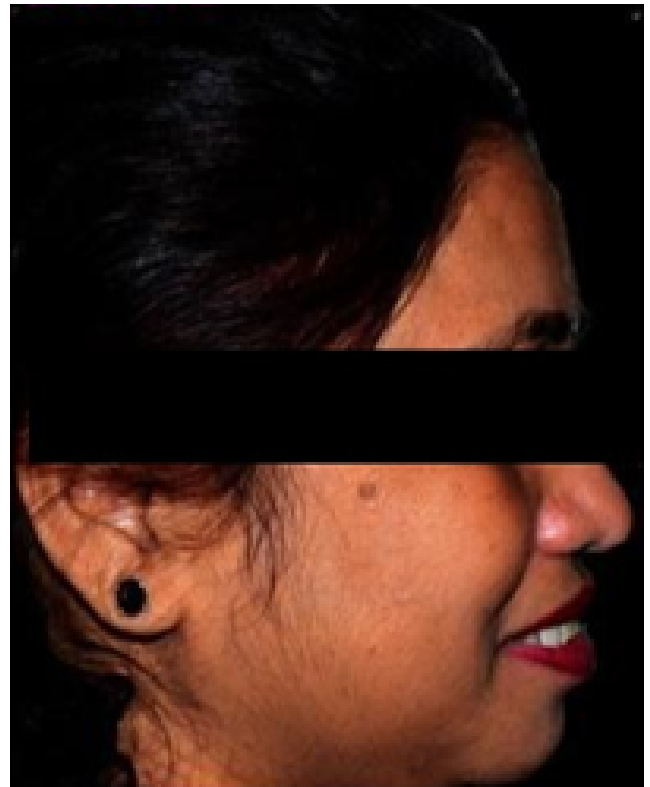

Fig. 2: Convex facial profile

and effective for the patient and save time. A single-visit of less than one hour was the time consumed to get the output through the CEREC CAD/CAM chairside system. The system allows scanning, digitally designing, making occlusal adjustments, and calibrating the proximal contacts. (Figure 3a,b)

Upper central incisors tooth preparation was done based on the thickness of the prosthetic material. Minimum thickness helps in achieving structural durability and aesthetics. Round angles were made to improve load distribution through the material. Tooth preparation was avoided from any irregular surfaces.

We then read the Morphology of dentition on software, and the data is observed by optical impression once the virtual model was developed to select insertion axis. The obtained data had to be sent to the milling machine. Both veneers were made from a single block and treatment was done with eMax CAD block. Later final adhesive luting of veneer was done. We then observed before and after treatment images. (Figure 4) The patient was very pleased with the final result. (Figure 5)

3. Discussion

According to Ackerman, adult orthodontics is that branch of orthodontics that is concerned with the balance between achieving optimal proximal and occlusal contact of

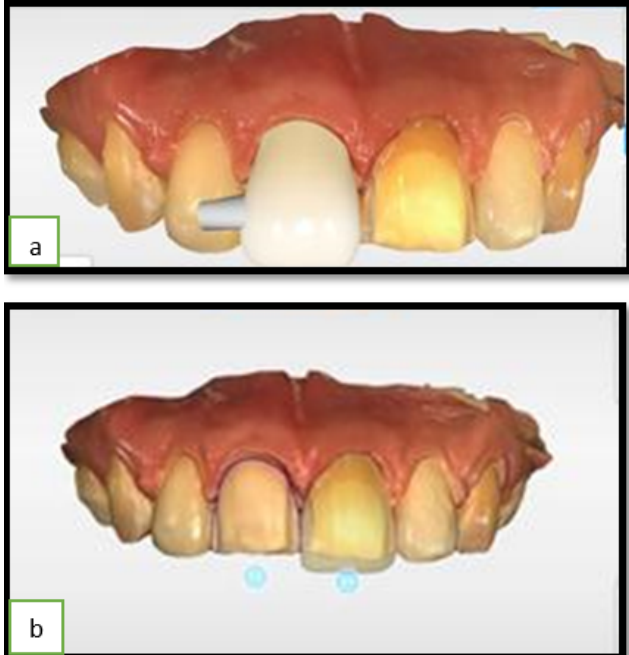


Fig. 3: a,b: CAD/CAM system scan for digital designing and adjustments.

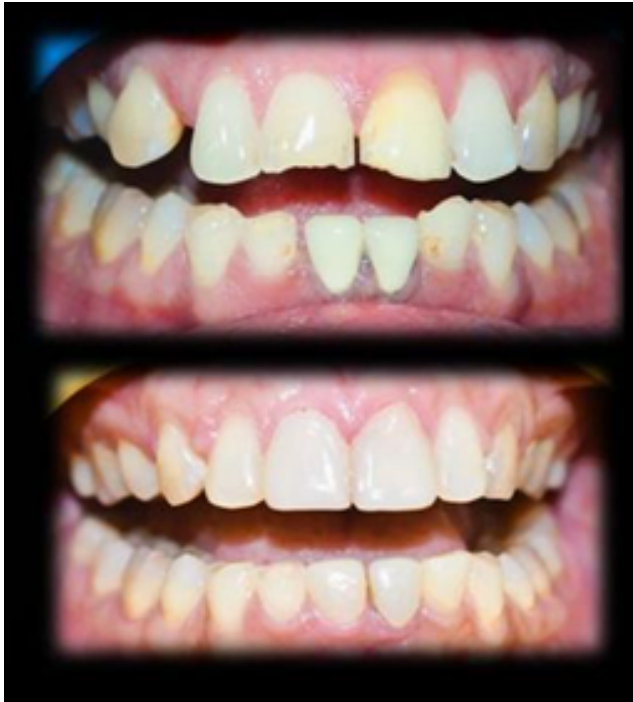

Fig. 4: Before and after treatment images depicting aligned and aesthetic teeth.

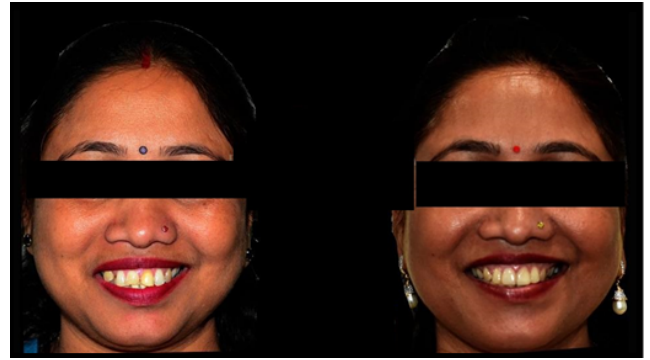

Fig. 5: Before and after treatment with a pleasant smile.

teeth, pleasing aesthetics, normal function with reasonable stability.⁹ The evaluation of sagittal relationship has been a significant problem in the field of orthodontics, due to the factors affecting the measuring angles which have prime importance in diagnosis and treatment planning of the case. ANB angle has been the most commonly used measurement for assessing sagittal jaw discrepancies. The angle value ranges from 2-4 degrees to 0-4 degrees.¹⁰

Adult patients who are above 50-years of age mostly present with complex oral problems which need a multidisciplinary approach of treatment planning. As here, we took a multidisciplinary approach to obtain the desired result. We gave 3 months Invisalign treatment along with veneer in the upper anterior in a single visit with CEREC workflow using eMax CAD block.

The study stated that IPS Emax CAD resulted in fracture-resistant crowns, while hand-layered zirconia crowns resulted in early veneer failures.¹¹ In this case, we also used IPS eMax CAD.

Generally, aesthetic satisfaction is one of the complex processes to obtain from the patient.^{12,13} However, a few factors may play an important role in securing a patient's satisfaction, such as durability of final aesthetic result, time duration of teeth preparation, and the cost of treatment. Here we managed all the factors to get a satisfactory outcome by achieving desirable functional and aesthetic results, considering other factors like ANB angle and age.

The CEREC system allows clinicians to independently design and machine ceramic restorations in a matter of hours, thus enabling reconstruction in only a single visit.¹⁴ In our present case, we used this system, and work was done in less than one hour in a single visit.

Dental veneers improve aesthetics, its indications are:

1. Discoloured teeth due to tetracycline staining, age, fluorosis, amelogenesis imperfect
2. Restored or worn out teeth
3. Abnormal morphology
4. Correction of minor malposition
5. Intraoral repair of crown and bridges¹⁵⁻¹⁷

In the present case, the patient has increased age, discoloured and minor malposition of teeth, hence we opted for veneers in combination with Invisalign aligners which gave a pleasant smile in an adult patient.

4. Conclusion

The evidence of our clinical practice suggests that CEREC chairside system is one of the valuable tools for clinician for saving time. The numbers of adult patients in orthodontics are usually concerned about aesthetics but adults may have other complications due to age related factors, which could pose a challenge for treatment. The biomechanics must be customized according to the individual's treatment requirements, and a multidisciplinary approach should be employed to get the maximum result. Therefore, concluding that a skilful combination of Invisalign clear aligners and veneers can give desirable results in correcting misaligned teeth and aesthetics when planned properly, even in adult patients.

5. Conflict of Interest

None.


6. Source of Funding

None.

References

- Oktay H. A comparison of ANB, WITS, AF-BF, and APDI measurements. *Am J Orthod Dentofacial Orthop.* 1991;99(2):122–8. doi:10.1016/0889-5406(91)70114-C.
- Rotberg S, Fried N, Kane J, Shapiro E. Predicting the "Wits" appraisal from the ANB angle. *Am J Orthod.* 1980;77(6):636–42. doi:10.1016/0002-9416(80)90155-4.
- Aylor CM. Changes in the relationship of nasion, point A, and point B and the effect upon ANB. *Am J Orthod.* 1969;56(2):143–63. doi:10.1016/0002-9416(69)90231-0.
- Align Technology. Available from: <http://www.invisalign.com>.
- Calamia J. The etched porcelain veneer technique. *N Y State Dent J.* 1988;54(7):48–50.
- Layton DM, Walton TR. The up to 21-year clinical outcome and survival of feldspathic porcelain veneers: accounting for clustering. *Int J Prosthodont.* 2012;25(6):604–12.
- Zaruba M, Ender A, Mehl A. New applications for three-dimensional follow-up and quality control using optical impression systems and OraCheck. *Int J Comput Dent.* 2014;17(1):53–64.
- Toh C, Setcos J, Weinstein A. Indirect dental laminate veneers—an overview. *J Dent.* 1987;15(3):117–24. doi:10.1016/0300-5712(87)90067-4.
- Proffit WR, Fields HW, Sarver DM. Contemporary Orthodontics. Mosby: St Louis; 2007.
- Steiner CC. Cephalometrics for you and me. *Am J Orthod.* 1953;39:729–55.
- Guess PC, Zavanelli RA, Silva NR, Bonfante EA, Coelho PG, Thompson VP, et al. Monolithic CAD/CAM lithium disilicate versus veneered Y-TZP crowns: comparison of failure modes and reliability after fatigue. *Int J Prosthodont.* 2010;23(5):434–42.
- Nalbandian S, Millar B. The effect of veneers on cosmetic improvement. *Br Dent J.* 2009;207(2):3. doi:10.1038/sj.bdj.2009.609.
- Meijering A. Survival of three types of veneer restorations in a clinical trial: a 2.5-year interim evaluation. *J Dent.* 1998;26(7):563–8. doi:10.1016/S0300-5712(97)00032-8.
- Mörmann WH, Krejci I. Computer-designed inlays after 5 years in situ: clinical performance and scanning electron microscopic evaluation. *Quintessence Int.* 1992;23(2):109–15.
- RCSE. National Clinical Guidelines 1997. England: GTA; 1997.
- Ferrari M, Patroni S, Balleri P. Measurement of enamel thickness in relation to reduction for etched laminate veneers. *Int J Periodontics Restor Dent.* 1991;12(5):407–13.
- Tjan AH, Dunn JR, Sanderson IR. Microleakage patterns of porcelain and castable ceramic laminate veneers. *J Prosthetic Dent.* 1989;61(3):276–82. doi:10.1016/0022-3913(89)90127-3.

Author biography

Gaurav Gupta, Professor  <https://orcid.org/0000-0003-3895-059X>

Anirudh Agarwal, Professor & Head

D.K Gupta, Senior consultant

Neeraj Chandra, Senior Lecturer

Priyanka Gupta, Senior Demonstrator

Devanshi Sankhla, Associate Dentist

Cite this article: Gupta G, Agarwal A, Gupta DK, Chandra N, Gupta P, Sankhla D. A skillful combination of invisalign aligners followed with veneers: A case report. *IP Indian J Orthod Dentofacial Res* 2023;9(2):143-146.