

Content available at: <https://www.ipinnovative.com/open-access-journals>

IP Indian Journal of Orthodontics and Dentofacial Research

Journal homepage: <https://www.ijodr.com/>

Case Report

Maxillary total arch distalization with infra-zygomatic crest (IZC) bone screws for the correction of skeletal class II malocclusion: A case report

Mohsin Aslam Wani^{1,*}, Shantanu Khattri¹, Anjali Thapa², Shiraz Siddiqui³, Mohd. Amir⁴, Mohd. Saeedul Jafar¹

¹Dept. of Orthodontics and Dentofacial Orthopaedics, Career Post Graduate Institute of Dental Sciences & Hospital, Lucknow, Uttar Pradesh, India

²Dept. of Orthodontics & Dentofacial Orthopaedics, Kids Dental Care, Gangtok, Gangtok, India

³Dept. of Orthodontics & Dentofacial Orthopaedics, Health Gulf Polyclinic, Tabuk, Kingdom of Saudi Arabia

⁴Dept. of Orthodontics & Dentofacial Orthopaedics, Consultant Orthodontist, Prayagraj, Uttar Pradesh, India



ARTICLE INFO

Article history:

Received 11-02-2023

Accepted 06-04-2023

Available online 03-06-2023

Keywords:

Temporary Skeletal Anchorage Devices (TSADs)

Infrazygomatic Crest (IZC) bone screw

Total arch distalization

Zygomatic crest

Centre of resistance (Cres)

Extra-alveolar (EA) implants

ABSTRACT

The correction of skeletal malocclusions in orthodontics has always been a contest for clinicians, especially in non-growing individuals, and often necessitates the distalization of maxillary or mandibular skeletal bases. To accomplish this, diverse treatment modalities have been employed by researchers, and the most recent one is the use of extra-alveolar bone screws such as Infra-zygomatic Crest (IZC) implants. Unlike conventional methods such as extraction and orthognathic surgery, this technique is an effective and efficient treatment alternative for predictable total arch distalization in borderline surgical cases, without interfering with the root movements and with minimal dependence on patient compliance. For achieving the displacement of teeth in a bodily controlled manner, an appropriate direction and magnitude of force must be carefully chosen. Therefore, this case report attempts to measure the amount and pattern of maxillary molar distalization using Infra-zygomatic Crest (IZC) implants with long power arms as a workable treatment option, in an 18-year-old female patient with a skeletal Class II pattern, with no extra mini-implants in the anterior region for intrusion.

This is an Open Access (OA) journal, and articles are distributed under the terms of the [Creative Commons Attribution-NonCommercial-ShareAlike 4.0 License](https://creativecommons.org/licenses/by-nc-sa/4.0/), which allows others to remix, tweak, and build upon the work non-commercially, as long as appropriate credit is given and the new creations are licensed under the identical terms.

For reprints contact: reprint@ipinnovative.com

1. Introduction

In contemporary orthodontics, the most prevalent skeletal malocclusion seen clinically is Class II malocclusion with an incidence rate of about 38% to 50%, adversely affecting the facial and dental esthetics of patients.¹ Traditionally, such cases have been treated with extraction therapy or maxillary molar distalization by various extra-oral and intra-oral methods, that are usually accompanied by undesired reactionary forces contributing to the splaying and forward thrust of anterior teeth.²⁻⁵ However, the advent of Temporary Skeletal Anchorage Devices (TSADs),

especially Extra-alveolar (EA) implants such as the Infra-zygomatic Crest (IZC) bone screws, have produced an archetype shift in orthodontic treatment mechanics by becoming a promising substitute for achieving skeletal anchorage in molar distalization process.⁶

The IZC ridge of the maxilla is considered to be an ideal site for implant insertion, because of the availability of a dense cortical plate, safer buccal location from the root apices, flexibility of allowing higher placement of the implant in the maxillary vestibular region, and allowing single-phase of unobstructed tooth movement during retraction.⁷ This has contributed to the high success rate of IZC implants (93.7%).⁸ The zygomatic crest eminence can

* Corresponding author.

E-mail address: mohsynaslam@gmail.com (M. A. Wani).

be felt clinically along the buccal curvature between the alveolar and zygomatic process of the maxilla, however, age-related variations have been observed and usually, the ridge is located between the maxillary second premolar and first molar in young subjects and above maxillary first molar in adults.⁹ Lin prefers IZC bone screws to be placed in the 1st and 2nd molar region, whereas, Liou favors a more anterior placement, closer to the mesiobuccal root of the 1st molar tooth.¹⁰

The recommended size and material for the IZC bone screw is 2×12 mm stainless steel (SS). A clearance of 5 mm between the screw head and supporting soft tissue is considered adequate to facilitate good oral hygiene and avoid any soft tissue irritation.¹¹ The insertion method of the IZC bone screw involves a phase of cortical bone penetration with the tip of the implant perpendicular to the long axis of the tooth, followed by the gradual orientation of the screw to about 55-70° inferior to the horizontal plane to achieve maximum buccal bone engagement.⁸ This case report intends to highlight the amount of maxillary arch distalization produced by using IZC bone screws and a medium-length (8-10mm) power arm hook.

2. Case Report

An 18-year-old female patient reported with a chief complaint of forwardly placed upper teeth to the post-graduate clinic. No significant medical or dental history of the patient was ascertained. On extra-oral examination, the patient had a convex facial profile, posterior divergence, incompetent lips, deep mento-labial sulcus angle and no facial asymmetry. Intra-oral examination revealed a full-cusp Class II molar relation bilaterally and end-on canine relation on both sides. Overjet was 4 mm, with no midline deviation and increased incisor exposure of 4 mm. The maxillary incisors were relatively upright and mild crowding was observed in the lower anterior section. No temporomandibular joint pathology was detected (Figure 1).

Panoramic radiograph revealed that all teeth including third molars have erupted to the occlusal level and normal root morphology was evident. The lateral cephalogram (Figure 2) and cephalometric analysis showed an average growth pattern (Go-Gn-SN = 30°), sagittal maxillary excess (SNA = 86°), retrognathic mandible (SNB = 76°), class II skeletal base (ANB = 10° and Wits Appraisal = +9 mm), retroclined upper incisors (Upper Incisor to NA = 13°) and relatively proclined lower incisors (Lower Incisor to NB = 36°). Model analysis showed a Bolton's ratio with an excess of mandibular overall (0.2mm) and mandibular anterior (1.8mm) tooth material, respectively.

2.1. Treatment objectives

The treatment objective was to improve facial aesthetics by:

1. Simultaneous maxillary arch distalization to compensate for the excessive overjet of 2 mm and arch length-tooth material discrepancy of 3 mm, thereby reducing the lip protrusion, correcting overjet, achieving lip competency and class I molar and canine relation.
2. And to achieve an intrusion of more than 2 mm so as to offset the excessive incisor display.

2.2. Treatment alternatives

Based on the post-pubertal age of the patient, three treatment approaches were prescribed and defined to the patient:

1. Surgical: Orthodontic decompensation followed by the orthognathic surgical approach of Lefort I Osteotomy with posterior impaction of the maxilla in combination with BSSO (Bilateral Sagittal Split Osteotomy) and advancement of the mandible to correct the sagittal discrepancy as indicated by the values recorded by Burstone Analysis (N-A-Pog = +19°, Ar-Ptm(HP) = 30 mm, N-A (HP) = + 3 mm), N-B (HP) = - 15mm, PNS-ANS (HP) = 60 mm, Go-Pog = 73 mm, B-Pog (MP) = - 4 mm) or
2. Premolar extraction: Orthodontic Camouflage treatment with extraction of maxillary first and mandibular second premolar teeth.
3. Third molar extraction and total arch distalization: Orthodontic Camouflage treatment with the extraction of maxillary third molars and in-toto distalization of maxillary arch with the aid of Infra-zygomatic Crest (IZC) bone screws in combination with the mandibular tooth material reduction (inter-proximal slicing or single incisor extraction). This option was the most conservative approach among all the other treatment options.

2.3. Treatment plan

The principal aim of the treatment plan was to achieve the utmost possible distalization of the maxillary arch and its dentition to improve the skeletal, dental and soft tissue parameters. Leveling and aligning the maxillary dentition along with the torque correction of maxillary anterior teeth to give enough freedom for total arch displacement in the posterior direction was an essential part of the treatment plan.

2.4. Treatment progress

Extraction of 18 and 28 was done, bands were placed on the upper and lower first molars and bonded buccal tubes were attached to the upper and lower second molars. MBT 0.022" × 0.028" slot metal bracket system from 3M™ Unitek™ Gemini was used. After initial leveling and alignment, 19 ×

25 SS working archwires were placed in both arches. Two 2×12 mm stainless steel IZC bone screws (Model: A-1P-212012) from Bio-Ray® (Figure 3) were placed in the zygomatic crestal bone between maxillary first and second molars bilaterally at an angle of 70° (approx.) and 9 mm high from the cemento-enamel junction (CEJ) of the molars. Figure-of-8 steel ligature wire was used to span across all the maxillary teeth to form a single unit, so that applied forces were evenly distributed. A medium-length hook (8-10mm) was crimped on both sides onto the upper working archwire distal to the canine and was engaged with the IZC bone screw using a NiTi coil spring of 9 mm length and a distalizing force of 300 grams (10 oz) was applied (Figures 4 and 5). Considering the biomechanical implication, the direction and the height of the force vector was maintained at the level or above the centre of resistance (C_{res}) of the maxillary denture, such that the bodily displacement and counter-clockwise rotation of the entire dentition and the skeletal base are produced. The treatment was continued for 6 months, unfortunately, thereafter the patient permanently relocated to another place and discontinued the treatment. However, the treatment results achieved by then have been documented in the following results section.

2.5. Treatment results

An improvement in the skeletal and dental parameters was observed. A reduction in the sagittal skeletal discrepancy was depicted by the posterior movement of Point A and a reduction in ANB angle by 3° . Minor reduction in vertical angulation confirms the maxillary intrusion and forward auto-rotation of the mandible. Improvement in the axial inclination of upper anterior teeth suggests adequate torque expression by the sequential archwires. Molar distalization changes were calculated by using Radiographic Analysis (Figure 6), as recommended by Abhishek et al.¹² About 3 mm of maxillary molar distalization (U6 to PTV and U6 to Facial axis) was achieved post four months of distalization force application and was clinically observed by a change in full cusp class II into end-on molar relation. The change in axial inclination was minimal as indicated by the amount of tipping (α angle) and U6 to TVL (cusp tip and root apex), as summarized in Table 1.

3. Discussion

Facial esthetics is the prime concern of most of the patients undergoing orthodontic treatment and usually, when the protrusion is not so severe, patients do not agree to the extraction of multiple upper and lower vital teeth. However, if required, they are willing to sacrifice third molars, owing to their minimal effects on esthetics and function, providing ample space distal to the second molars for attaining distalization of the entire dentition with the assistance of skeletal anchorage.¹³ The C_{res} of the entire

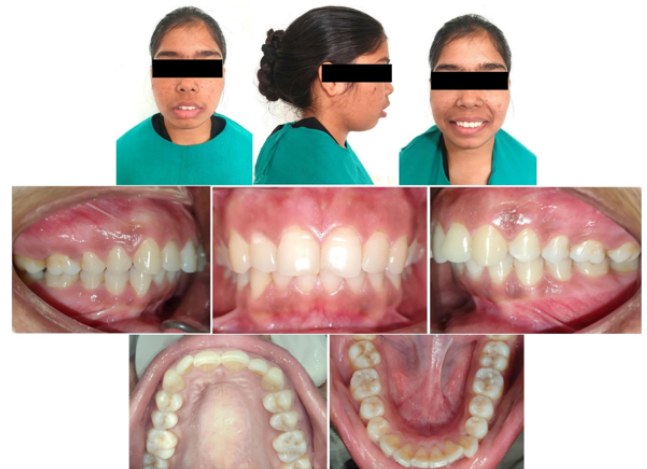

Fig. 1: Pre-treatment extra-oral and Intra-oral records.

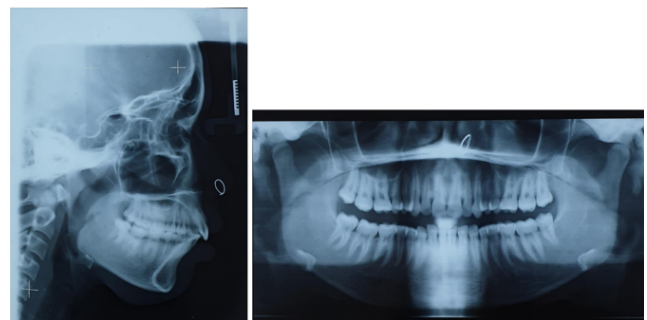


Fig. 2: Pre-treatment lateral cephalogram and OPG records

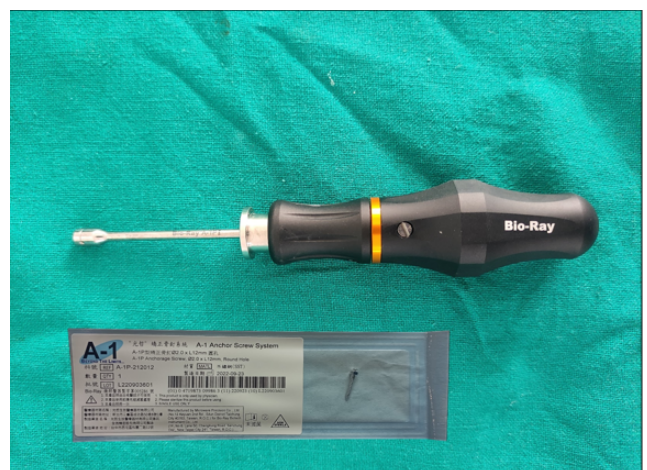

Fig. 3: Infra-zygomatic Crest (IZC) Implant and Driver.

Table 1: Cephalometric changes recorded after 4-months of IZC distalization procedure

Measurement	Mean	Pre-treatment	Post-distalization
Skeletal Variables			
SNA (°)	82	86	83
SNB (°)	80	76	76
ANB (°)	2	10	7
Wits Appraisal (mm)	0	+9	+7
Go-Gn-SN (°)	32	30	30
Dental Variables			
Upper Incisor to NA (mm)	4	4	4
Upper Incisor to NA (°)	22	13	18
Upper Incisor to SN (°)	102	96	98
Lower Incisor to NB (mm)	4	8	9
Lower Incisor to NB (°)	25	36	38
Soft Tissue Variables			
Nasolabial Angle (°)	102	111	108
Upper-lip to S-line (mm)	0	+4	+3
Lower-lip to S-line (mm)	-1	-2	-1
Arch Distalization Changes			
U6 to PTV (mm)		(a) 24	(a') 21
U6 to Facial axis (mm)		(b) 3	(b') 0
Amount of tipping/ α angle (°)		(α) 77	(α') 78
U6 to TVL (cusp tip) (mm)		(A) 43	(A') 40
U6 to TVL (root apex) (mm)		(B) 44	(B') 41.5

of the cortical bone. The highest retention of the screw can be achieved by placing them in areas with the thinnest soft tissue and the thickest cortical bone.²⁷ Liou et al., recommend the infra-zygomatic crest region as an insertion site for orthodontic skeletal anchorage requirements of the maxilla because of its thicker bone and also due to its anatomical advantage, since this region has two cortical plates—the buccal cortical plate and the sinus floor, providing a bi-cortical fixation and better primary stability of the bone screw.¹⁶ Paul P. et al. reported that implants showed maximum von mises stress at 90° angulations and minimum at 60° angulations with a load of 8 oz to 12 oz (220 to 340g). So, an optimal angulation and force that are required for

the effective biomechanics of the IZC implants and can be safely loaded, should not exceed these values.^{28,29}

4. Conclusion

Pertaining to the line of action of force, the magnitude and the point of application of the force, in relation to the center of resistance (C_{res}) of maxillary dentoalveolar complex and the corresponding extra-radicular positioning of the infra-zygomatic (IZC) crest implants, the desired biomechanical results can be achieved, even in borderline surgical cases. The bodily distalization of the maxillary dentition with minimal tipping is therefore possible by employing forces closer to the C_{res} , thereby eliminating the unwanted effects of the generated reactionary forces on the occlusal plane. Sound knowledge of biomechanics and its useful clinical applicability is therefore the forerunner of most orthodontic treatment strategies.

5. Conflict of Interest

None.

6. Source of Funding


None.


References


- Rosa WGN, De Almeida-Pedrin R, Oltramari PVP, Conti ADC, Poleti T, Shroff B, et al. Total arch maxillary distalization using infrazygomatic crest miniscrews in the treatment of Class II malocclusion: a prospective study. *Angle Orthod.* 2023;93(1):41–8.
- Vakil KK, Sunil LN, Sahane D. Managing Class II malocclusion with miniscrews implants - Case reports. *J Ind Orthod Soc.* 2010;44:20–8.
- Kuroda S, Sugawara Y, Deguchi T, Kyung HM, Takano-Yamamoto T. Clinical use of miniscrew implants as orthodontic anchorage: Success rates and postoperative discomfort. *Am J Orthod Dentofacial Orthop.* 2007;131(1):9–15. doi:10.1016/j.ajodo.2005.02.032.
- Shroff B, Lindauer SJ, Burstone CJ, Leiss JB. Segmented approach to simultaneous intrusion and space closure: Biomechanics of the three-piece base arch appliance. *Am J Orthod Dentofacial Orthop.* 1995;107(2):136–43. doi:10.1016/s0889-5406(95)70128-1.
- Nanda R. *Biomechanics in Clinical Orthodontics.* Saunders; 1997.
- Khan J, Goyal M, Kumar M, Kushwah A, Kaur A, Sharma M, et al. Comparative evaluation of displacement and stress distribution pattern during maxillary arch distalization with Infra Zygomatic Screw- A three-dimensional finite element study. *Int Orthod.* 2021;19(2):291–300.
- Shaikh A, Jamdar AF, Galgali SA. Efficacy of Infrazygomatic Crest Implants for Full-arch Distalization of Maxilla and Reduction of Gummy Smile in Class II Malocclusion. *J Contemp Dent Pract.* 2021;22(10):1135–43.
- Hsu E, Lin JS, Yeh H, Chang CH, Roberts WE. Comparison of the failure rate for infrazygomatic bone screws placed in movable mucosa or attached gingiva. *Int J Orthod Implantol.* 2017;47:96–106.
- Liou EJ, Chen PH, Wang YC, Lin JC. A computed tomographic image study on the thickness of the infrazygomatic crest of the maxilla and its clinical implications for miniscrew insertion. *Am J Orthod Dentofacial Orthop.* 2007;131(3):352–6.
- Lin J, and WER. CBCT imaging to diagnose and correct the failure of maxillary arch retraction with IZC screw anchorage. *Int J Orthod Implantol.* 2014;35:4–17.


11. Chang CH. Clinical applications of orthodontic bone screw in Beethoven Orthodontic Center. *Int J Orthod Implantol.* 2011;23:50-1.
12. Bansal A, Prakash AT, Deepthi, Naik A. A Noble, Easy and Conceptual Radiographic Analysis to Assess the Type of Tooth Movement (Molar Distalization). *J Clin Diagn Res.* 2015;9(8):22-5. doi:10.7860/JCDR/2015/13123.6286.
13. Chen G, Teng F, Xu TM. Distalization of the maxillary and mandibular dentitions with miniscrew anchorage in a patient with moderate Class I bimaxillary dentoalveolar protrusion. *Am J Orthod Dentofacial Orthop.* 2016;149(3):401-10.
14. Sung EH, Kim SJ, Chung YS, Park YG, Hs Y, Lee KJ, et al. Distalization pattern of whole maxillary dentition according to force application points. *Korean J Orthod.* 2015;45(1):20-8. doi:10.4041/kjod.2015.45.1.20.
15. Tanne K, Koenig HA, Burstone CJ. Moment of force ratios and the center of rotation. *Am J Orthod Dentofacial Orthop.* 1988;94(5):426-31. doi:10.1016/0889-5406(88)90133-3.
16. Jeong GM, Sung SJ, Lee KJ, Chun YS, Mo SS. Finite element investigation of the center of resistance of the maxillary dentition. *Korean J Orthod.* 2009;39(2):83-94. doi:10.4041/kjod.2009.39.2.83.
17. Teuscher U. An appraisal of growth and reaction to extraoral anchorage Simulation of orthodontic-orthopedic results. *Am J Orthodontics.* 1986;89(2):113-21. doi:10.1016/0002-9416(86)90087-4.
18. Jeong GM, Sung SJ, Lee KJ, Chun YS, Mo SS. Finite-element investigation of the center of resistance of the maxillary dentition. *Korean J Orthod.* 2009;39(2):83-94. doi:10.4041/kjod.2009.39.2.83.
19. Almeida MR. Biomechanics of extra-alveolar mini-implants. *Dental Press J Orthod.* 2019;24(4):93-109.
20. Kim SJ, Kim JW, Choi TH, Lee KJ. Combined use of miniscrews and continuous arch for intrusive root movement of incisors in Class II division 2 with gummy smile. *Angle Orthod.* 2014;84(5):910-8.
21. Hedayati Z, Shomali M. Maxillary anterior en masse retraction using different antero-posterior position of mini-screw: A 3D finite element study. *Prog Orthod.* 2016;17(1):31. doi:10.1186/s40510-016-0143-z.
22. Lee KJ, Kim SJ. Advanced biomechanics for total arch movement and non-surgical treatment for hyperdivergent faces. *Semin Orthod.* 2018;24(1):83-94. doi:10.1053/j.sodo.2018.01.008.
23. Sreenivasagan S, Subramanian AK, Chae JM, Venugopal A, Marya A. Displacement patterns of the maxillary anterior teeth during total distalization and en masse anterior retraction using interradicular and infrazygomatic crest mini-implants with varying power arm heights: A finite element analysis. *J Int Oral Health.* 2021;13(5):462-9. doi:10.4103/JIOH.JIOH_99_21.
24. Rokutanda H, Koga Y, Yanagida H, Tominaga JY, Fujimura Y, Yoshida N, et al. Effect of power arm on anterior tooth movement in sliding mechanics analyzed using a three-dimensional digital model. *Orthod Waves.* 2015;74:93-8. doi:10.1016/j.odw.2015.06.001.
25. Doshi DS, Pradhan TM. A comparative evaluation of different compensating curves and power arm length during retraction of maxillary anterior teeth: A finite element study. *Indian J Health Sci Biomed Res.* 2017;10(2):183. doi:10.4103/kleuhsj.ijhs_392_16.
26. Kuroda S, Yamada K, Deguchi T. Root proximity is a major factor for screw failure in orthodontic anchorage. *Am J Orthod Dentofacial Orthop.* 2007;131(4):68-73.
27. Kim HJ, Yun HS, Park HD. Soft-tissue and cortical-bone thickness at orthodontic implant sites. *Am J Orthod Dentofacial Orthop.* 2006;130(2):177-82.
28. Paul P, Mathur AK, Chitra P. Stress distribution patterns in mini-implant and bone in the infra-zygomatic crest region at different angulations: A finite element study. *J World Fed Orthod.* 2021;10(1):29-34.
29. Alrbata RH, Momani MQ, Al-Tarawneh AM, Ihyasat A. Optimal force magnitude loaded to orthodontic microimplants: a finite element analysis. *Angle Orthod.* 2016;86(2):221-7.

Author biography

Mohsin Aslam Wani, Former Post Graduate Student
 <https://orcid.org/0000-0002-2522-0996>

Shantanu Khattri, Professor  <https://orcid.org/0000-0001-5387-7031>

Anjali Thapa, Consultant Orthodontist  <https://orcid.org/0009-0005-7458-3661>

Shiraz Siddiqui, Specialist Orthodontist  <https://orcid.org/0009-0003-1340-7096>

Mohd. Amir, Consultant Orthodontist

Mohd. Saeedul Jafar, Post-Graduate Student

Cite this article: Wani MA, Khattri S, Thapa A, Siddiqui S, Amir M, Jafar MS. Maxillary total arch distalization with infra-zygomatic crest (IZC) bone screws for the correction of skeletal class II malocclusion: A case report. *IP Indian J Orthod Dentofacial Res* 2023;9(1):127-132.