

Content available at: <https://www.ipinnovative.com/open-access-journals>

IP Indian Journal of Orthodontics and Dentofacial Research

Journal homepage: <https://www.ijodr.com/>

Case Report

Correction of ectopically placed canine by combining skeletal anchorage and statically determinate force system

Shubhangi Ameet Mani¹, Ravindra Manerikar¹, Nilesh Mote¹, N G Toshniwal¹,
Kunal Pallan¹, Deeksha Ganesh Devadiga^{1,*}

¹Dept. of Orthodontics, Rural Dental College, Loni, Maharashtra, India



ARTICLE INFO

Article history:

Received 05-02-2023

Accepted 05-04-2023

Available online 03-06-2023

Keywords:

Ectopic canine

Highly placed canine

Skeletal anchorage

TADS

Temporary anchorage devices

Loop mechanics

t loop

midline shift

Crowding

Extraction

ABSTRACT

The incidence of ectopically erupting canine is quite common, reasons are multifactorial, but usually it's the lack of space which happens due to mesial drift of the posterior teeth or the inherent discrepancy between arch length and tooth size discrepancy. If it's the former, distalization is one of the Go-to treatment modality one can opt for provided the nose and lip relation is optimum and does not warrant for extraction. If it's the latter then extraction remains the only choice. This case report discusses an innovative way of aligning a highly placed canine without taxing the anchorage in all 3 planes with help of Skeletal anchorage and Loop mechanics while also correcting the inclinations and gummy smile without hindering nose-lip relation to a certain extent and also tackling the common problem of anatomically short upper lip.

This is an Open Access (OA) journal, and articles are distributed under the terms of the [Creative Commons Attribution-NonCommercial-ShareAlike 4.0 License](https://creativecommons.org/licenses/by-nc-sa/4.0/), which allows others to remix, tweak, and build upon the work non-commercially, as long as appropriate credit is given and the new creations are licensed under the identical terms.

For reprints contact: reprint@ipinnovative.com

1. Introduction

Ectopically placed canines are one of the frequent conditions encountered in orthodontic practice. There are many reasons for this to happen, but usually it's the lack of space which can happen because of mesial drift of the posterior teeth or the inherent discrepancy between arch length and tooth size.¹ If the displacement is due to the mesialization of the posteriors, due to the early exfoliation of the deciduous molars, then the treatment of choice would be distalization. But if it's due to arch length and tooth size discrepancy, then there is no other choice but to extract.²

Ectopic canines are usually associated with midline shift. Since the upper midline is an important focal spot in an aesthetic smile, any midline deviation greater than

2mm is easily recognized by the patient. So, correction of this deviation becomes a priority. Therefore, getting the canines in alignment is a biomechanical and also aesthetic challenge.

An orthodontist is at crossroads when deciding on a treatment plan in cases which require extraction due to the severity of crowding, but the facial profile does not allow extraction since it may lead to worsening of profile in a well-compensated case soft tissue wise.^{3,4}

This case report discusses an innovative way of aligning a highly placed canine without taxing the anchorage in all 3 planes with the help of Skeletal anchorage and Loop mechanics, while also correcting the inclinations and gummy smile while maintaining the nose-lip relation and also tackling the common problem of anatomically short upper lip.

* Corresponding author.

E-mail address: deekshadevadiga07335@gmail.com (D. G. Devadiga).

2. Diagnosis and Etiology

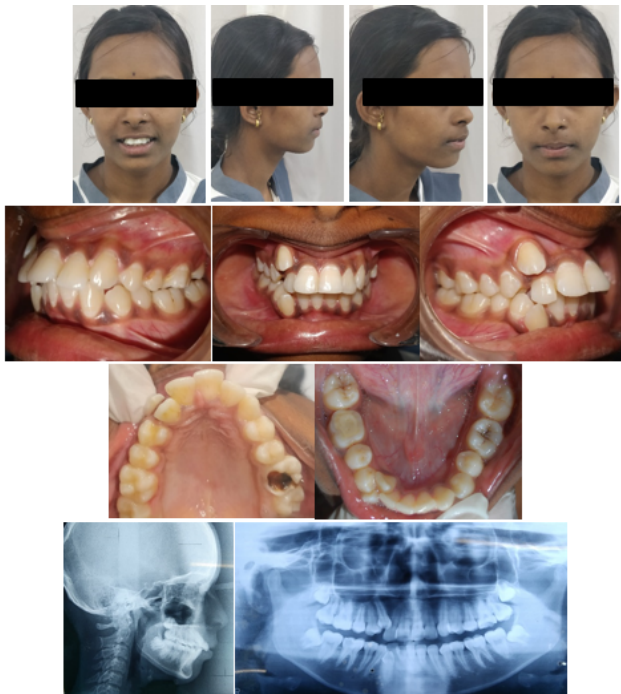


Fig. 1: Pre-treatment Intra oral and extra oral photographs

A 19-year-old female patient reported to the Department of Orthodontics with a chief complaint of irregularly placed teeth. She exhibited a convex profile, mesoprosopic face type, significant lip strain on closure with hyperactive Mentalis muscle. The patient had a short upper lip with an upward tilted nose. No gross facial asymmetry was detected. On smiling, the patient had excessive incisal exposure with a shift in the upper midline towards the right.

Intraoral examination revealed an increased overjet with proclined incisors. The right side exhibited ectopic placement of both upper and lower canines with crowding in both the arches. Both the upper and lower midline did not coincide with the facial midline and were shifted to the right. Antero-posteriorly, the molars were in Class I relationship bilaterally. The upper right first molar presented a deep carious lesion.

3. Treatment Objective

1. Levelling and Alignment of all teeth.
2. Correction of Upper and Lower mid line with respect to the facial mid line.
3. Correction of Upper and Lower anterior crowding.
4. Maintaining Class I molar relation bilaterally.

4. Treatment Alternatives

The patient was given an all first premolar extraction option which would aid in correction of crowding and inclinations,

but with retraction of the lower right canine there was a probability of damaging the root of the lateral incisor.

Another option was to extract the lateral incisor in the lower right segment and lateralization of canine and cuspidization of the premolar.

Instead upper first premolars and a canine in the lower right segment extraction was carried out and cuspidization of first premolar was decided.

5. Treatment Progress

All upper teeth were bonded on the MBT 0.022 slot except the upper right lateral incisor. Taking into consideration the inclinations of the anterior teeth, the Nance palatal button was selected as an anchorage reinforcement appliance. On observing the position and proximity of the upper right canine to the lateral incisor, segmental retraction and extrusion was planned by placing a TAD between the upper right 2nd premolar and molar and retracting with the help of a T loop made from 19x25 TMA. The activation of the loop was done every 7 weeks.

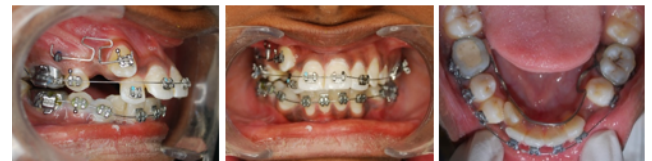

Fig. 2: Implant supported T Loop canine retraction

The wire sequence followed in both arches was 012 NiTi to 018 NiTi. After that, 018 AJ Wilcock Premium plus wire was used as base arch wire, and lingually placed lateral incisor was engaged to it, retraction of canine and midline correction was done simultaneously with the help of an open coil spring.

After 5 months, the upper right canine was distalized and extruded significantly. A rigid arch wire was engaged in the upper arch and Piggyback technique was used to get the canine in alignment.

After 3 months, extraorally, the smile appeared gummy and there was also some generalized spacing observed in the upper anterior region. So, Mini Titanium Implants of 8 x 1.5 mm dimension were placed bilaterally distal to the canine to bring about intrusion and simultaneous retraction for space closure in the anterior region. The power chain was engaged on long hooks for 2 months.

After space closure, finishing and detailing was carried out on 21x25 NiTi. After that, 21x25 stainless steel arch wire was placed with extra individual positive crown torque and root torque for the upper right lateral and canine respectively. The total treatment duration was 28 months.

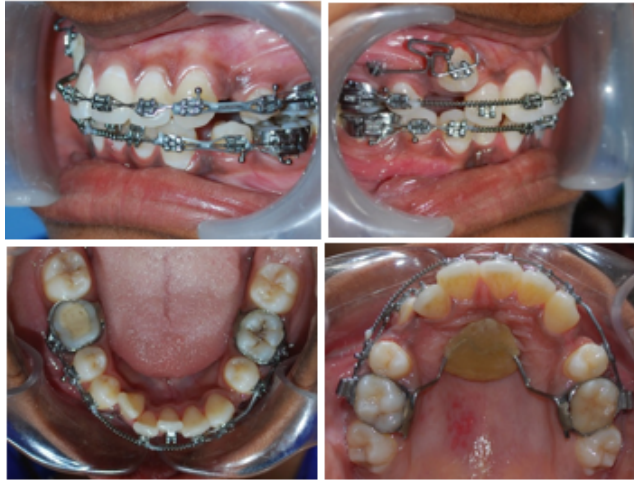
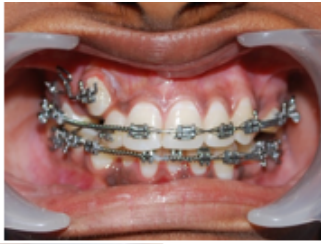
Fig. 3: Canine extrusion and simultaneous midline correction with open coil spring

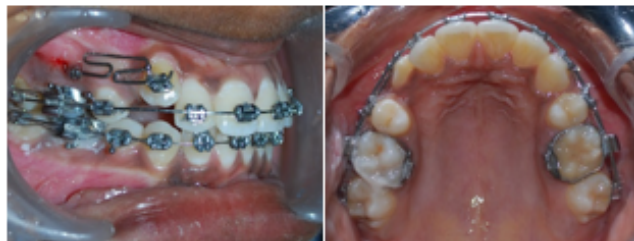
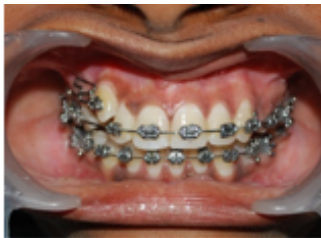
Fig. 4: Canine retraction progress

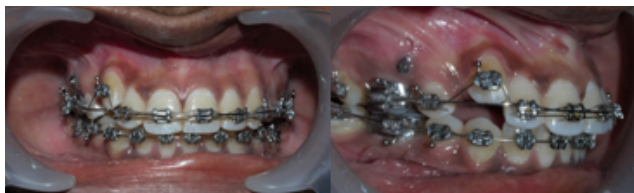

Fig. 5: Canine extrusion with piggy- back technique

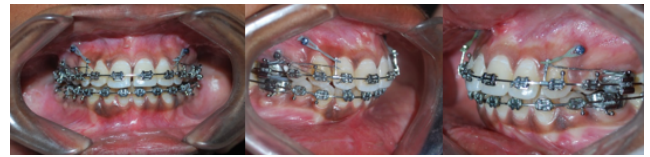


Fig. 6: Implant supported retraction and intrusion

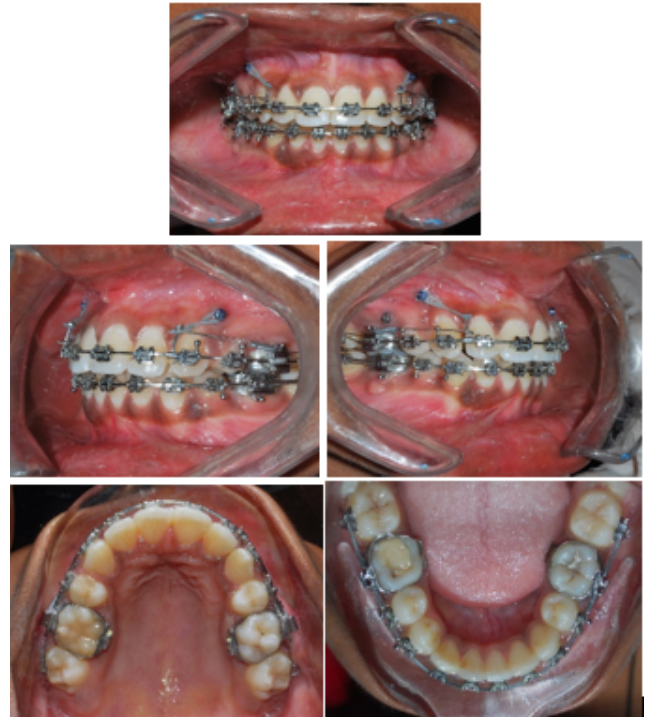

Fig. 7: Retraction in progress

6. Treatment Result

There was visible improvement in the facial profile of the patient. The procumbence of the lips decreased. There was significant reduction in lip strain as evident in the lateral cephalogram and extra-oral photographs. The nose lip relation, which was optimum due to the upwardly tipped nose and short upper lip in the beginning, was maintained and the teeth were not over-retracted.

There was significant improvement in the inclinations of the upper anterior. The extraction spaces in the lower arch were exhausted from decrowding, so the correction achieved was minimal. The efforts made to prevent the medialisation of the upper molars can be appreciated in the superimpositions. Complete space closure with optimum root parallelism was obtained.

7. Discussion

This was a peculiar case, where the patient was way past her growth spurt, and presented with an obvious problem of arch length and tooth size discrepancy, severe midline

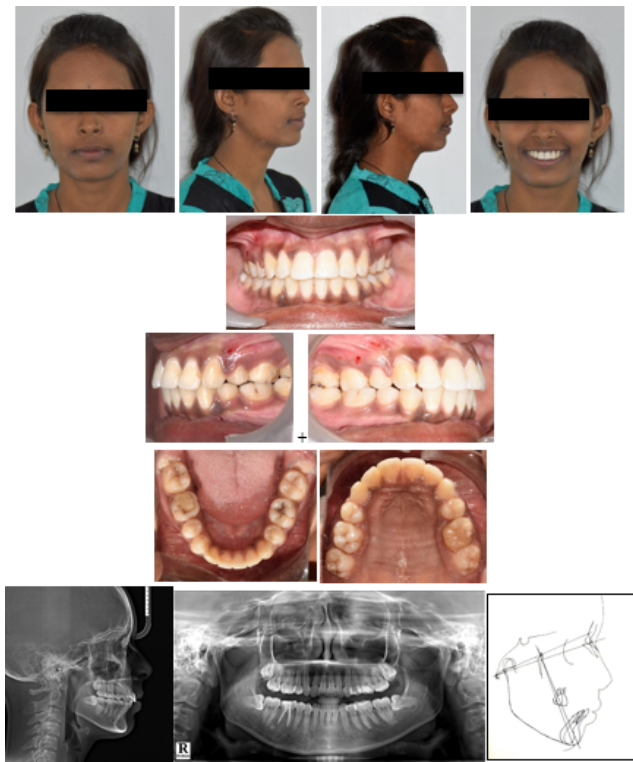


Fig. 8: Post treatment extra-oral photographs, lateral cephalogram, opg and super imposition

Table 1: Skeletal analysis

Parameter	Normal Value	Pre-treatment	Post Treatment
ANB	2°	3.5	3
Wits appraisal	0mm	BO is 1.5mm post to AO	BO 1mm post to AO
B – angle	27-32°	31.5	31
SNA	82°	80	83
N L- A	0-1mm	-3mm	-1
SNB	80°	76.5	80
N L – Pog	Small -8to-6 med -4 to 0 Large -2 to 2	-10mm	-4.5
Gonial Angle	143°+/-6°	131	134
S-N to Go-Gn	32°	31	30
FMA	25°	31	32
Y axis (N-S-Gn)	66°	70	66
U1 – SN	102°	121	107
U1 – NA	22°,4mm	41,7mm	23,5,5mm
IMPA	90°	93	94
L1 – NB	25°,4mm	26,5mm	28,5,5,5
Interincisal angle	131°	111	125

Table 2: Softtissue analysis

Parameter	Normal Value	Pre-treatment	Post treatment
S line	U-0 L-0	U +4mm L +5mm	U-6 L-1.5
NLA	102°	121	122
U lip strain	15+/-1mm	-2mm	0mm

shift and complicated with good soft tissue compensation and optimum facial parameters. In this case, the patient had a highly placed canine. One of the biggest challenges faced in such a situation is the mesial and upward migration of the posterior segment while aligning the canine. Absoluteness of TAD was combined with the controlled, biologically optimum and stable force generated by a segmental T-loop.^{5,6} The retraction of a canine by just a power chain or elastic thread from TAD, majorly brings about only crown movement. In this scenario, control of root angulation was crucial given its proximity to the lateral incisor root. A T-Loop made up of 19x25 TMA wire with necessary anti rotation bends, gives 3D control and ensures the translation of the tooth and not just tipping. Since the wire was made up of TMA, the activation duration, load deflection rate and Moment to Force ratio almost mimics natural tooth eruption, thus helping in best soft tissue response and bone remodelling rate.

Retraction of anterior teeth can be segmental or en masse. The decision depends on the presenting intra oral situation.^{7,8} In this case, the patient had severe midline shift, lingually placed lateral incisors and significant lip strain. This requires the creation of space by extraction for correcting midline as well as aligning lateral incisors. The alignment of the upper right lateral incisor was needed early on so as to ensure a good anchorage unit to extrude the canine. 0.018 AJ Wilcock Premium plus was used for segmental retraction, as the midline correction and retraction of canines could be achieved faster. This correction was done with Open NiTi coil spring as the force delivery is constant. The base arch wire was AJ Wilcock Premium plus, as the properties like Resilience, zero stress relaxation rate and Stiffness could be used as an advantage and prevent it from getting distorted by force from an open coil spring.

The canine was extruded and aligned using the Piggyback technique popularised by Sanders, as it prevents the adjacent teeth from collapsing into space and also canting of the maxillary plane.⁹

The decision to extract the canine from the lower arch was made, as its proximity to the lateral incisor and the length of the root put the vitality of the lateral in jeopardy and also the vitality of the canine itself given its proximity to the labial cortical plate was critical.

7.1. Decision was made to work within the anatomical boundaries

From an aesthetic and functional perspective, it's always easier to cuspidize the lower first premolar rather than the upper first premolar. The lingual cusp on the lower premolar is not prominent, so it wouldn't interfere with lateral excursions and is well away from the esthetic zone. It is not the same when it comes to replacing the upper canine by a premolar. Besides, from the mini-aesthetics aspect, the patient would require gingival surgery to match the zenith of the premolar to the contralateral canine.

Sometimes patients have a change of heart, and given the COVID scenario looming large at the time, the patient backed out of the esthetic surgery which was planned to correct her nose and lip relationship. So, Torque controlled en-masse intrusion and retraction was needed to compensate for the anatomically short upper lip. TADs were placed distal to the canine bilaterally, long hooks were used to make sure the force vector passed close to the centre of resistance, and a power chain was run.

There are many techniques to bring intrusion and retraction, but given the latest systematic reviews, all of them worsen the profile of the patient. Three main reasons to place TADs distal to canine were: 1. The target teeth which were the incisors. 2. The power chain usually lacerates the gingiva and frenal attachment when placed between premolar and molar 3. Anterior retraction and space closure.

Right from the days of Ronald Roth, overcorrection has become quite a mainstay in modern orthodontics. The bracket of the upper right lateral was inverted to deliver the negative root torque needed and the lower incisor bracket had the required negative root torque built in the base, but still additional root torque was built in the wire to prevent relapse.

8. Conclusion

This case had 2 buccally placed canines on the same side, one in each arch.. Anatomical boundaries, age of patient and esthetic considerations play a major role in deciding the extraction pattern. Once the decision was made, a biomechanically sound approach was selected to correct the canines as well as correct the midlines right from the early stages of treatment. Thus, the use of elastics for midline correction near the end of treatment was eliminated. Placing bets on a statically determinate force system with the upper canine and rigorous mechanics helped in improving the predictability of the case.

9. Conflict of Interest

None.

10. Source of Funding

None.


References

1. John ZAS, Shrivastav S, Gurudatta NS, Murarka S. An Innovative Approach to Manage Tooth Size - Arch Length Discrepancy. *J Evolution Med Dent Sci*. 2019;8(50):3819–21. Available from: <http://dx.doi.org/10.14260/jemds/2019/827>.
2. Redahan S, Lagerström L. Orthodontic treatment outcome: the relationship between anterior dental relations and anterior inter-arch tooth size discrepancy. *J Orthod*. 2003;30(3):237–44. doi:10.1093/ortho/30.3.237.
3. Kang JM, Oh MB. Extraction Treatment Using Unilateral Molar Distalization for Lip Protrusion Patient with Asymmetric Molar Relationship. *Clin J Korean Assoc Orthod*. 2021;11:140–9. doi:10.33777/cjka.2021.11.2.140.
4. Moshkelgosha V, Fathinejad S, Pakizeh Z, Shamsa M, Golkari A. Photographic Facial Soft Tissue Analysis by Means of Linear and Angular Measurements in an Adolescent Persian Population. *Open Dent J*. 2015;9(1):346–56. doi:10.2174/1874210601509010346.
5. Jiang F, Roberts WE, Liu Y, Shafiee A, Chen J. Mechanical environment for lower canine T-loop retraction compared to en-masse space closure with a power-arm attached to either the canine bracket or the archwire. *Angle Orthod*. 2020;90(6):801–10.
6. Tian H, Xie C, Lin M, Yang H, Ren A. Effectiveness of orthodontic temporary anchorage devices in canine retraction and anchorage preservation during the two-step technique: a systematic review and meta-analysis. *BMC Oral Health*. 2020;20(1):278–10.
7. Xia Z, Chen J, Jiangc F, Li S, Vecicilli RF, Liu SY, et al. Load system of segmental T-loops for canine retraction. *Am J Orthod Dentofac Orthop*. 2013;144:548–56.
8. Shyagali TR, Rajpara Y, Trivedi K. Simple “TRS” Auxiliary tube for retraction of anterior segment using segmental T loop mechanics. *Int J Orthod Milwaukee*. 2014;25(1):31–3.
9. Lombardo L. Ectopic canine control with conventional brackets. *Int Orthod*. 2012;10:377–403. doi:10.1016/j.ortho.2012.09.0128.

Author biography


Shubhangi Ameet Mani, Professor  <https://orcid.org/0000-0002-1440-1409>

Ravindra Manerikar, Professor  <https://orcid.org/0000-0002-8086-4866>

Nilesh Mote, Professor  <https://orcid.org/0000-0001-7309-3007>

N G Toshniwal, Professor and HOD

Kunal Pallan, Post Graduate Student  <https://orcid.org/0000-0002-0717-9942>

Deeksha Ganesh Devadiga, Post Graduate  <https://orcid.org/0000-0001-8457-4340>

Cite this article: Mani SA, Manerikar R, Mote N, Toshniwal NG, Pallan K, Devadiga DG. Correction of ectopically placed canine by combining skeletal anchorage and statically determinate force system. *IP Indian J Orthod Dentofacial Res* 2023;9(2):122-126.